

# HYDATID CYST OF SACRUM AFFECTING THE SAKROILIAC JOINT: A CASE REPORT

## SAKROİLİAK EKLEMİ TUTAN SAKRUM KİST HİDATİĞİ: OLGU SUNUMU

Yunus GÜZEL\*, Burcak K. KAÇIRA\*\*, Recep GÖNCÜ\*\*\*,  
Ali GÜLEÇ\*\*\*\*, Harun KÜTAHYA\*\*\*, Musfata YEL\*\*\*\*\*

### SUMMARY

**Objective:** To describe a rare instance of hydatid cyst that caused severe and progressive low-back pain and misdiagnosed as sacroiliitis. **Introduction:** Hydatid disease or hydatidosis is a serious human cestode infection in the world and has a characteristic geographic distribution. The liver and lungs are most frequently involved organs. Bone involvement is less than 4% in cases. Vertebral hydatid disease is uncommon. Signs of sacroiliac joint and low-back pain cause difficulties in differential diagnosis and this rare condition may be misdiagnosed.

**Case Report:** A case of a 21-year-old woman with hip pain had been caused by a secondary hydatid cyst of the sacral and pelvic areas. Patient was diagnosed sacroiliitis and sciatica in another center. As treatment for these failed, the patient referred to our clinic. Physical examination and radiological tests revealed iliac bone lesions, which is starting from left sacral area and extending to sacroiliac joint.

**Results:** Following medical treatment, curettage and grafting were performed. Macroscopic image and histopathological evaluation of the material which removed from lesion field was consistent with hydatid disease. No recurrence was detected and patient was symptom free at 11 months follow up. **Conclusions:** Bone hydatid disease is misdiagnosed in early periods. It progresses and the bone is destructed. In patients with a history of hydatid disease and with musculoskeletal complaints, a possible disease of hydatid cyst should be kept in mind. And which is safer in management of remaining cavity, bone grafting or acrylic cement? We think that bone grafting is safe in management of remaining cavity.

**Key words:** Cyst hydatid, surgical treatment, spinal hydatid infection

**Level of evidence:** Case report, Level IV

### ÖZET

**Amaç:** Ciddi ve ilerleyici bel ağrısına neden olan ve yanlış tanı almış nadir görülen bir kist hidatik vakasını tanımlamak.

**Giriş:** Hidatik hastalık ya da hidatidozis dünyada yaygın bir insan sestod enfeksiyonudur ve karakteristik coğrafik bir dağılıma sahiptir. Karaciğer ve akciğerler en sık tutulur. Vakalarda kemik tutulumu %4'den daha azdır. Vertebral hidatik hastalık nadirdir. Sakroiliak eklem bulguları ve bel ağrısı ayırıcı tanıyı zorlaştırır ve bu nadir durum yanlış tanıya neden olabilir. **Olgu Sunumu:** Sakrum ve pelvisin sekonder hidatit kistlerinin kalça ağrısına neden olduğu 21 yaşında bayan hasta sunuldu. Başka bir merkezde sakroileit ve siyatik ağrısı tanısı almış ve tedavisi başarısız olan hasta kliniğimize sevk edildi. Fizik muayenesi ve radyolojik testleri sol sakrumdan başlayıp sakroiliak kemiğe uzanan iliak kemik lezyonlarını açığa çıkardı. **Sonuç:** Medikal tedaviyi takiben, küretaj ve greftleme uygulandı. Lezyondan çıkarılan materyalin makroskopik görünümü ve histopatolojik değerlendirilmesi hidatit hastalık ile uyumluydu. 11 aylık takibinde nüks gözlenmedi ve hasta semptomsuzdu.

**Tartışma:** Erken dönemlerinde kemik hidatik hastalığı yanlış tanı alabilir. Hastalık ilerler ve kemiği destrükte eder. Hidatitk hastalık öyküsü olan ve kas-iskelet şikâyetleri olan hastalarda hidatik kist hastalığı ihtimali akılda tutulmalıdır. Debride edilen vertebrada kalan kavitenin kemik greftiyle doldurulmasının daha güvenilir olduğuna inanıyoruz.

**Anahtar Kelimeler:** Kist hidatit, cerrahi tedavi, omurga kist hidatiti

**Kanıt Düzeyi:** Olgu sunumu, Düzey IV

### INTRODUCTION

Echinococcosis is a zoonotic infection caused by Echinococcus species and is one of the most important helminthic diseases worldwide. Echinococcus granulosus is a small tapeworm which requires humans as an intermediate hosts. Human infection is caused by ingestion of the tapeworm eggs. Liver

and lungs involvement is the most common (7). Bone hydatid disease is a rare pathology and bone involvement constitutes only 1-2 % of all hydatid cyst cases: iliac bones and spine is the most common site (3). This case report describes a rare instance of a hydatid cyst that caused severe and progressive low-back pain (LBP) with S1-2 neural foramen involvement without neurologic dysfunction.

\* Ortopedi ve Travmatoloji Uzmanı, Yozgat Akmağdeni Devlet Hastanesi, Yozgat.

\*\* Yard. Doç. Dr., Ortopedi ve Travmatoloji Uzmanı, Ortopedi ve Travmatoloji Anabilim Dalı, Necmettin Erbakan Üniversitesi Tıp Fakültesi, Konya

\*\*\* Ortopedi ve Travmatoloji Uzmanı, Beyhekim Devlet Hastanesi, Konya.

\*\*\*\* Ortopedi ve Travmatoloji Uzmanı, Meram Eğitim ve Araştırma Hastanesi, Konya.

\*\*\*\*\* Prof. Dr., Ortopedi ve Travmatoloji Uzmanı, Özel Konya Medline Hastanesi, Konya.

## CASE REPORT

A 21-year-old female was presented with hip pain and LBP. She described the pain was radiating toward the left thigh, without change during rest. In her medical history; six years ago she had been operated on for lung hydatid cyst for 3 times, and she had been also treated by antiparasitic therapy after surgery. She was followed and treated as sacroileitis and sciatica because of left hip pain in another center for six months.

At presentation, her vital signs were normal. She had low-back pain and normal range of motion of lower extremity. The straight leg raising test was positive for left at 70°–80°. Results of the neurological examination of the lower limbs were normal. Laboratory findings were consistent with increased levels of lymphocytes, eosinophils, and C-reactive protein. Indirekt hemagglutination test was positive for cyst hydatid.

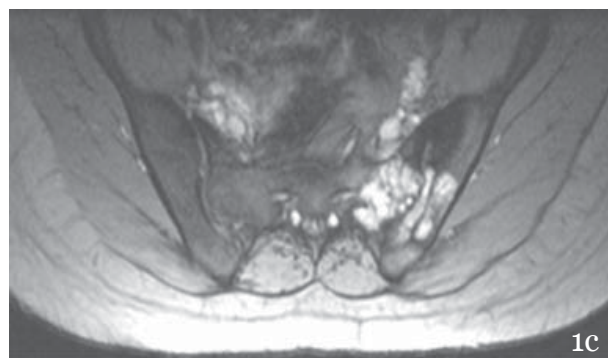
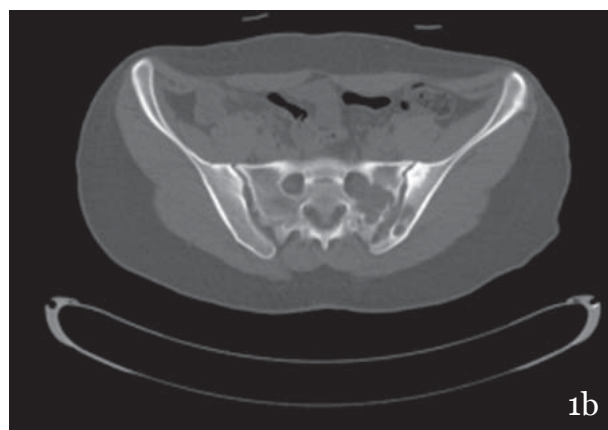
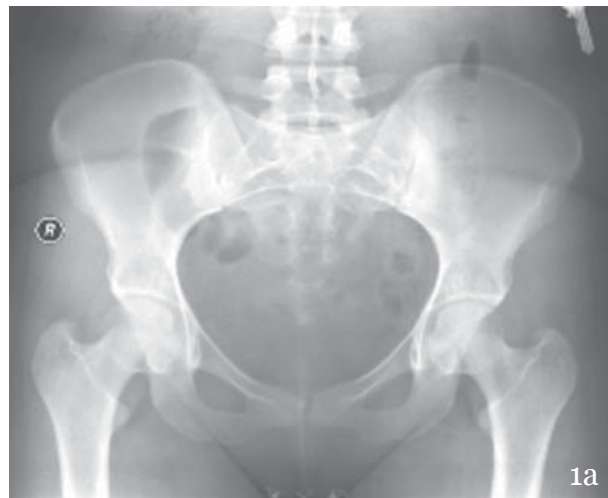Chest x-ray and thorax computerized tomography (CT) revealed increased density and consolidation on both lower lobes of lungs. Abdomen CT revealed cysts which are compatible with type 2 and type 3 hydatid cysts on hepatic parenchyma. Plain pelvic radiograph revealed expansive destructive lesion on the left iliac bone and sacrum extending to the sacroiliac joint (SIJ) (Figure-1A).

Pelvic CT showed multilobular cysts located in the left hemi-sacrum, expanding the S1–2 neural foramen and extended to the iliac bone and SIJ (Figure-1B).

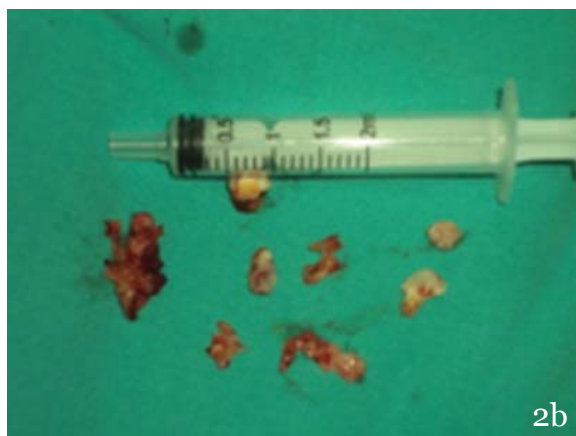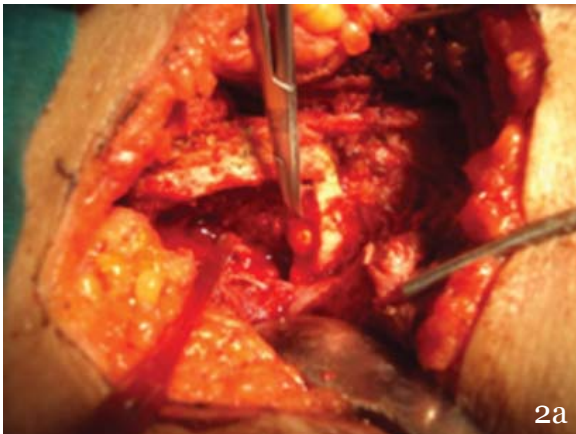
Magnetic resonance T1-weighted image revealed a hypointense cystic lesion in S1 and S2 sacral ala, extending to the left SIJ and invading through the sacral canal with displacement of S1 and S2 nerve roots (Figure-1C).

Mebendazole (100 mg twice daily) treatment was administered for two weeks before surgery. In surgery, bony window removed from posterior ileum over cystic lesion. Multiple pearly white capsulated cysts were enucleated. The affected sacroiliac joint and S1-2 sacral ala were curetted and the area irrigated with hypertonic saline and polyvinyl iodine 10 % (Figure-2A, 2B). Remaining cavity was grafted with 60 cc allograft.

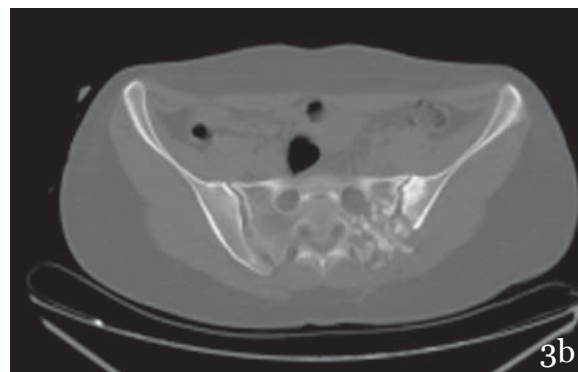
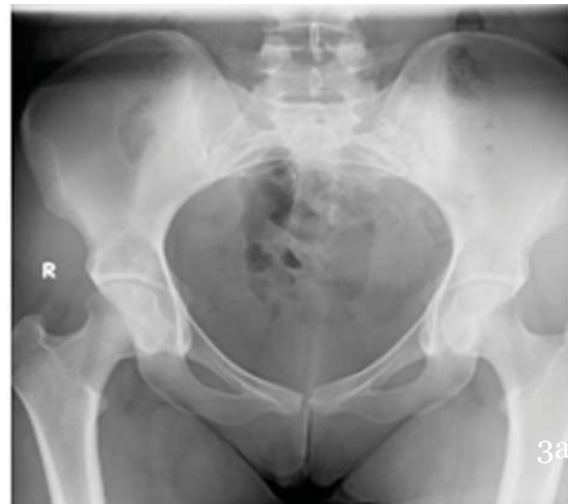Diagnosis of hydatid disease was confirmed by histopathologic examination. The patient was mobilized with crutches by allowing toe-touch weight-bearing in postoperative period. Mebendazole treatment was continued for 4 months. At 11 months after surgery, the clinical and radiologic examination yielded no evidence of recurrence (Figure-3A, 3B). The patient had only a little discomfort on the left SIJ in full flexion.



**Figure-1.a.** Plain pelvic radiograph shows expansive destructive lesion (arrowhead) on the left lateral sacrum extending through right SIJ and iliac bone. **b.** Computerized tomography (CT) scans shows multiloculated cysts located in the left hemisacrum expanding the S1–2 neural foramen and extended to the iliac bone and SIJ. **c.** Magnetic resonance T1-weighted image revealed a hypointense cystic lesion in S1 and S2 sacral ala, extending to the right SIJ and invading through the sacral canal with displacement of the S1 and S2 nerve roots.



**Figure-2.a.** Cavity and hydatid cyst **b.** Enucleated hydatid cysts



**Figure-3.a.** Plain pelvic radiograph at 11th months after surgery. **b.** Computerized tomography (CT) scans shows bone grafts are not yet completely reorganized in the left sacroiliac joint and sacrum at 11th months after surgery. There are erosive changes and sclerosis in the left sacroiliac joint.

## DISCUSSION

Hydatid disease of spine occurs in 1 % of all cases of human echinococcosis and is most commonly located in dorsal spine (50 %) (1). Sacral and cervical spinal segments are the least commonly involved areas (2).

Because of common symptoms such as LBP and radicular pain, misdiagnosing is common. In our case, involvement of the sacroiliac joint had been caused to LBP, thus the patient had been followed by rheumatology clinic for sacroileitis. The positive history for previous echinococcosis is helpful for diagnosis as in our case.

Operative treatment of spinal echinococcosis involves the selection of an approach that allows adequate removal of the cyst and cyst contents without spillage, management of the remaining cavity

and avoidance of reactions hypersensitivity to the hydatid antigen. Removal of the main cyst mass may not be effective because a small daughter cyst can be left behind. Local application of disinfectants is useful to devitalize cystic contents to prevent recurrence (4). Hypertonic saline is the most frequently reported scolocidal agent used in spinal disease. We also used hypertonic saline and additionally we used polyvinyl iodine. The cavity was filled with polyvinyl iodine for ten minutes. We protected surrounding tissues with hypertonic saline-impregnated sponges to prevent transmission.

Sapkas et al. suggested that osteosynthesis can be improved by the use of acrylic cement, considering that osseous grafts can be invaded by hydatidosis extension or recurrence (6). Unlike these, Pintilie et al. recommended bone grafting for management of the remaining cavity (5). In this case,

a large cavity occurred in the sacroiliac joint, sacral area and iliac wing, so we used 60 cc allograft. There was no recurrence on computerized tomography on postoperative 11th months.

In conclusion, many cases of rare localizations of echinococcosis remain undiagnosed or

misdiagnosed. Hydatid cyst should be kept in mind in differential diagnosis of LBP, especially when treating patients who have positive history or live in endemic areas.

## REFERENCES

1- Charles RW, Govender S, Naidoo KS. Echinococcal infection of the spine with neural involvement. *Spine* 1988; 13: 47-49.

2- İşlekel S, Ersahin Y, Zileli M, Oktar N, Oner K, Ovül I, Ozdamar N, Tunçbay E. Spinal hydatid disease. *Spinal Cord* 1998; 36: 166-170.

3- Özdemir H M, Ögün T C, Tasbas B. A Lasting Solution Is Hard to Achieve in Primary Hydatid Disease of the Spine: Long-Term Results and an Overview. *Spine* 2004; 29(8): 932-937.

4- Pamir N, Ozdamar K, Elmacı I. Spinal hydatid disease. *Spinal Cord* 2002; 40: 153-160.

5- Pintilie D C, Panoza G, Hatmanu D, Fahrer M. Echinococcosis of humerus. Treatment by resection and bone grafting: A case report. *J Bone Joint Surg* 1966; 48-A (5): 957-961.

6- Sapkas GS, Stathakopoulos DP, Babis GC, Tsarouchas JK. Hydatid disease of bones and joint. *Acta Orthop Scand* 1998; 69 (1): 89-94.

7- Scarlata F, Giordano S, Saporito L, Marasa L, Li Pani G, Odierna A, Scaglione V, Di Carlo P, Romano A. Cystic hydatidosis: a rare case of spine localization. *Infec Med* 2011; 19(1): 39-41.

**Adres:** Op. Dr. Yunus Güzel, Yozgat Akmağdeni Devlet Hastanesi, Yozgat.

**Tel.:** 0505 699 63 68

**e-Mail:** dryg@windowslive.com

**Geliş Tarihi:** 1 Şubat 2013

**Kabul Tarihi:** 16 Mart 2013