

**Günümüzde**  
**Fundus Floresein Anjiyografinin**  
**Yeri**

Dr. Hürkan Kerimođlu, FICO  
N. E. U. Meram Tıp Fakóltesi

Sunumda adı geen ruhsat/izin sahipleri veya  
ürünlerle herhangi bir finansal ilintim yoktur

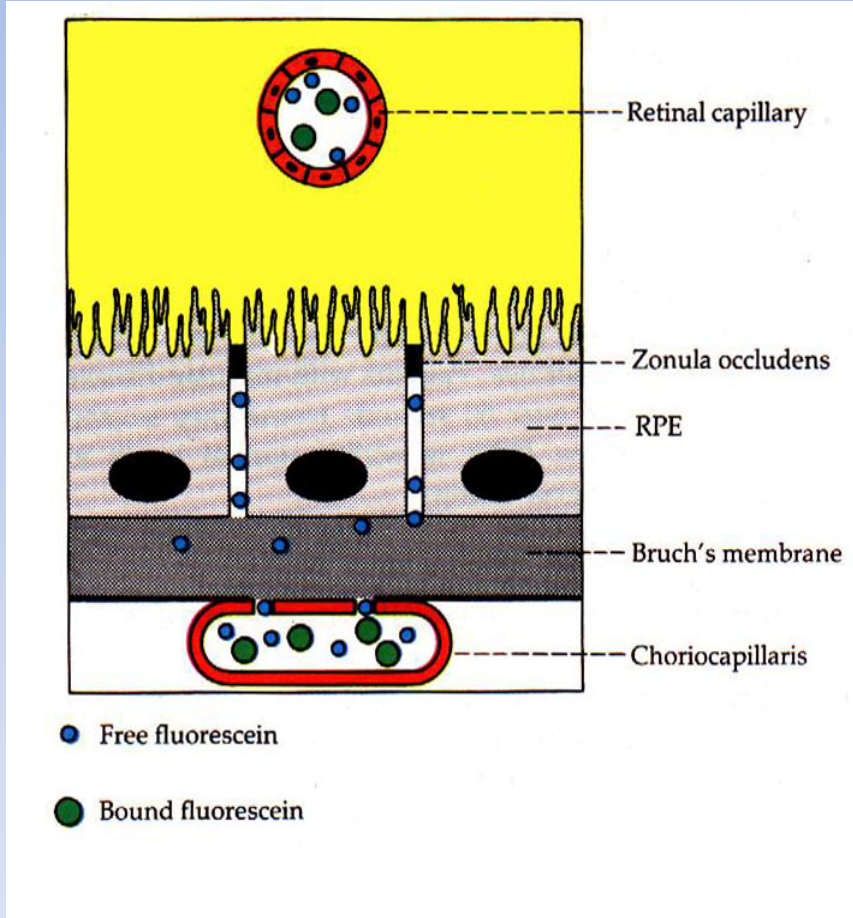
1871 - Adolf von Baeyer – Floresein sodyum

1920 - İlk ticari fundus kamera

1959 - MacLean ve Maumenee – Biyomikroskop/kobalt filtre

1960 - Harold Novotny ve David Alvis – Fotoğraf filmine kayıt

## FFA – Temel Prensipler



Floresein sodyum  
736d molekül ağırlığı

%85 albumine bağlı, %15 serbest

**İç kan-retina bariyeri**  
Geçirgen değil

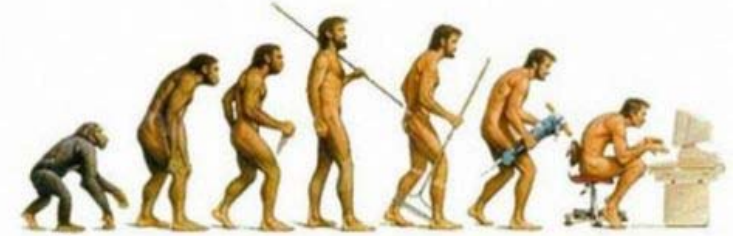

**Dış kan-retina bariyeri**  
Geçirgen değil

**Koryokapillaris**  
Geçirgen

## Geçmişten Günümüze FFA

■ Endikasyonlar

■ Teknik - Cihazlar



## Endikasyonlar



## Retinal Vasküler Hastalıklar

Diabetik retinopati

Hipertansif retinopati

Retinal arteriyel tıkanıklık

Retinal venöz tıkanıklık

Retinal makroanevrizma

Coat's hastalığı

Eales hastalığı

Retinal kapiller hemanjiyom

Retinal kavernöz hemanjiyom

## Maküler Hastalıklar

Yaşa bađlı maküla dejenerasyonu

Polipoidal koroidal vaskülopati

Retinal anjiyomatöz proliferasyon

Kistoid maküler ödem

Hereditör maküler hastalıklar

Dejeneratif miyopi

Anjiyoid yarıklar

Santral seröz korioretinopati

İdiopatik jukstafoveal telenjiektazi

Klorokin makülopatisi

# Retinokoroidal İnflamatuvar Hastalıklar

Toksoplazma retinokoroiditi

Multifokal koroidit

APMPPE

Punktat iç koroidopati

Oküler histoplazmozis sendromu

Birdshot korioretinopatisi

Okluzif retinal vaskülit

İnflamatuvar retinal ödem

Serpijinöz koroidit

## Optik Sinir Başı Hastalıkları

Optik diskin konjenital anomalileri

Optik pit

Jukstapapiller kapiller hemanjiyom

Anterior iskamik optik nöropati

Papillit

Papilödem

Peripapiller koroidal neovaskülarizasyon

## Koroidal Tümörler

Koroidal melanom

Koroidal metastaz

Koroidal hemanjiyom

## Endikasyonlar

Maküler patolojiler – OKT, İSYA, FAF

Submaküler koroidal patolojiler – EDI OKT, İSYA

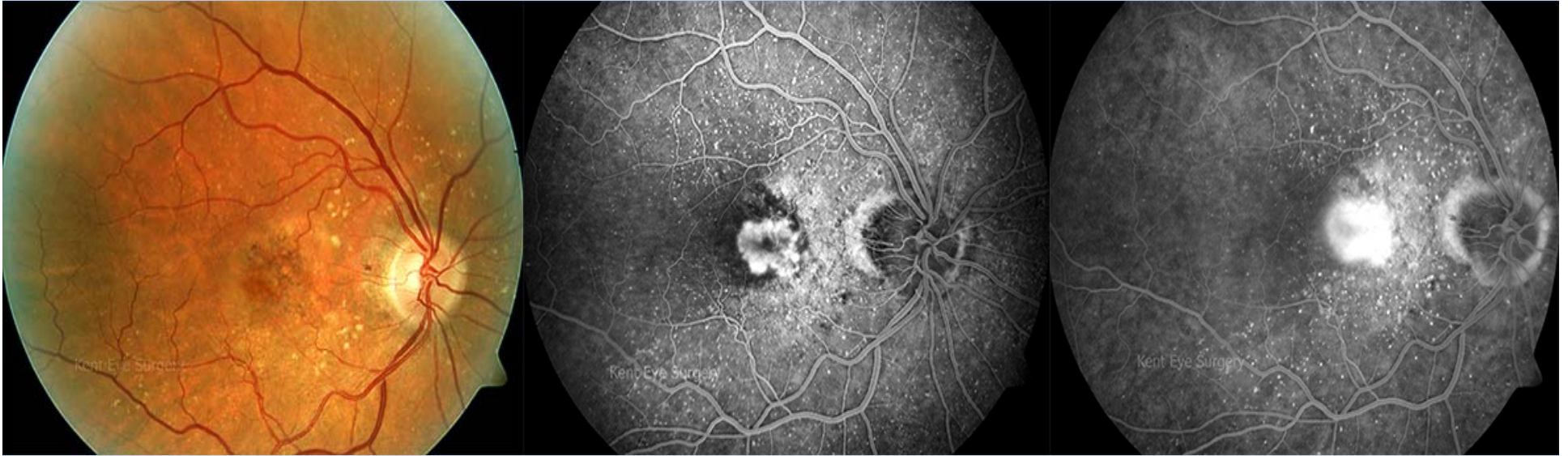
Koroidal vasküler sistem – İSYA

Koroidal inflamatuvar hastalıklar – İSYA

Retina pigment epiteli patolojileri – FAF

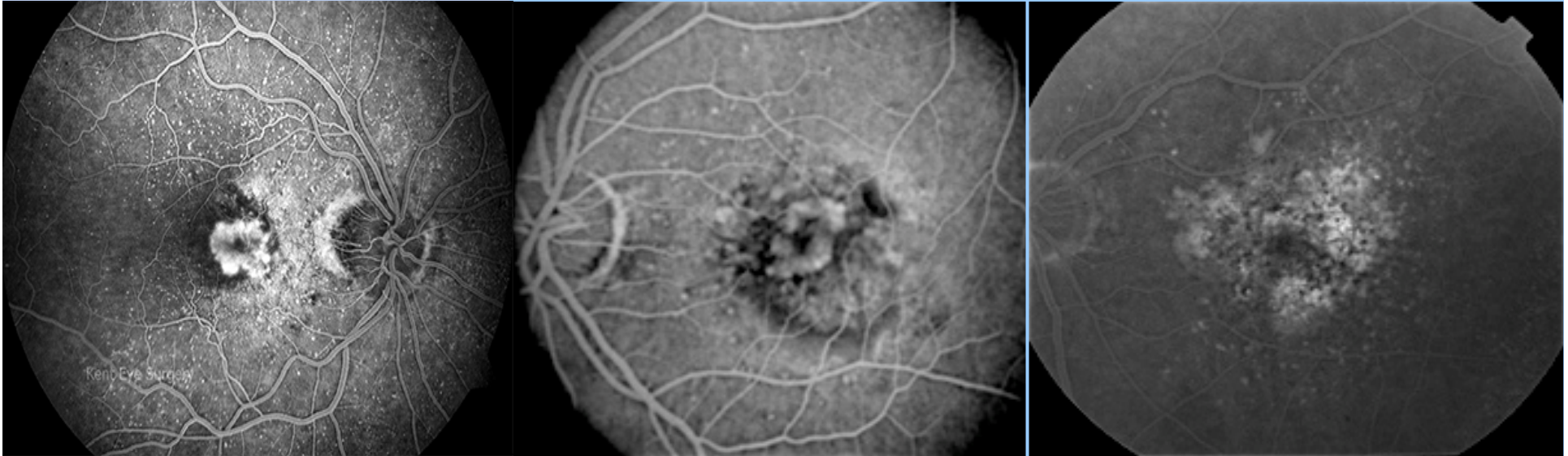
# Maküla Hastalıkları

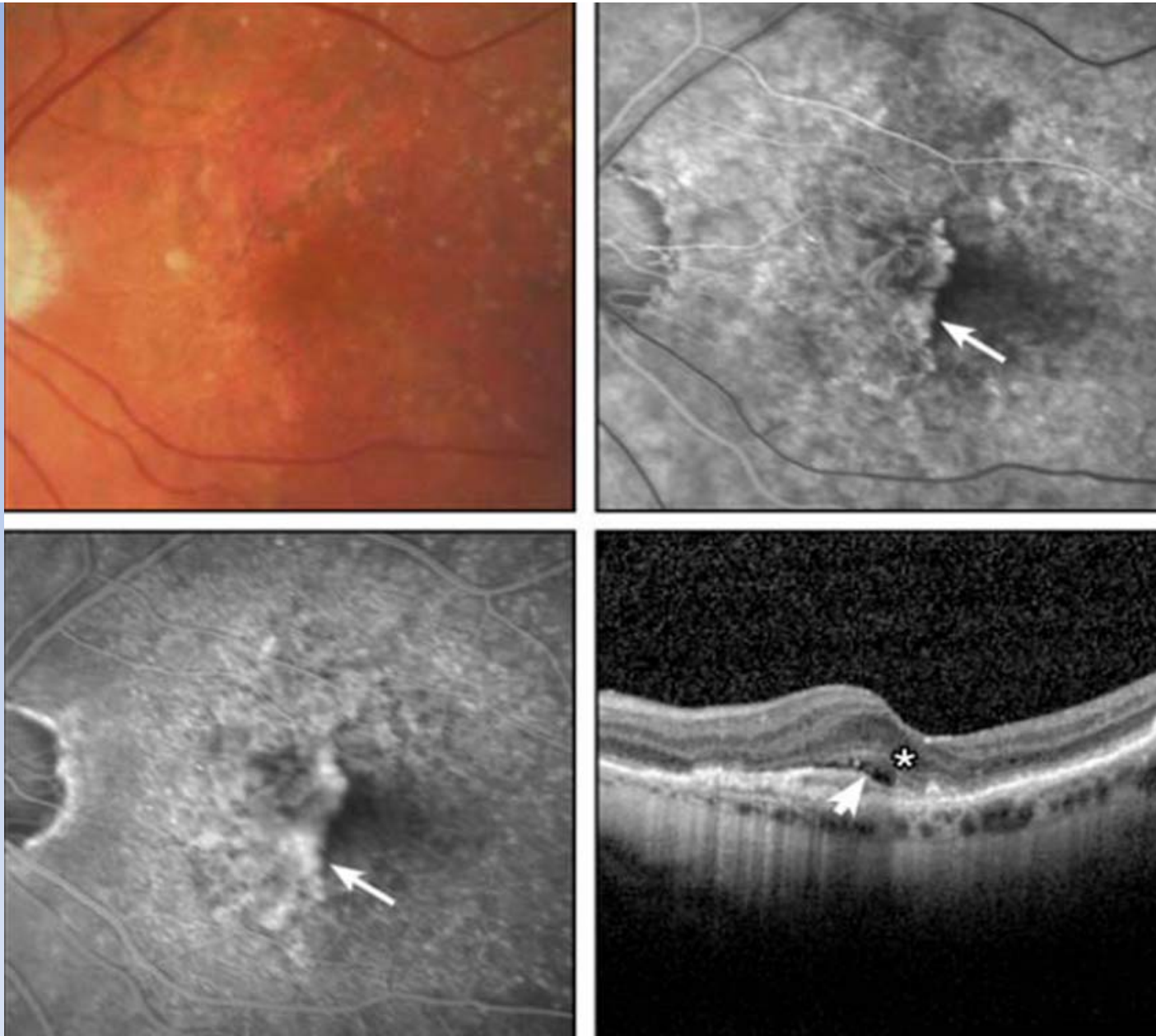
## YBMD – Tanı



# Maküla Hastalıkları

## YBMD – Lezyon tipi

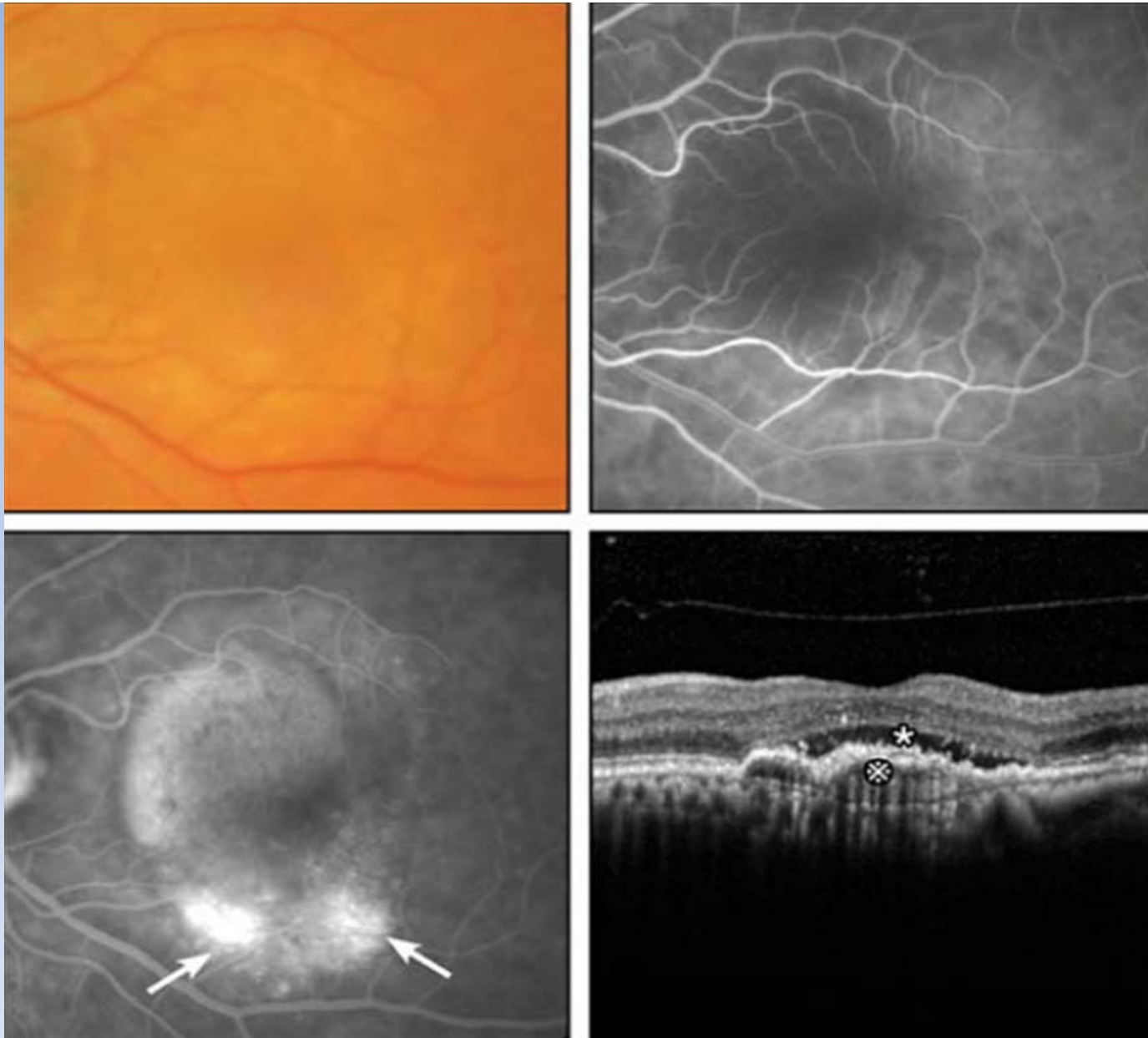



Mathew R, Pefkianaki M, Kopsachilis N, Brar M, Richardson M, Sivaprasad S.

[Correlation of Fundus Fluorescein Angiography and Spectral-Domain Optical Coherence Tomography in Identification of Membrane Subtypes in Neovascular Age-Related Macular Degeneration.](#)

Ophthalmologica. 2013 Nov 6.



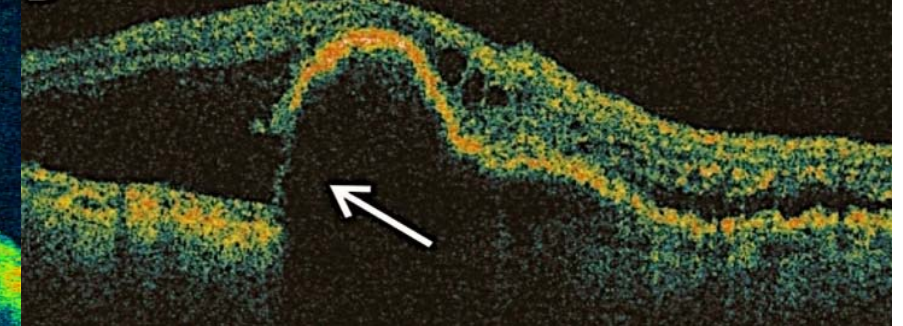
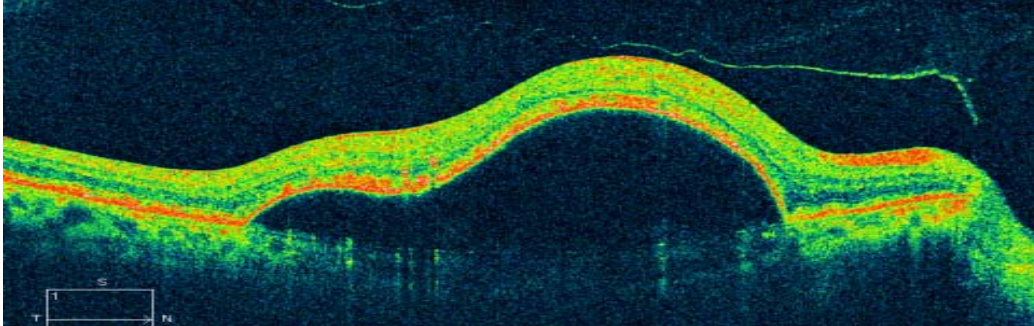
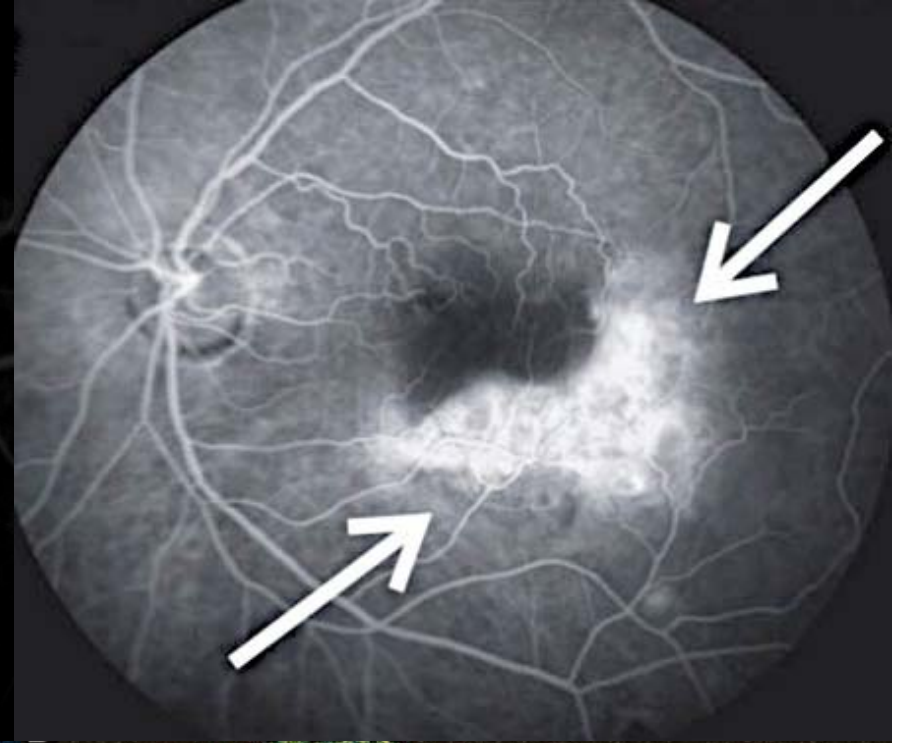
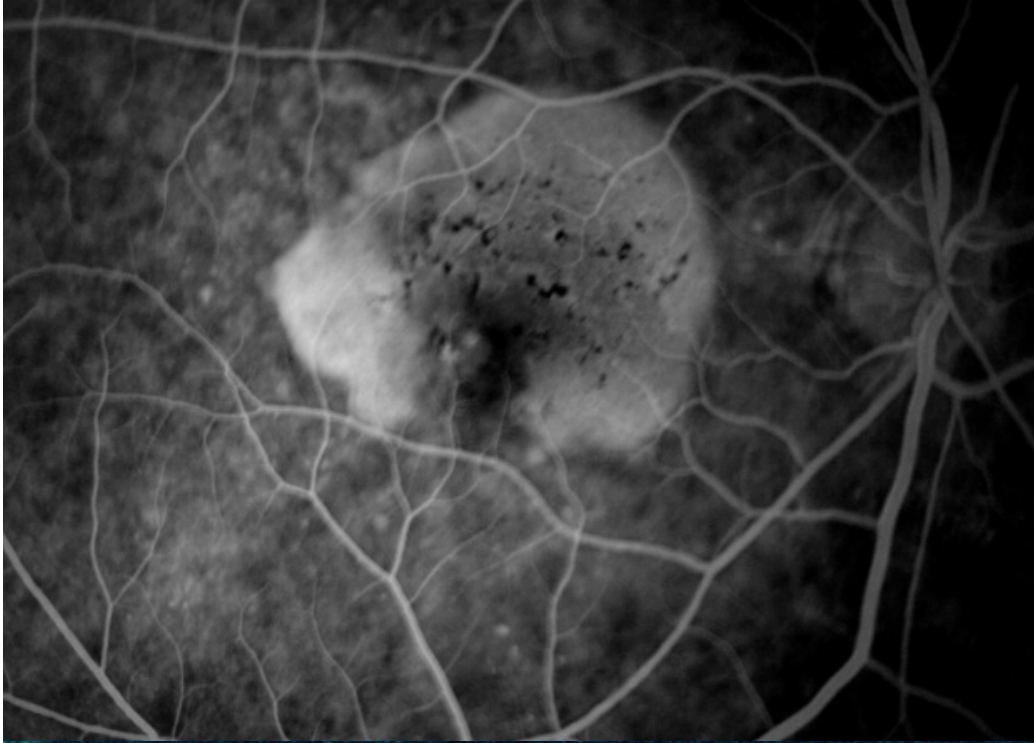Mathew R, Pefkianaki M, Kopsachilis N, Brar M, Richardson M, Sivaprasad S.

[Correlation of Fundus Fluorescein Angiography and Spectral-Domain Optical Coherence Tomography in Identification of Membrane Subtypes in Neovascular Age-Related Macular Degeneration.](#)

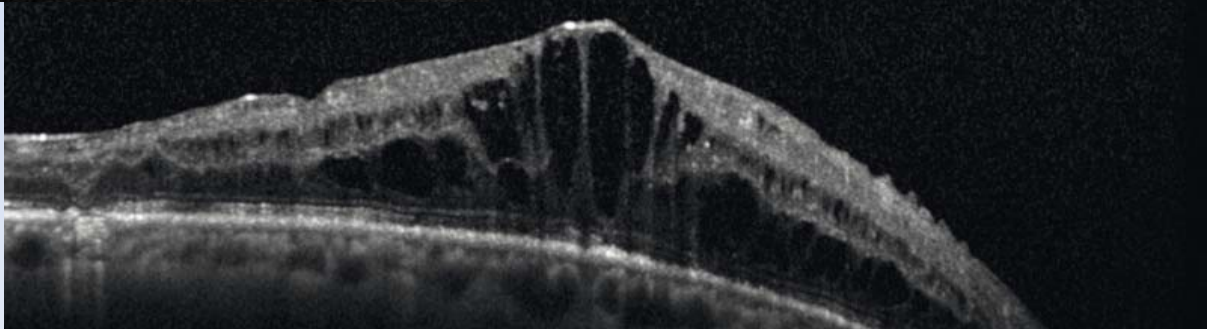

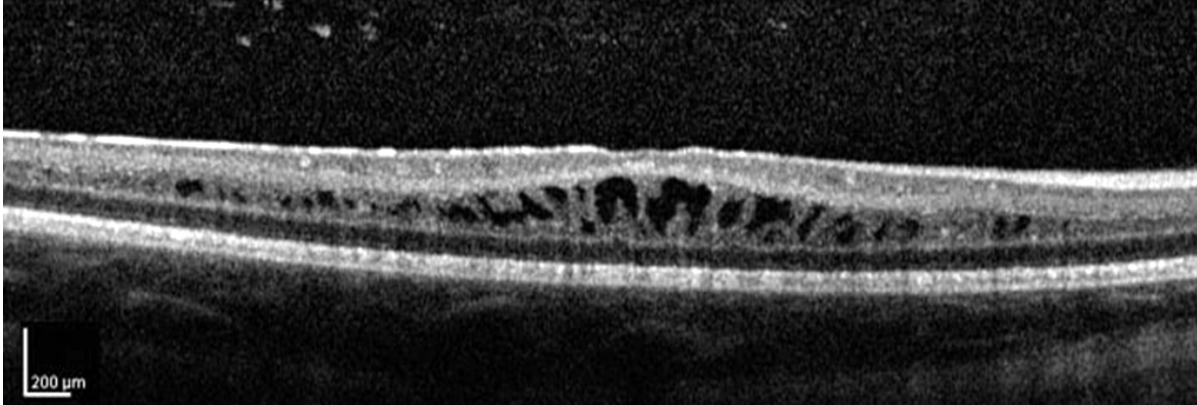
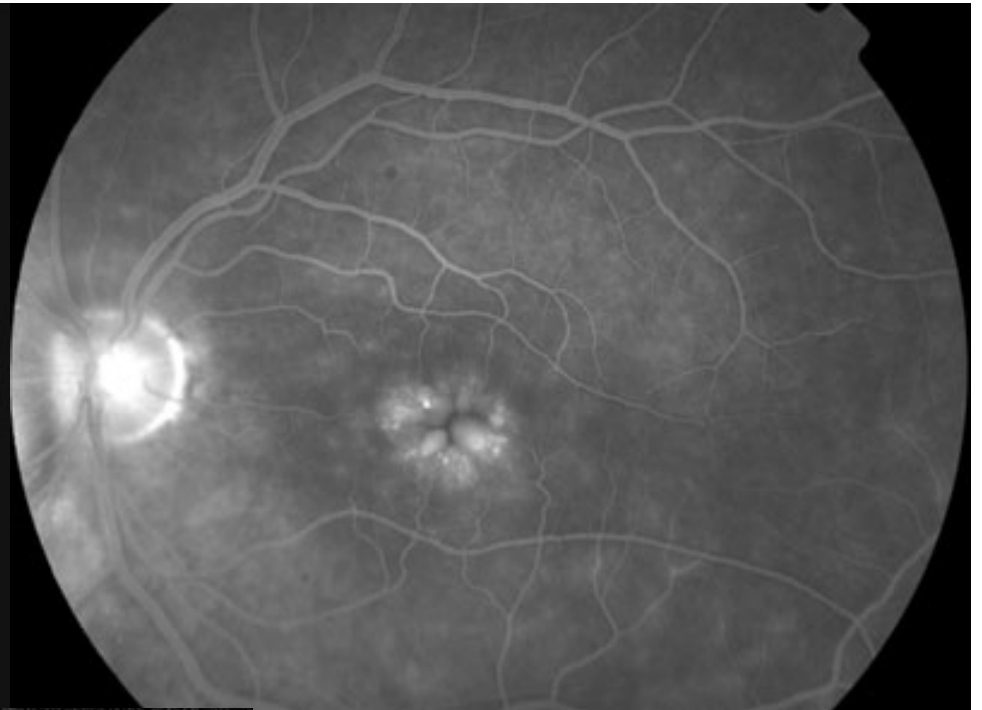
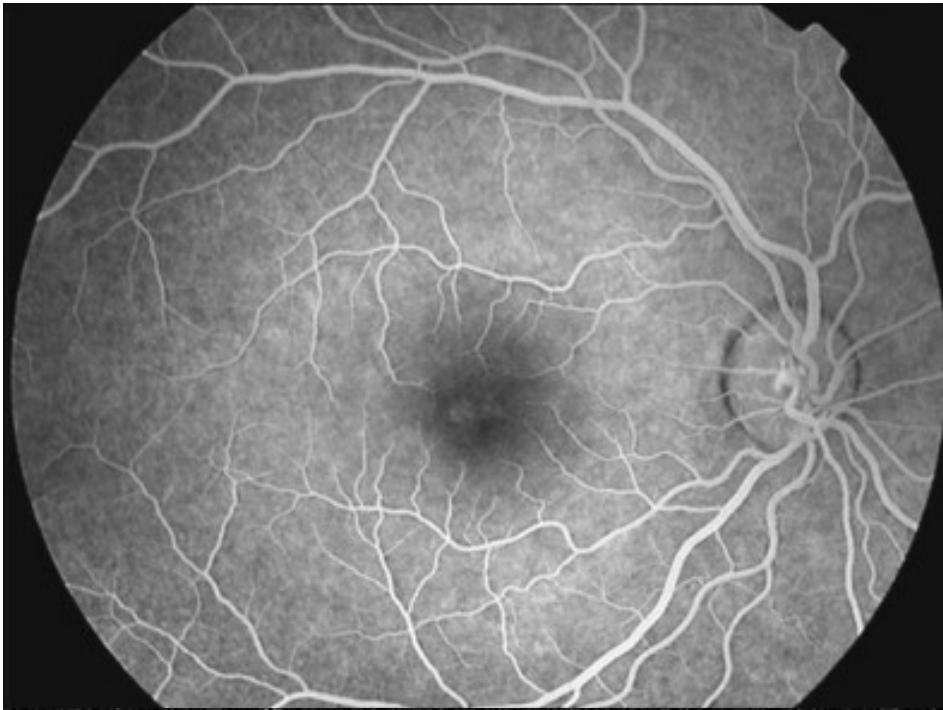
Ophthalmologica. 2013 Nov 6.

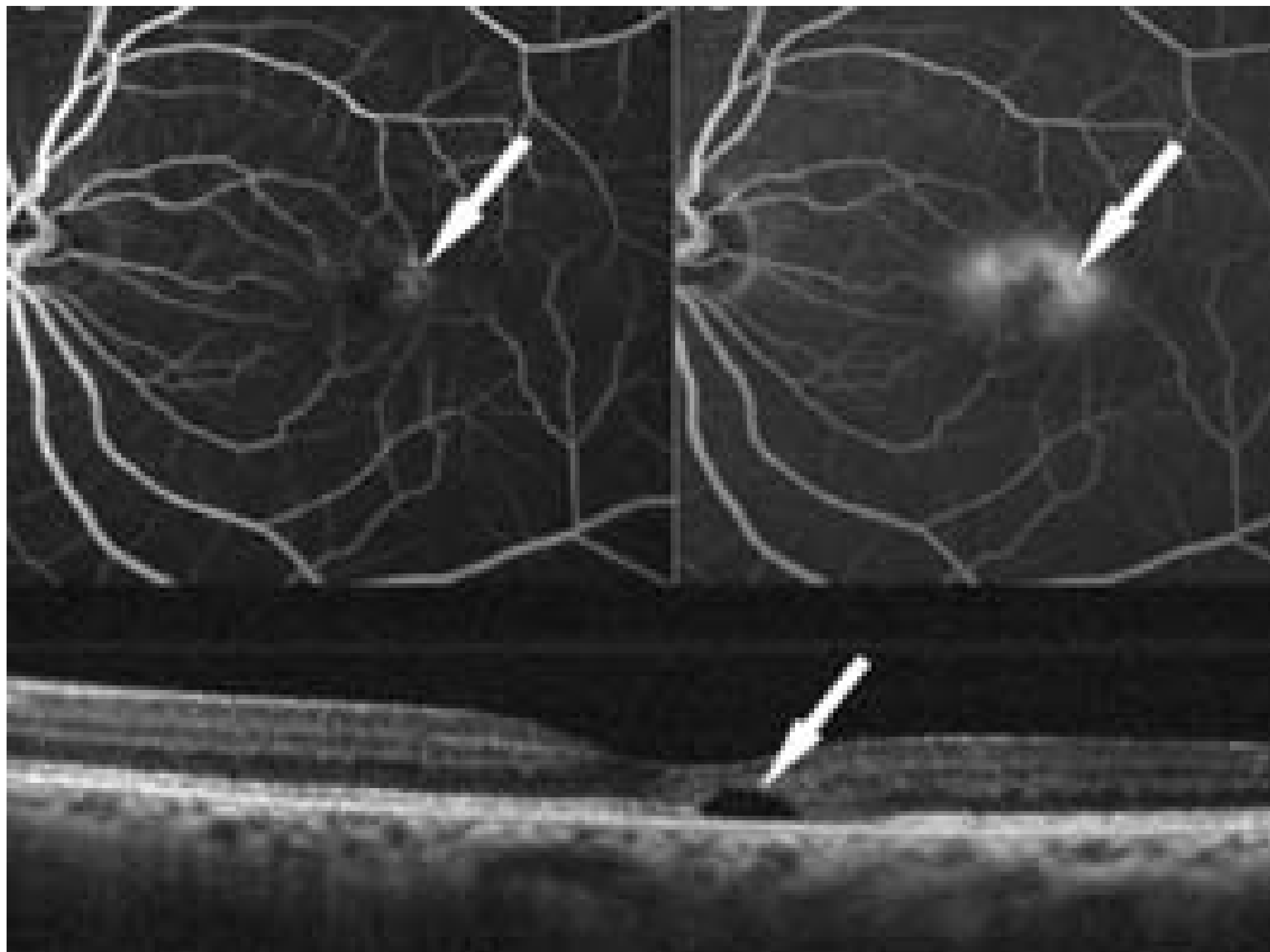
# Maküla Hastalıkları

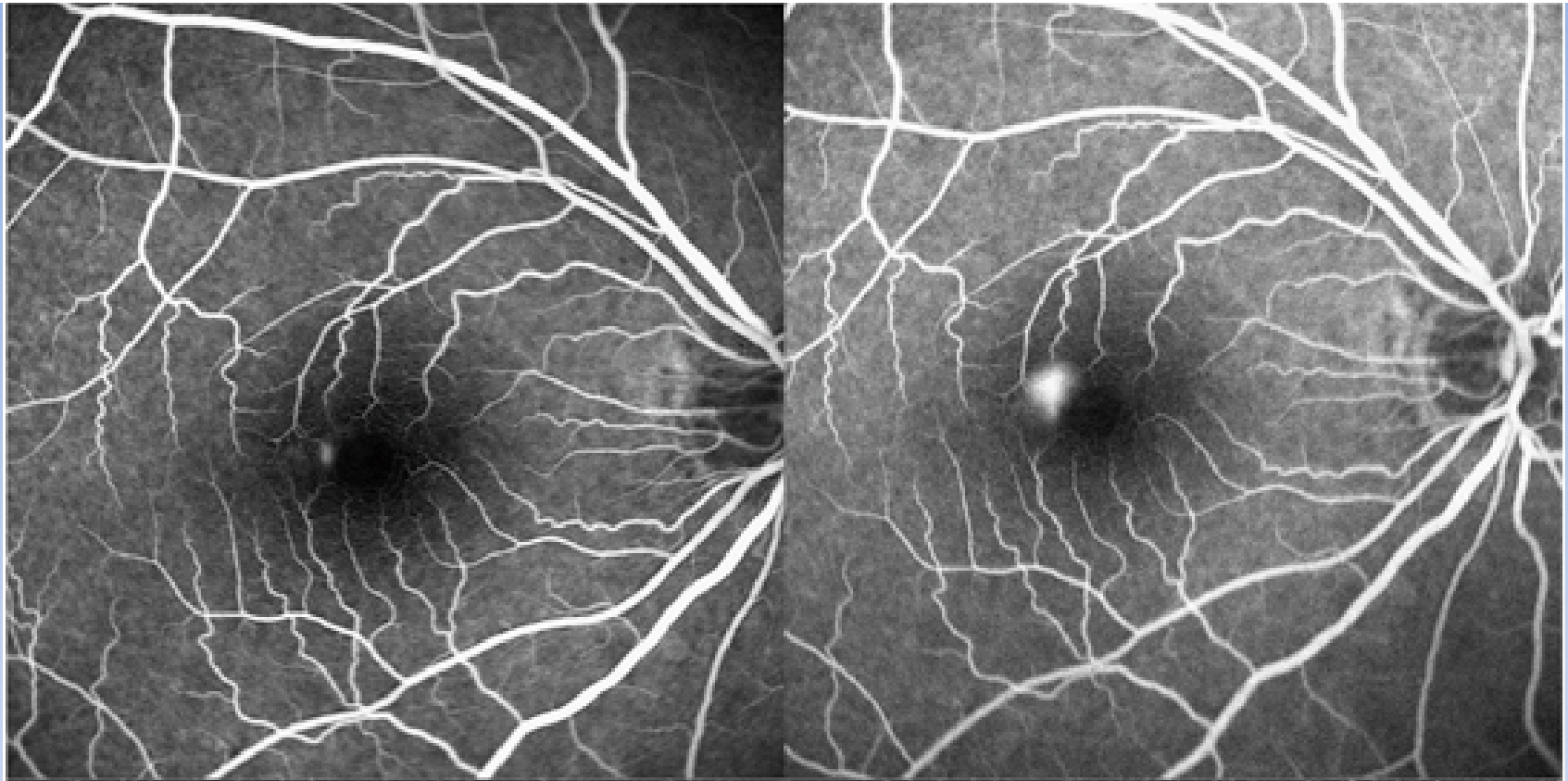
YBMD – Eşlik eden patolojiler



	FFA	OKT	İSYA
Tanı	+++	+	+
Ayırıcı tanı	+++	+	++
Lezyon sınıflaması	+++	+	-
PDT vs termal lazer	++	-	+
Prognoz değerlendirme	+	+++	-
Takip / Tekrar tedavi	+	+++	-







	FFA	ISYA	OKT
Irvine – Gass Send.	++	-	++
Diabetik makülopati	++	-	++
Retina ven tıkanıklığı	++	-	++
Üveitik makülopati	++	++	+
Vitreoretinal traksiyon	-	-	+++
İ. Maküler telenjektazi	+	-	++
YBMD	++	++	++

Coscas G (ed): Macular Edema.

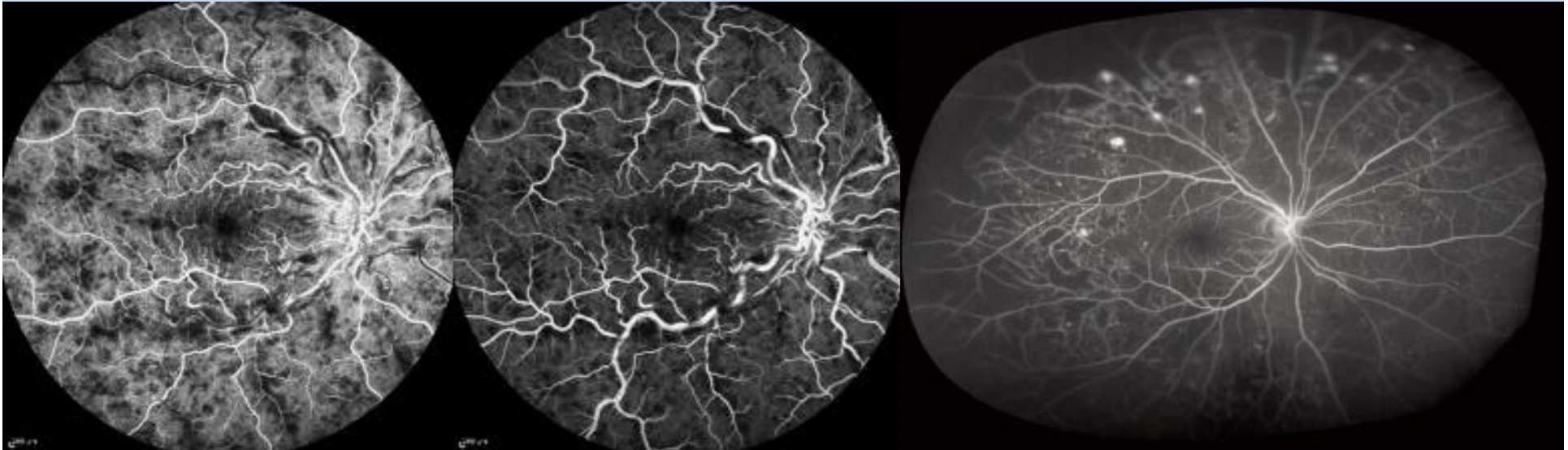
Dev Ophthalmol. Basel, Karger, 2010, vol 47, pp 27–48

## Endikasyonlar

the gold standard



FFA halen retinal vasküler sistem ve patolojilerinin değerlendirilmesinde altın standart tetkiktir



# Endikasyonlar

FFA halen retinal vasküler sistem ve patolojilerinin değerlendirilmesinde altın standart tetkiktir.

Vasküler patensi

Vasküler duvar anomalileri

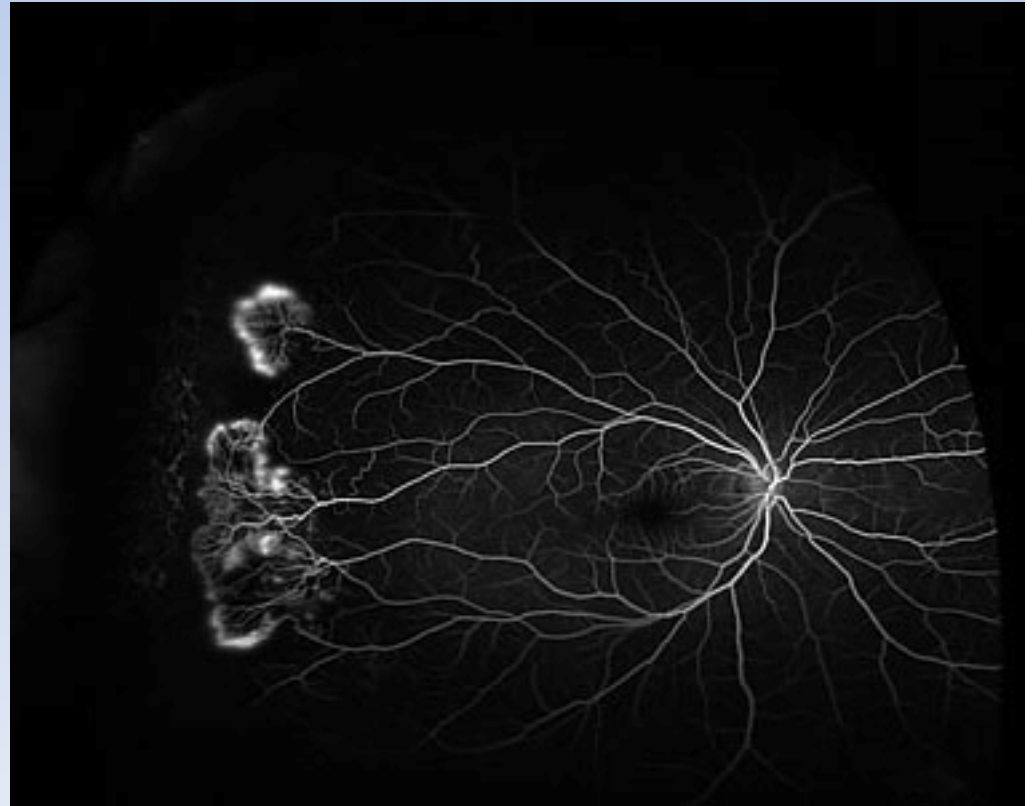
Vasküler tıkanıklık

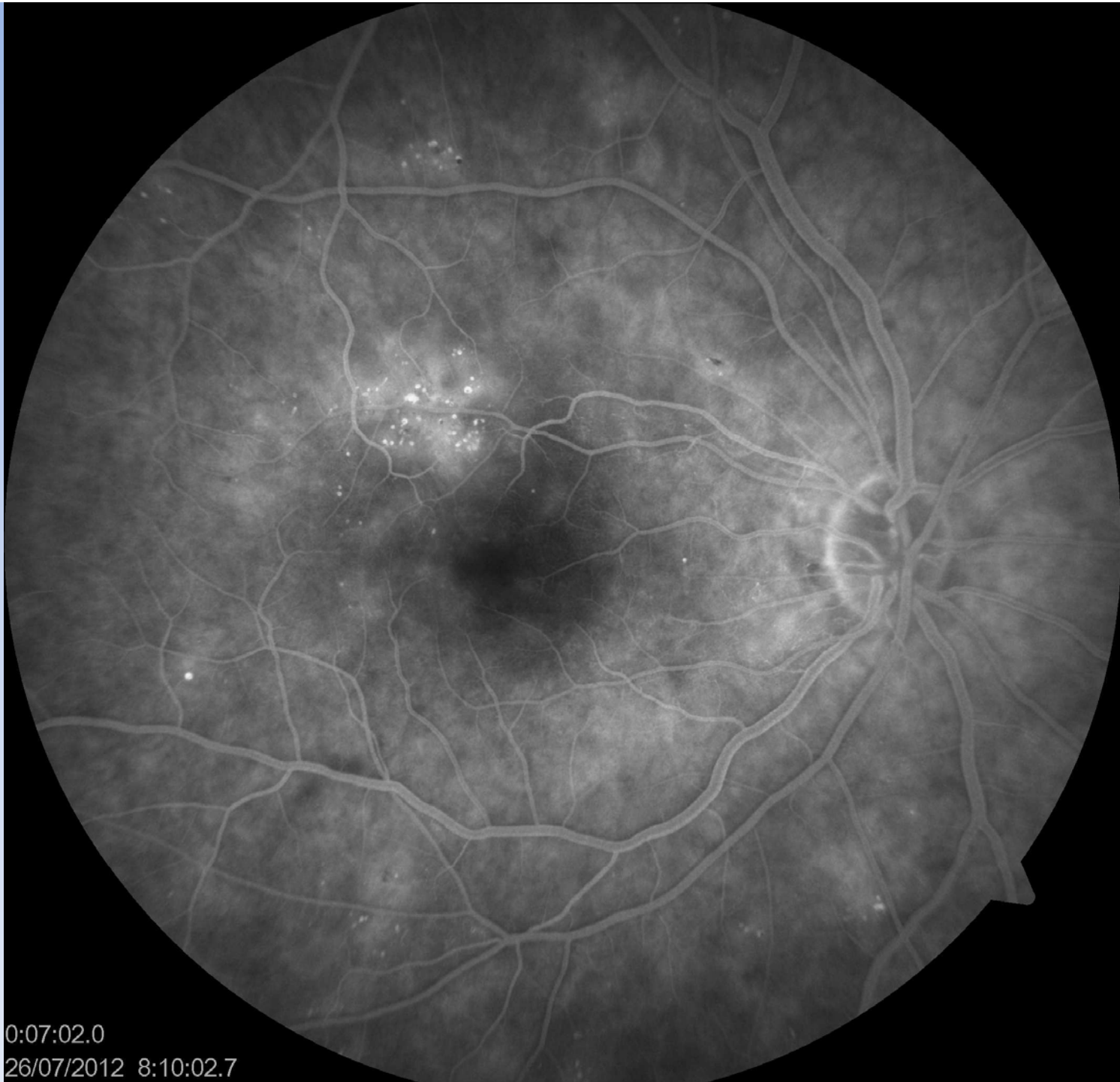Non-perfüze sahalar

Neovaskülarizasyon

Tedavi planlanma

Tedaviye yanıt





0:07:02.0  
26/07/2012 8:10:02.7

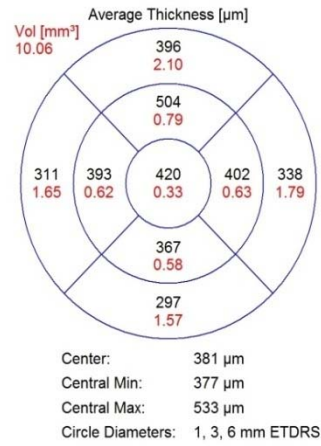
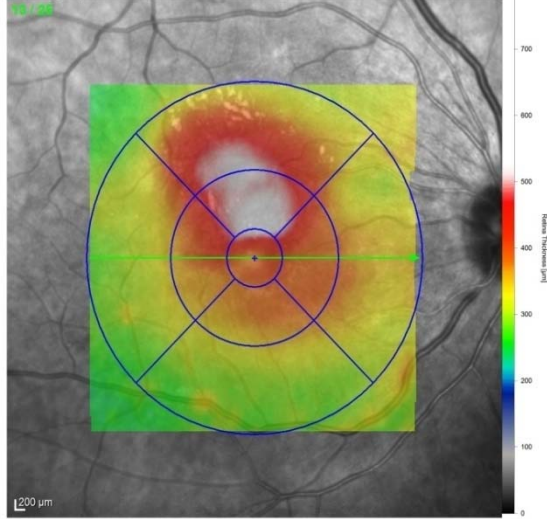
Patient: GUZEL, AYSE  
Patient ID: 6724868

DOB: Jan/01/1950  
Exam.: Jun/28/2012

Sex: F

OD

IR 30° [HS]



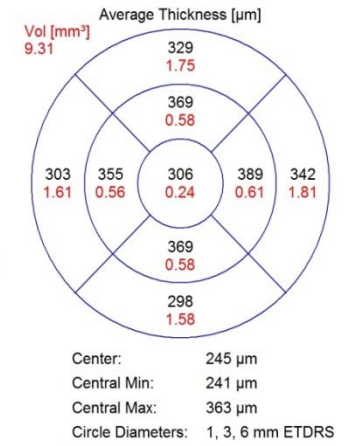
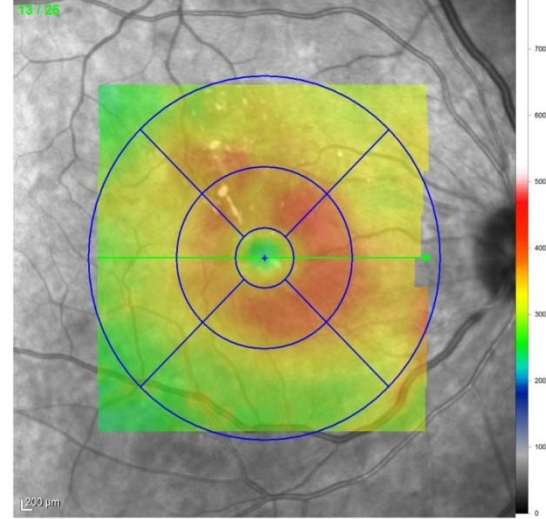
Patient: GUZEL, AYSE  
Patient ID: 6724868

DOB: Jan/01/1950  
Exam.: Jan/24/2013

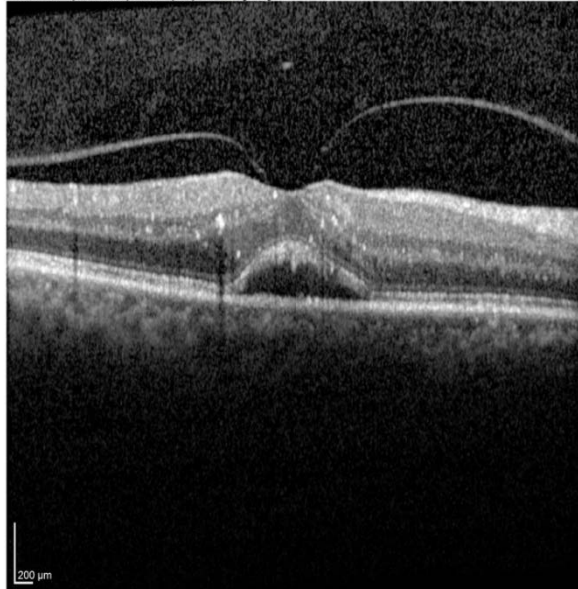Sex: F

OD

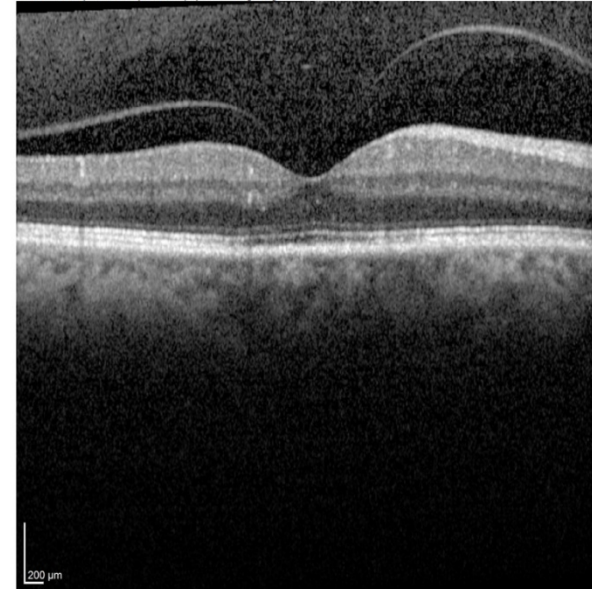
IR 30° [HS]

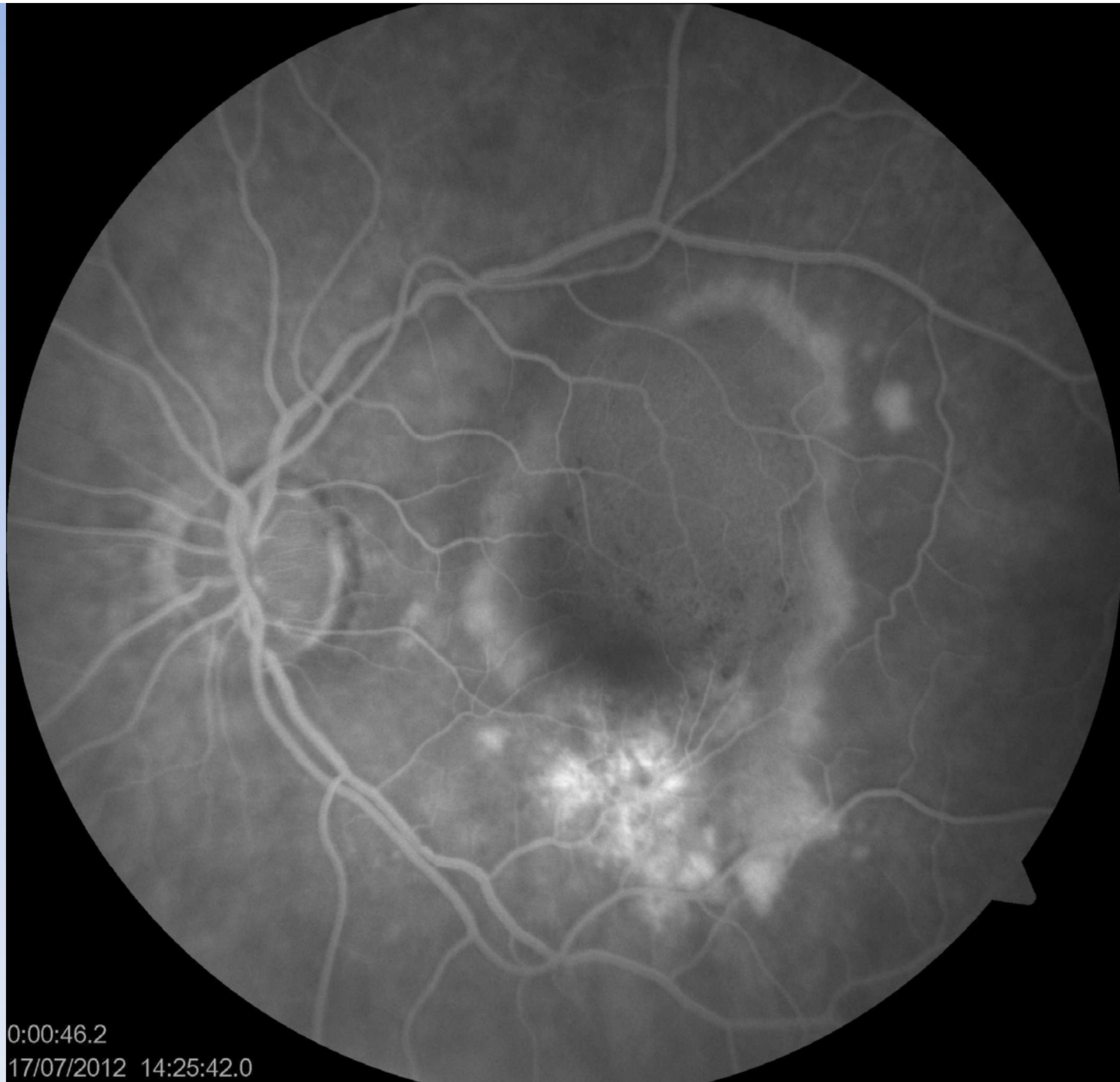

OCT 20° (5.9 mm) ART (10) Q: 19 [HS]

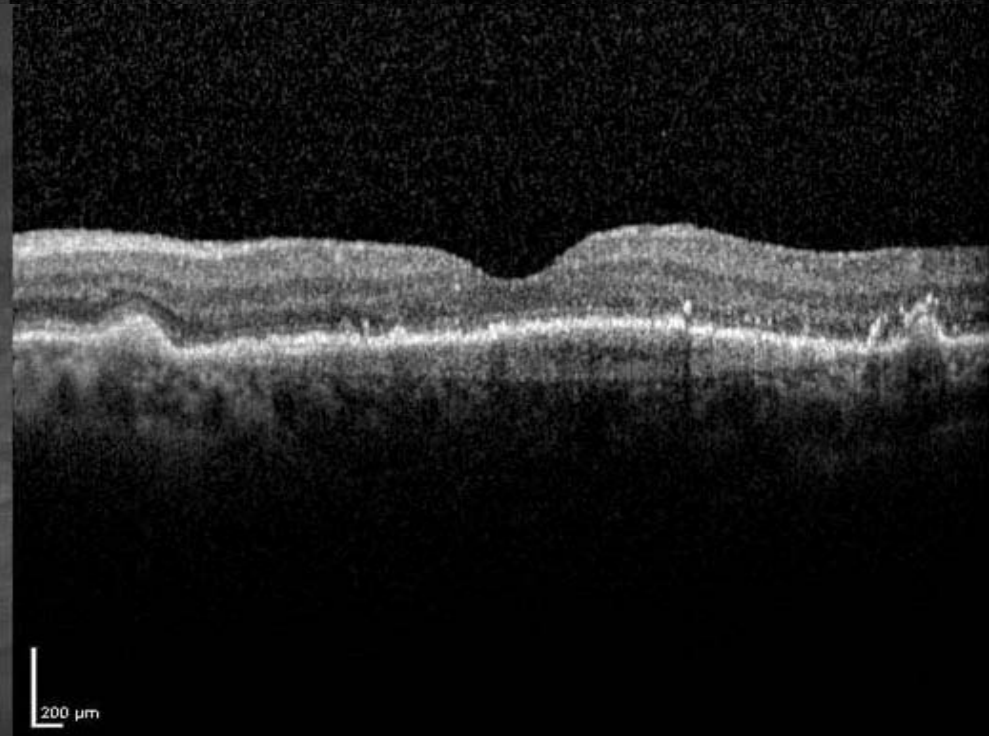
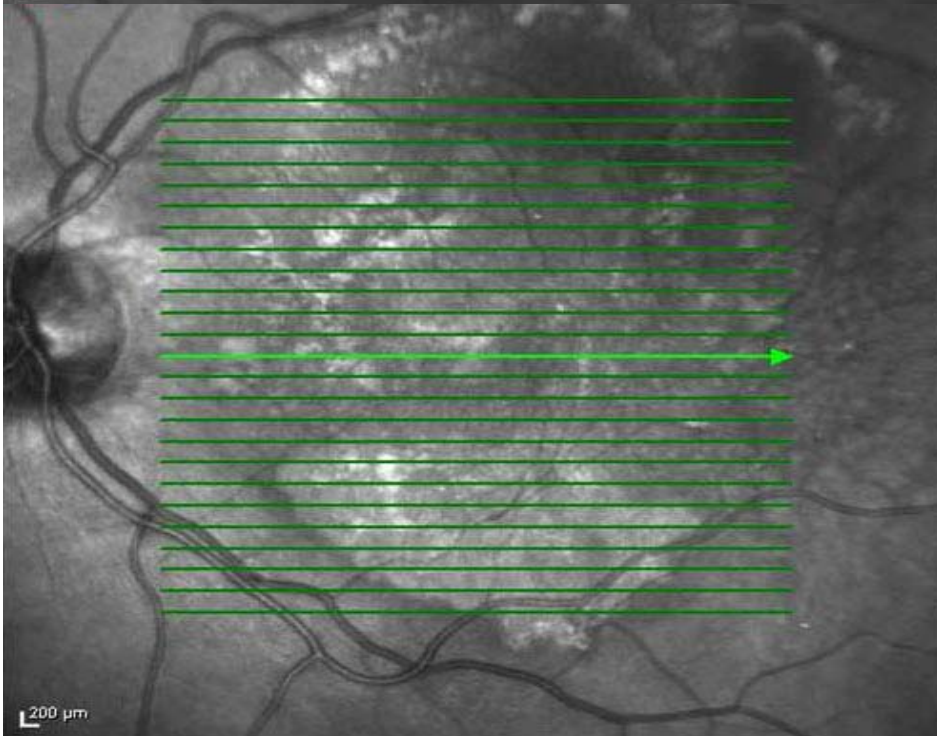
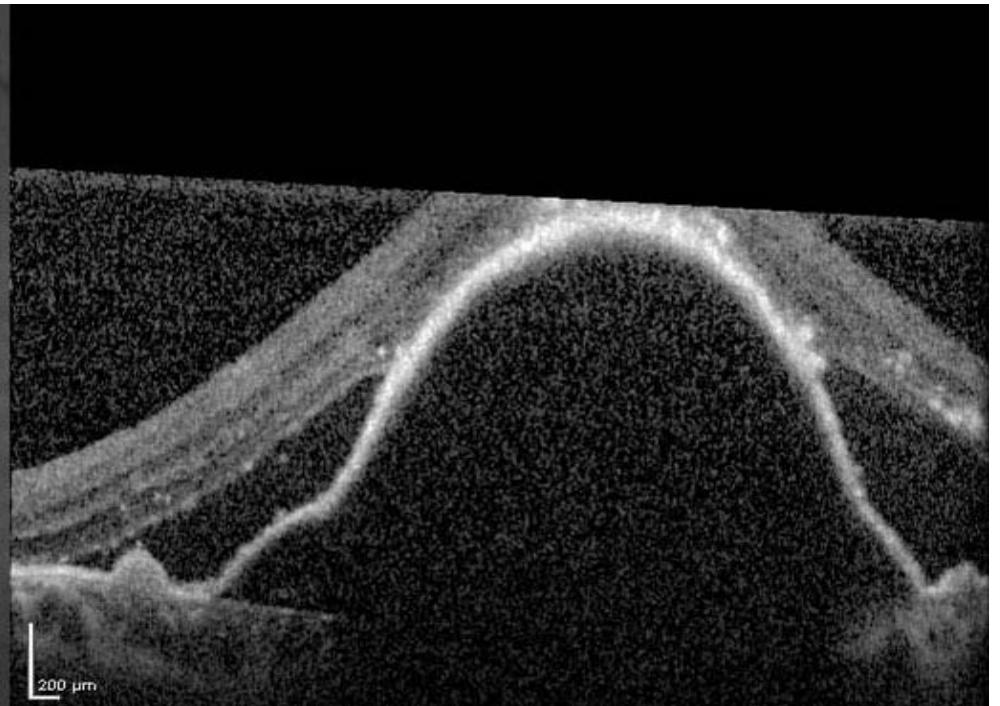
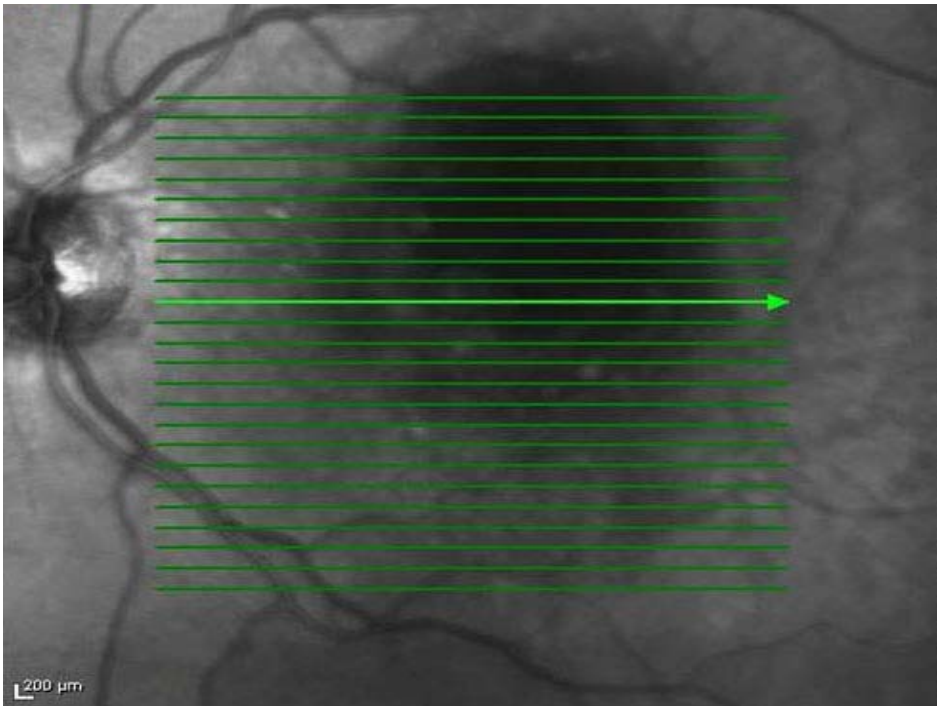


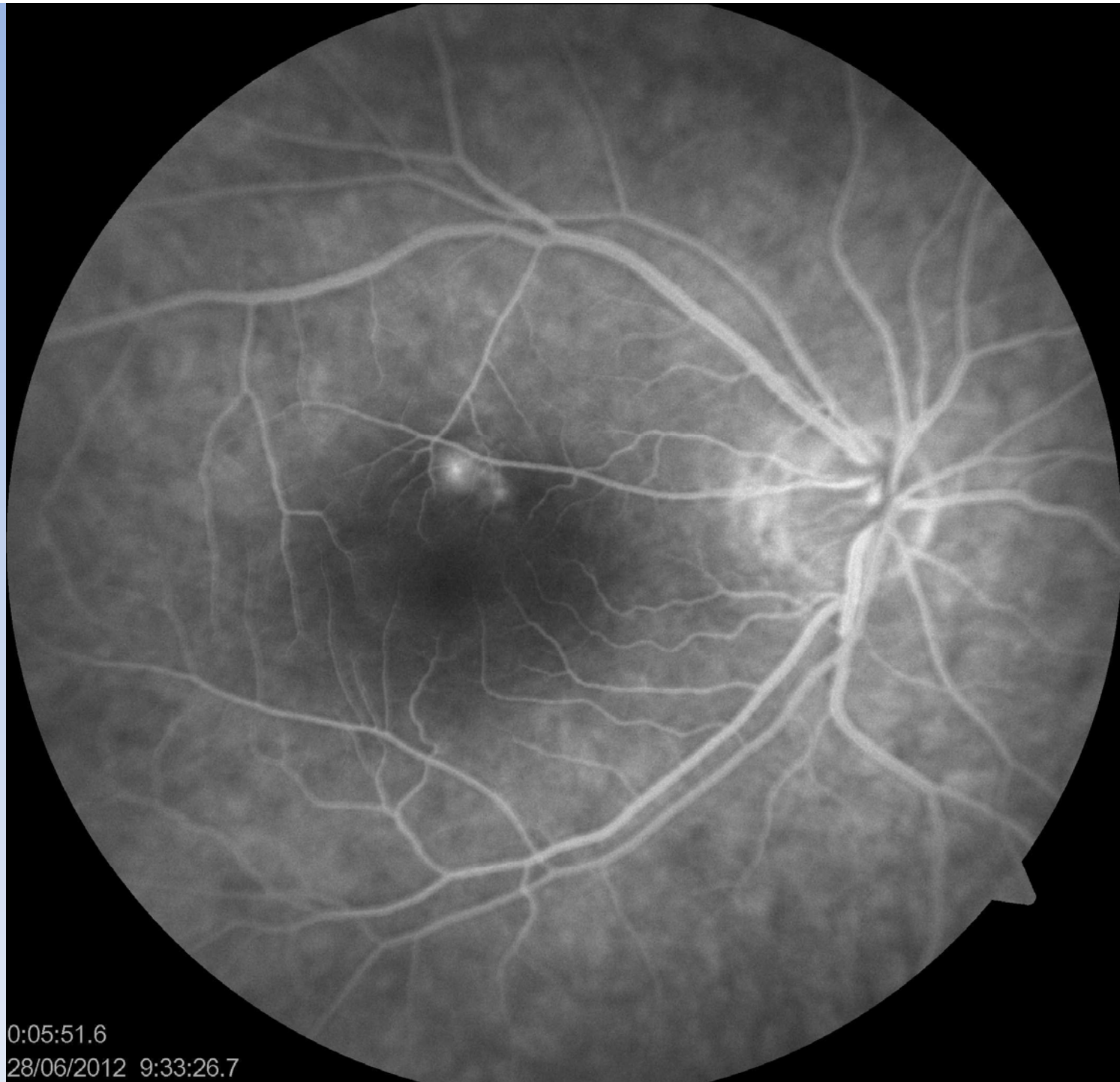OCT 20° (5.7 mm) ART (9) Q: 22 [HS]



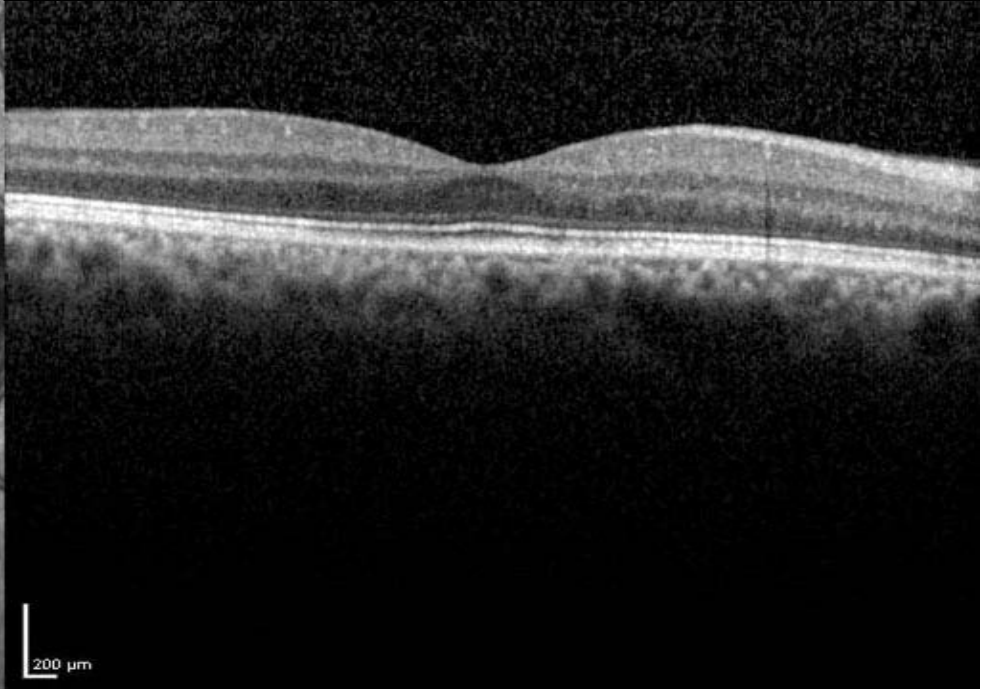
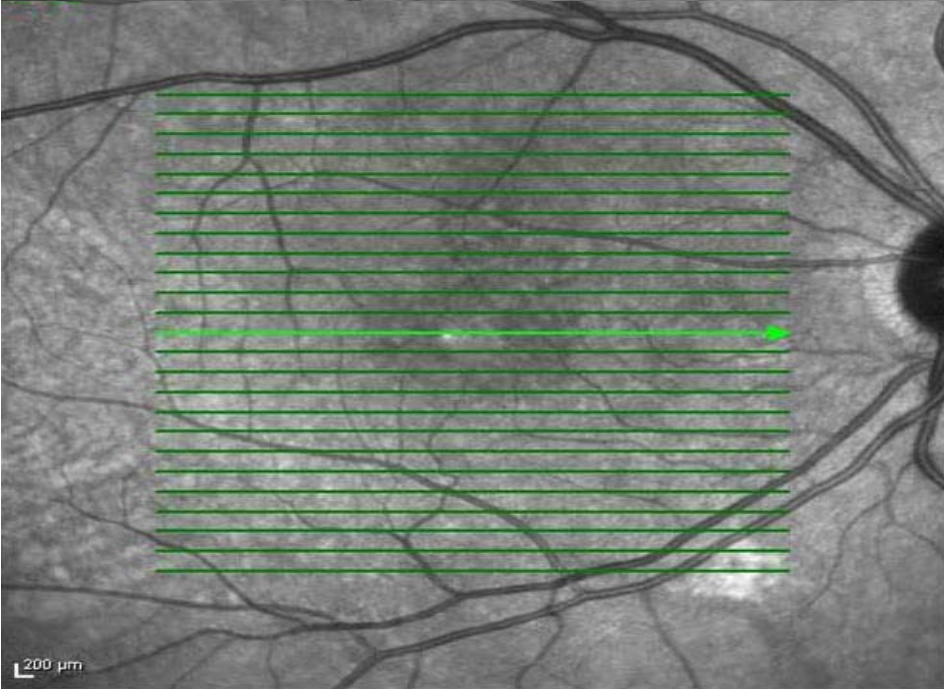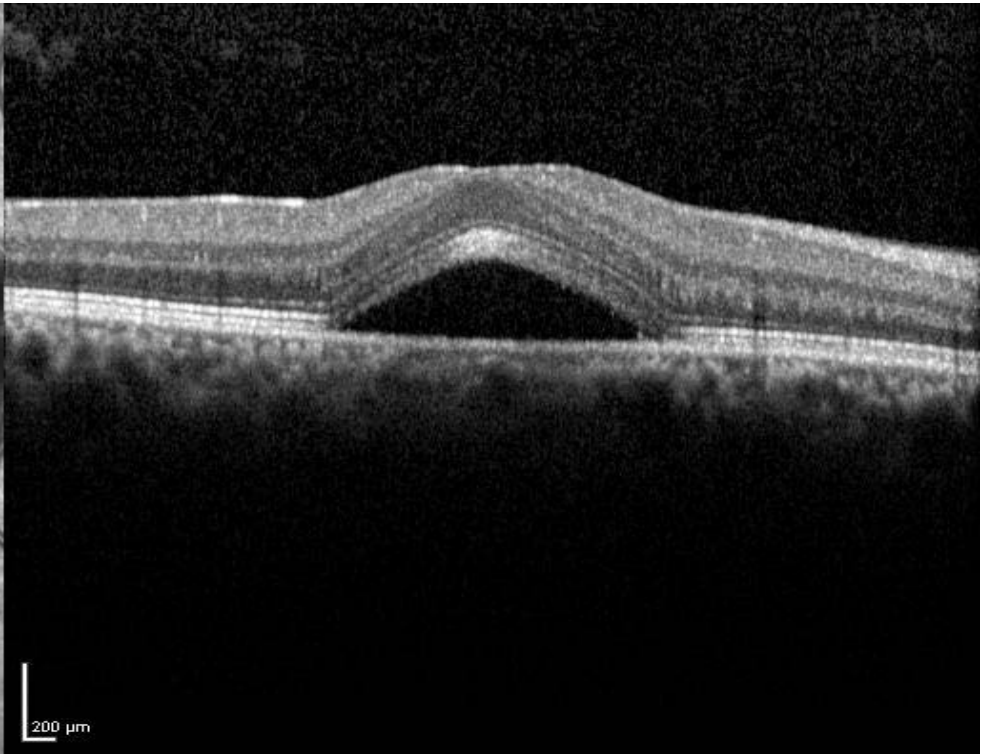
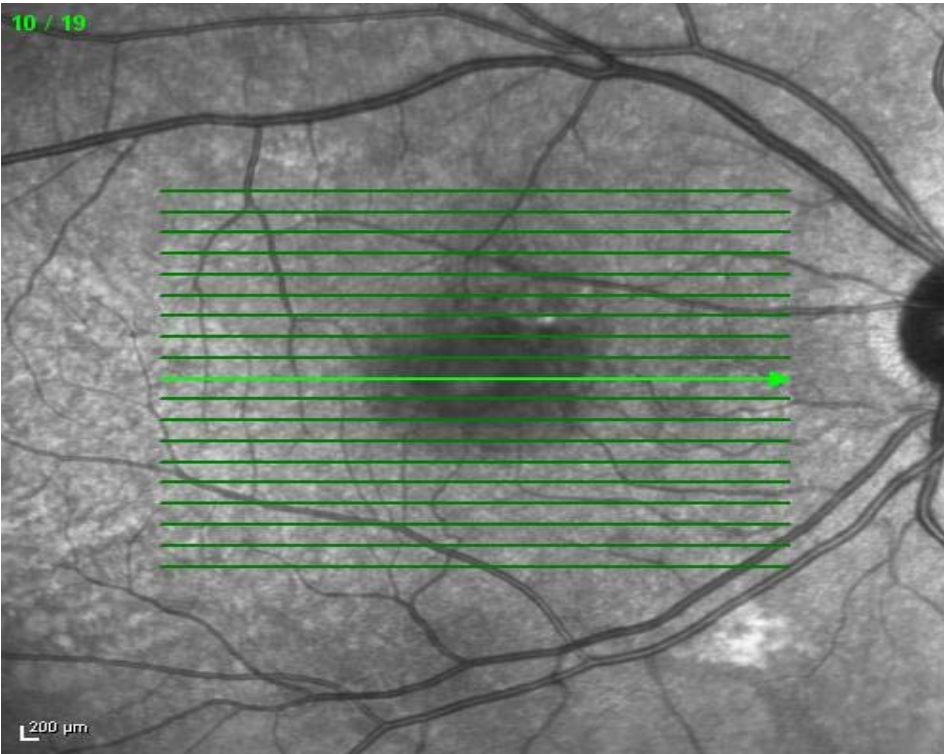


0:00:46.2  
17/07/2012 14:25:42.0





0:05:51.6  
28/06/2012 9:33:26.7



# Endikasyonlar

FFA halen retinal vasküler sistem ve patolojilerinin değerlendirilmesinde altın standart tekniktir.

Vasküler patensi

Vasküler duvar anomalileri

Vasküler tıkanıklık

Non-perfüze sahalar

Vasküler sızıntı

Tedavi planlanma

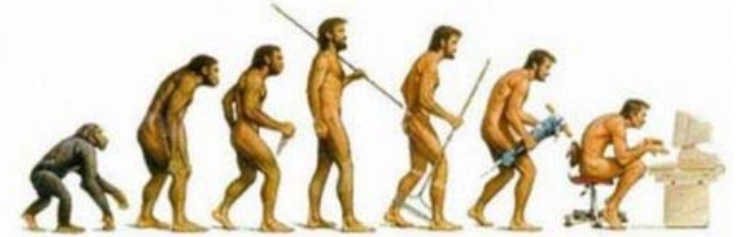

Tedaviye yanıt



## Geçmişten Günümüze FFA

■ Endikasyonlar

■ Teknik - Cihazlar



## Fotoğraf Filminden Dijital Görüntüye

Hızlı, maliyeti düşük

Yüksek kontrast, keskinlik

3MP CCD, 400 ISO'dan üstün

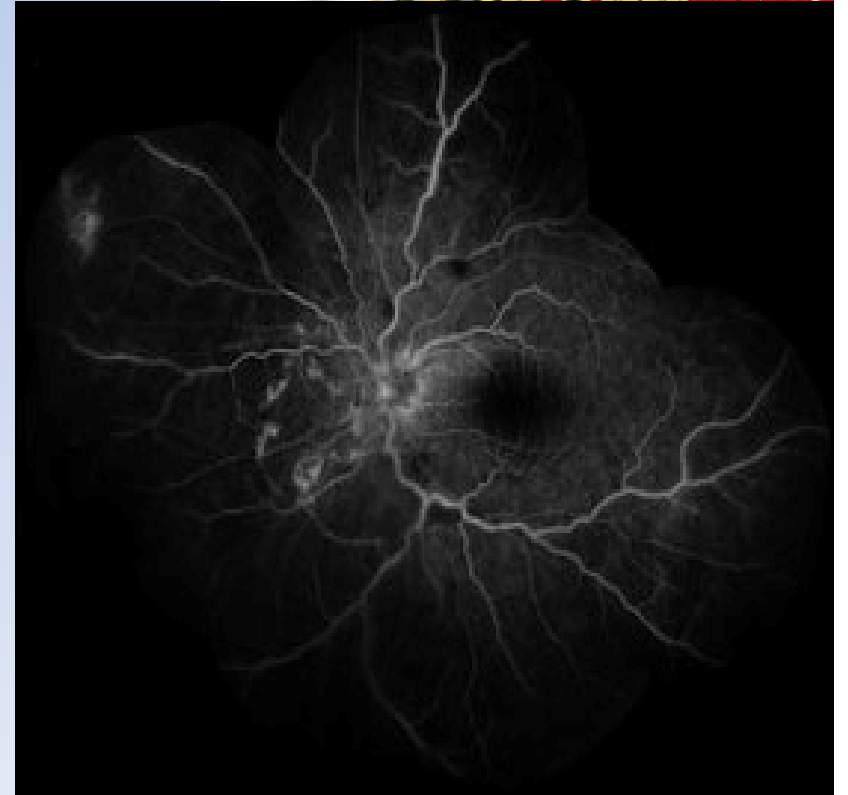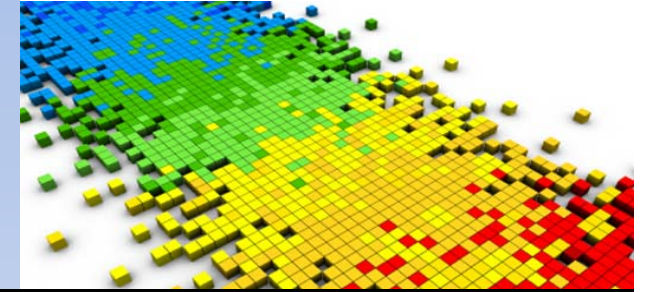
Görüntü üzerinde ölçüm yapabilme

Kompozit geniş açı

Arşivleme kolaylığı

İnternet üzerinden uzaktan erişim

Öğrenme eğrisinin kısalması



## Konfokal Tarayıcı Laser Oftalmoskop

Sodyum floreseinin etkin ekzitasyon bandında laser ışığı

488nm dalgaboylu mavi laser

Retinal ışık maruziyeti konvansiyonel FA'nin %1'i dir.

Flaş kullanılmadığı için hasta uyumu daha yüksek.

Küçük pupilladan görüntü kaydı.

Tek ve sabit dalga boylu laser ışığı kullanıldığı için

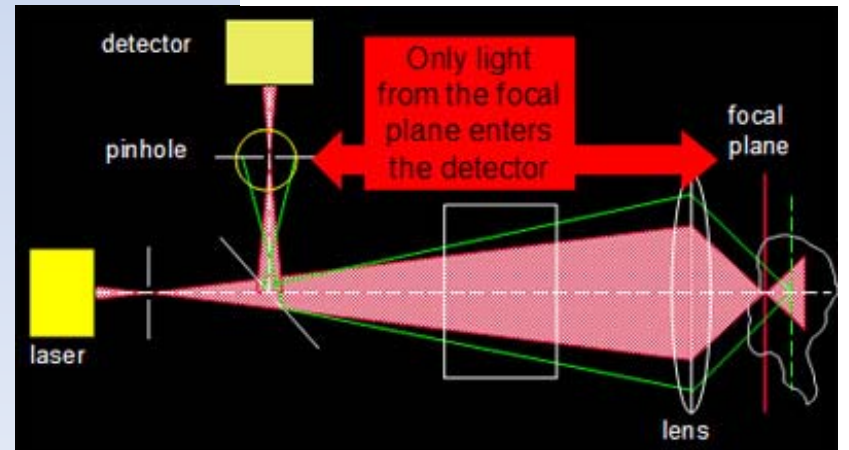
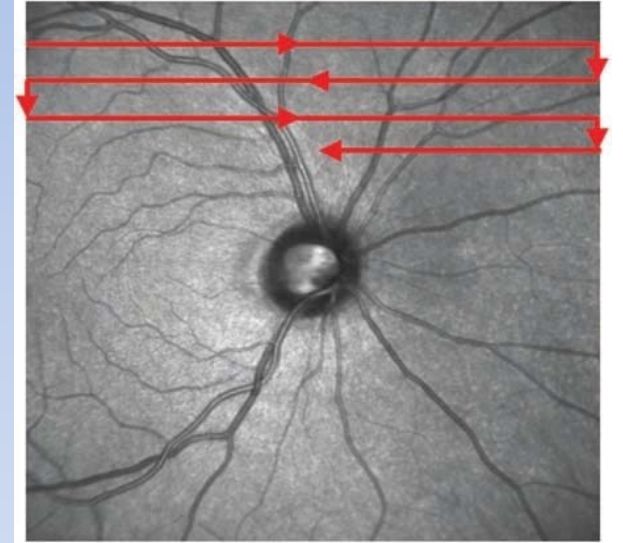

Tepe emisyon değeri yakalanır,

Bu sayede sinyal / gürültü oranı azaltılır

Retinanın fokal planına konjuge

Konfokal optik sistem

İmaj dışı saçılımın engellenir

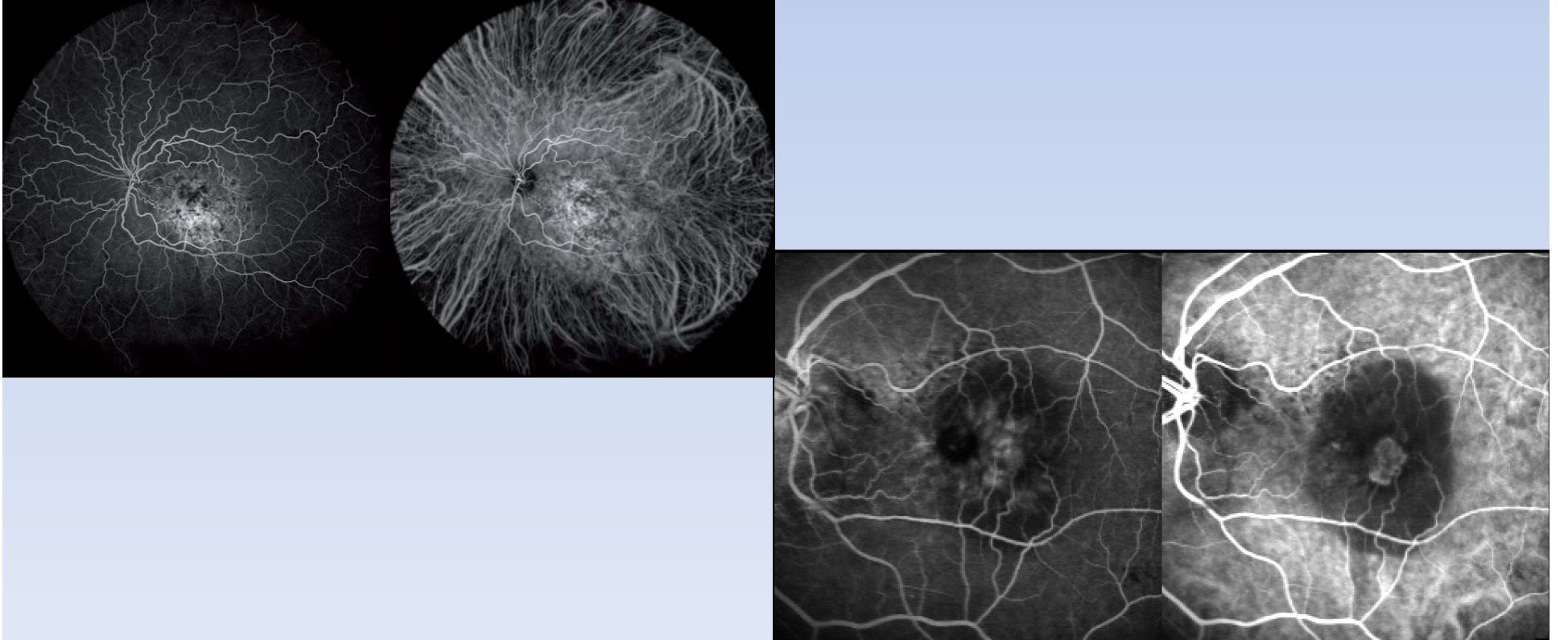


## Konfokal Tarayıcı Laser Oftalmoskop

Tek enjeksiyonla hem FA hem ICG kaydı alınabilir

(aynı anda iki farklı dalgaboylu laser ile)

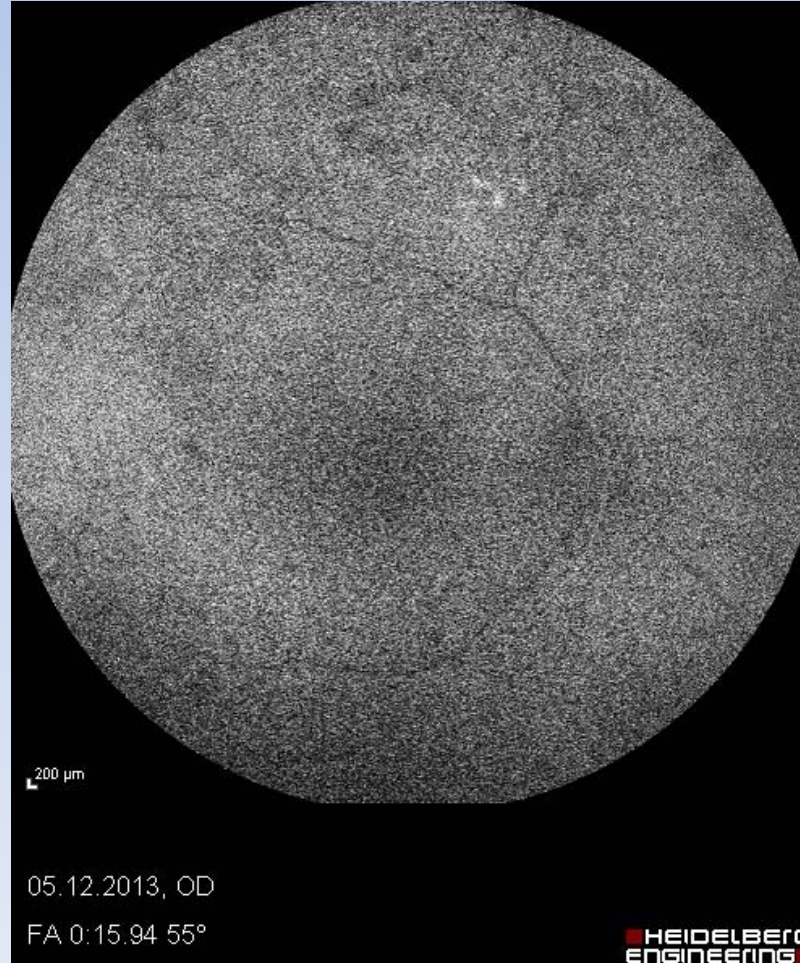
Eş zamanlı olarak retinal ve koroidal dolaşım değerlendirilebilir.



# Konfokal Tarayıcı Laser Oftalmoskop

Hızlı görüntü kaydı sayesinde dinamik görüntü kaydı yapılabilir

Hareketli görüntü – 16 frame/sn



## Geniř Aılı FFA

1926 ilk fundus kamera 20° grnt alanı

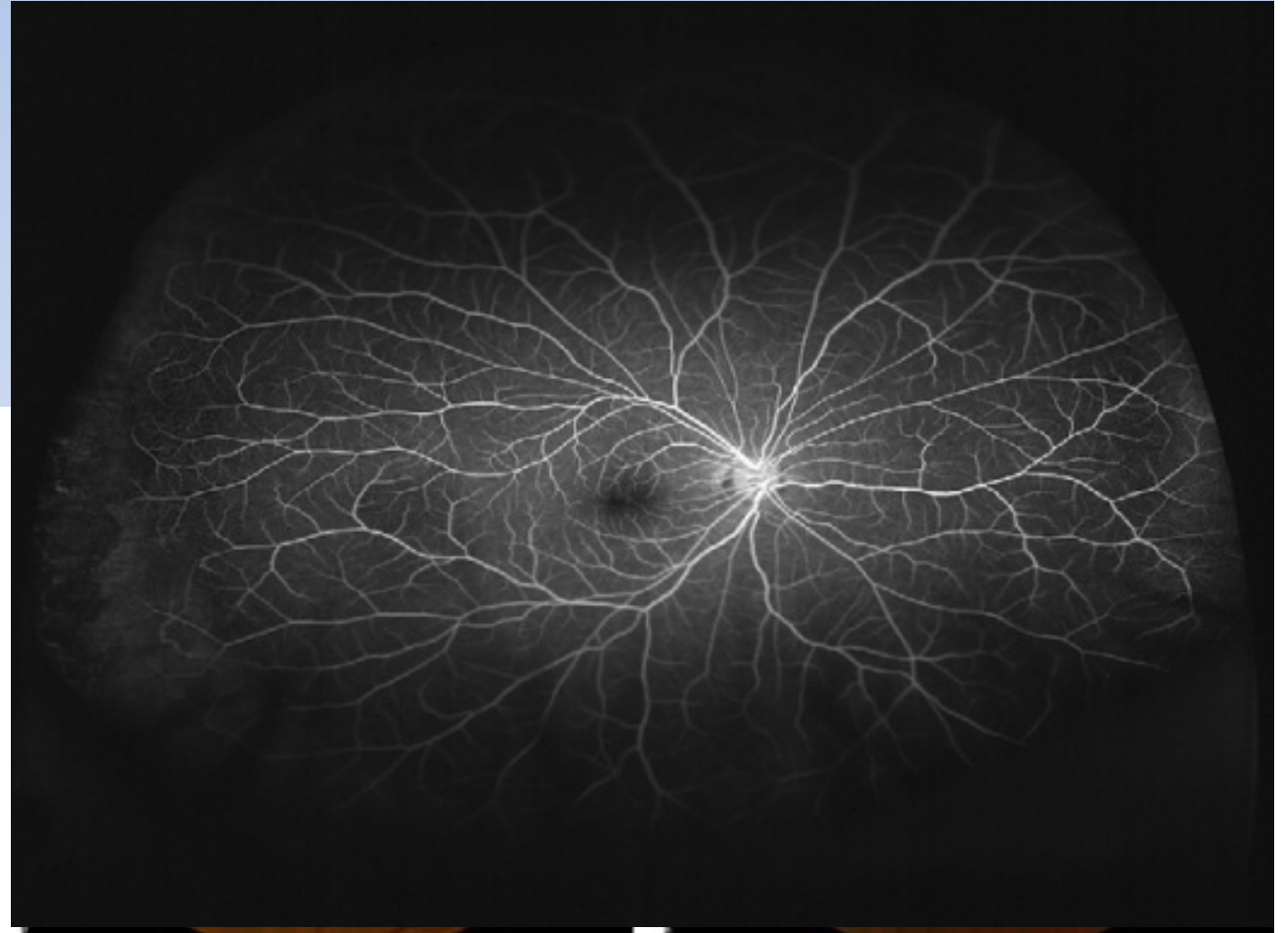
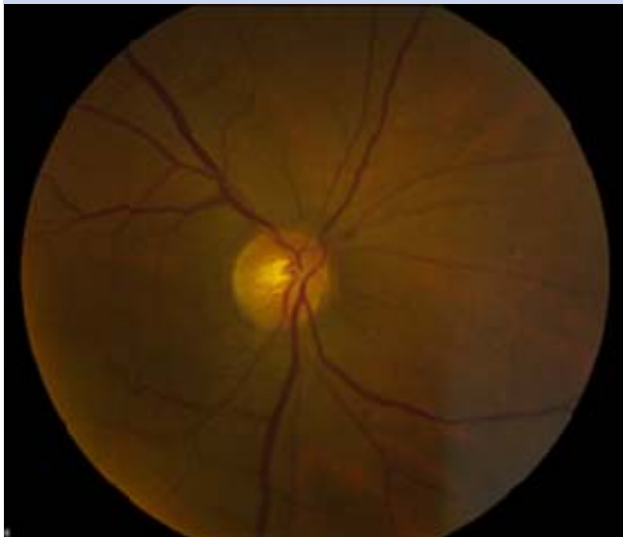Geleneksel fundus kamerada 30 -50° grntleme

200° 'ye kadar grnt alanı

Elipsoid ayna

Kk pupilladan,

Geniř alan grnts

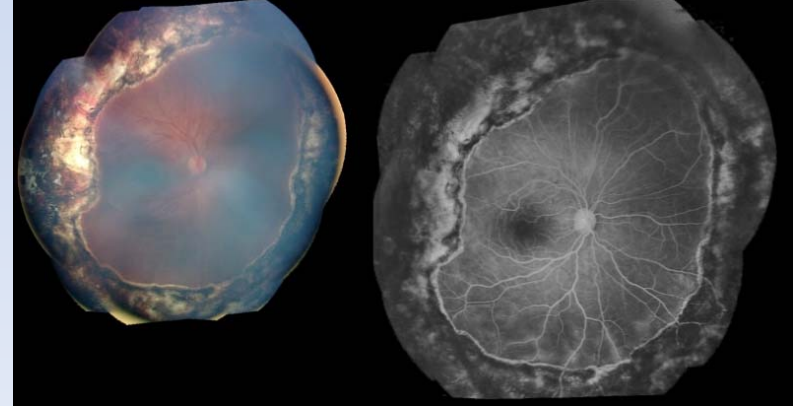
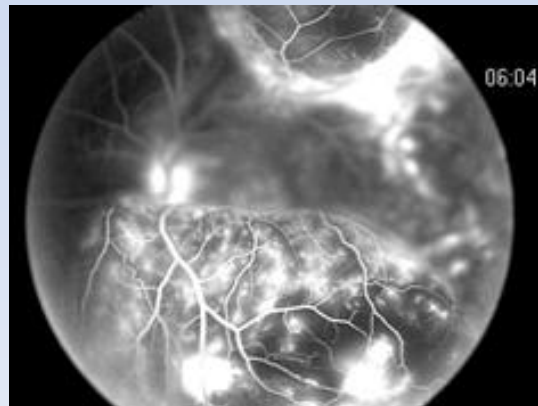
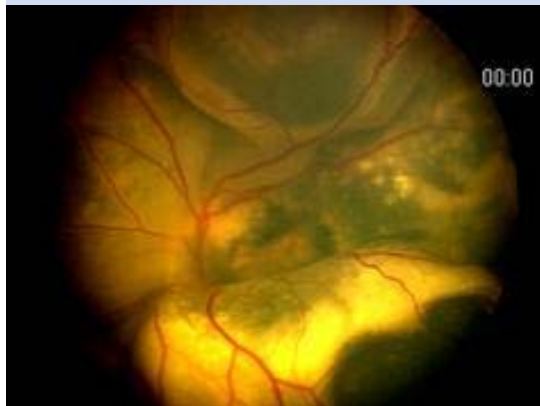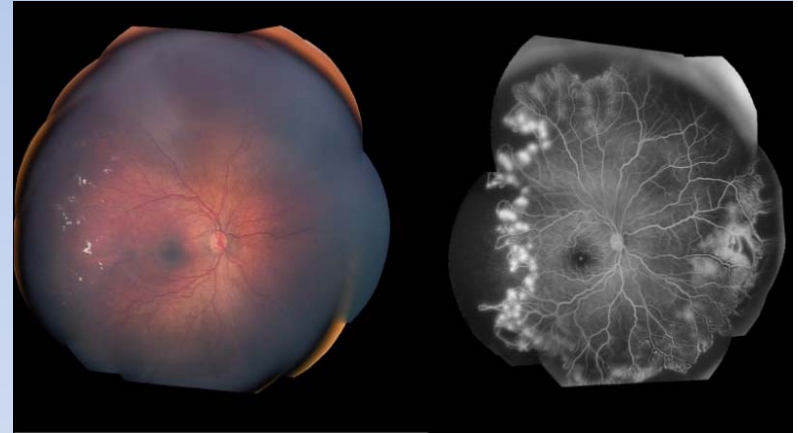

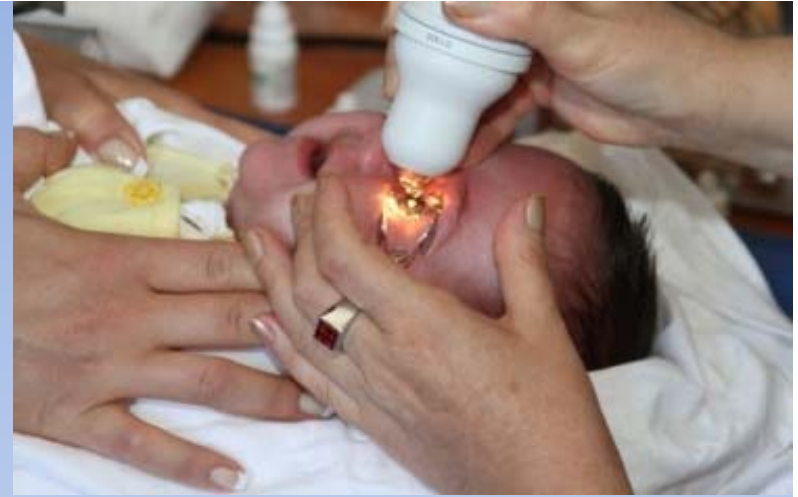
## Geniş Açılı FFA

Pediyatrik hastalar

Saydam optik alan gerektirir

Kontakt sistem - 130° görüntü alanı



## Geniş Açılı FFA

Periferal retinal görüntüleme

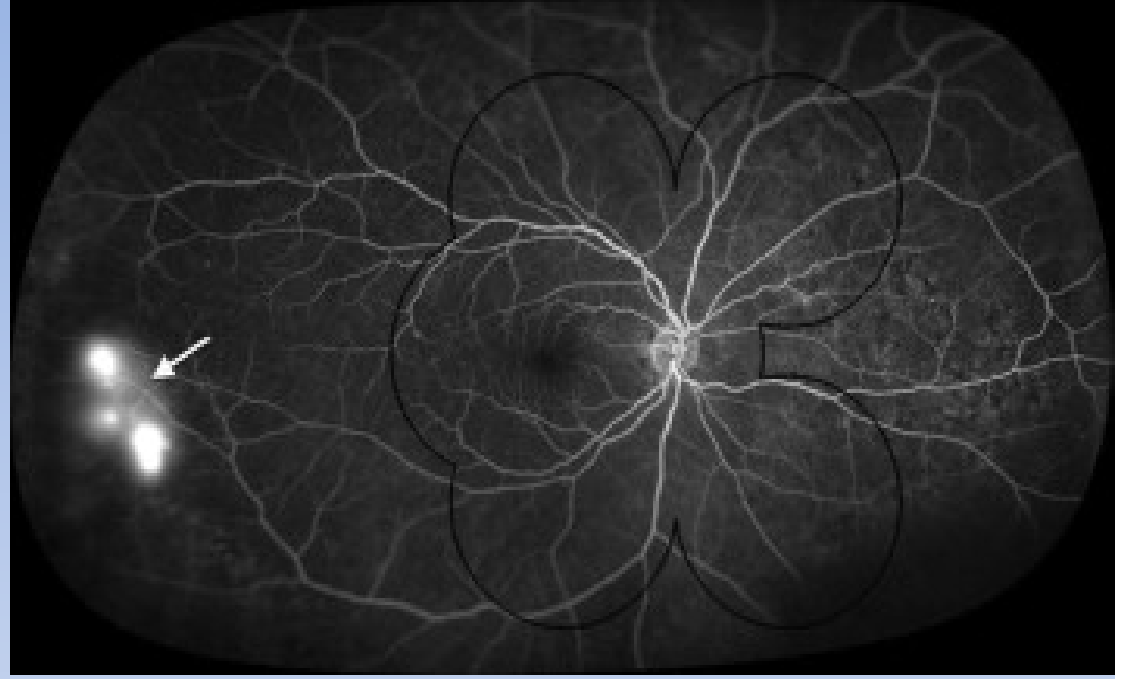
Diabetik retinopati

7 standart alan görüntüleme

30° 7 görüntü montajı – 75° görüntü alanı

Ultrageniş açı görüntüleme 7 standart alan görüntüye göre 3.2 kat daha fazla retinal alan

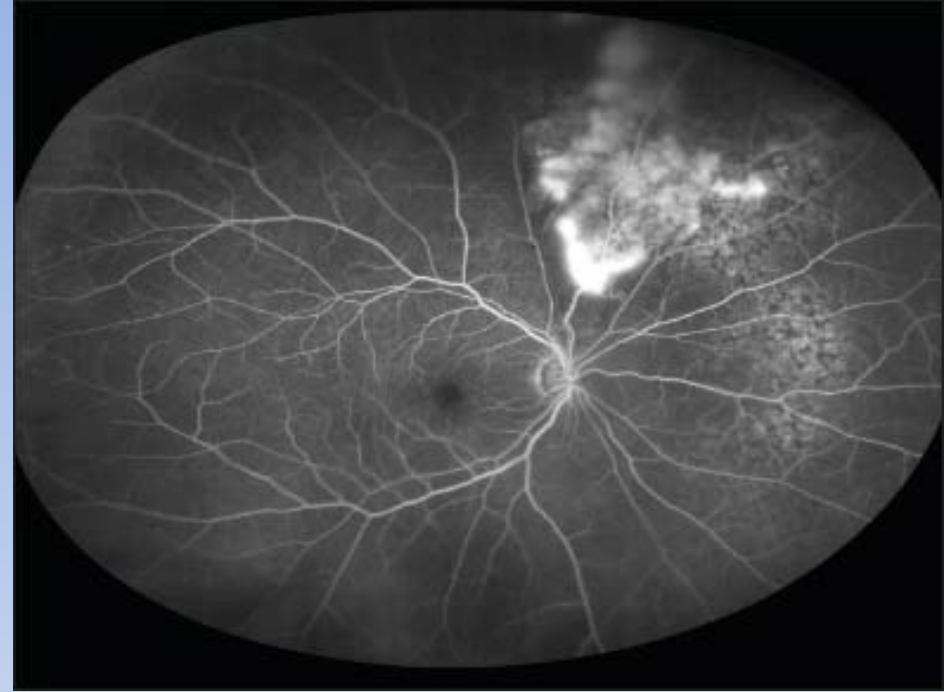Periferal non-perfüzyonu 3.9 kat, neovaskülarizasyonu 1.9 kat daha iyi gösterir.



Wessel MM, Aaker GD, Parlitsis G, et al. Ultra-wide-field angiography improves the detection and classification of diabetic retinopathy. *Retina*. 2012;32:785--91

## Geniş Açılı FFA

Retina ven oklüzyonu

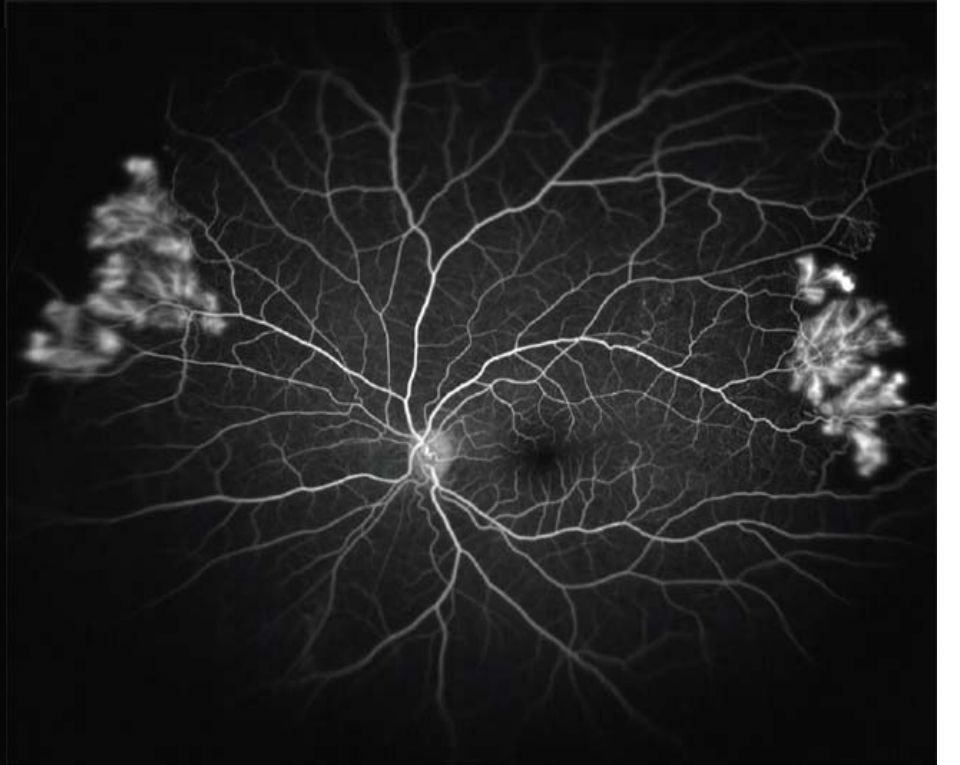
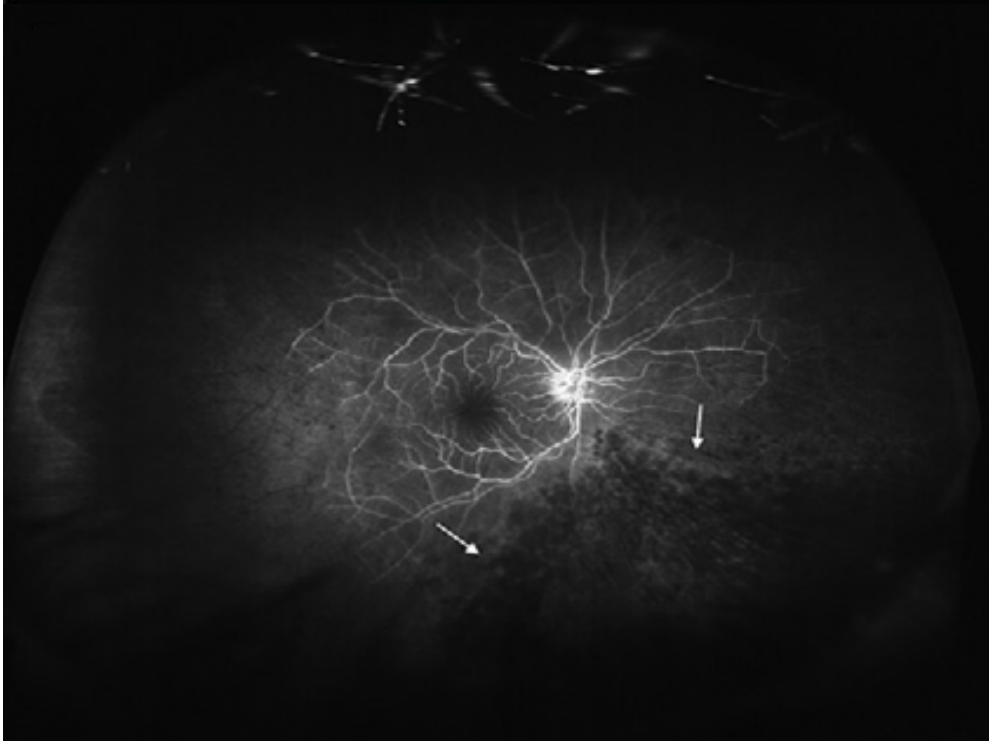
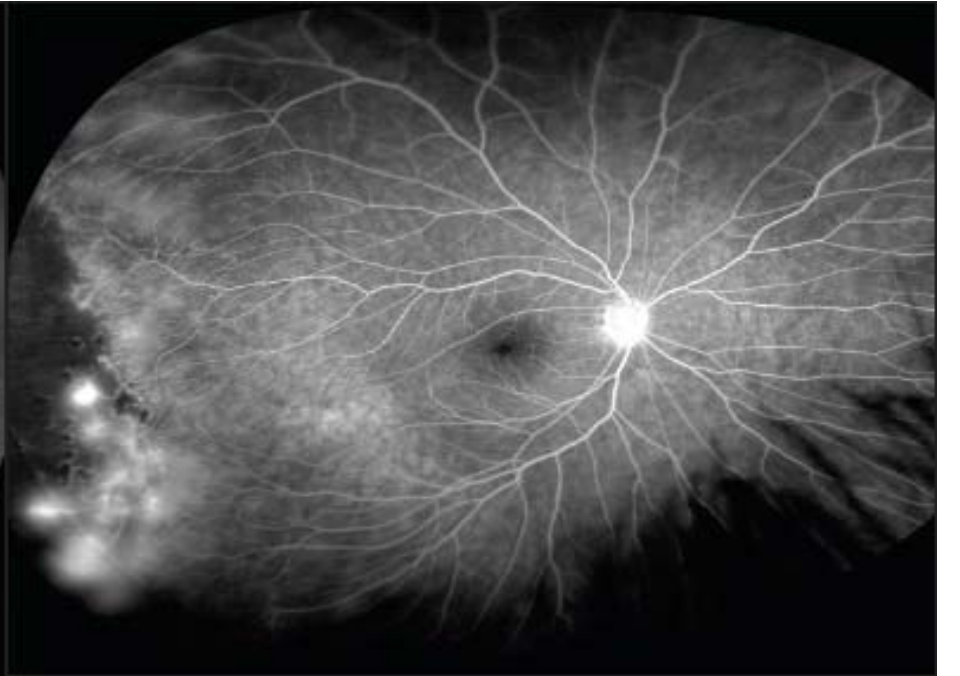
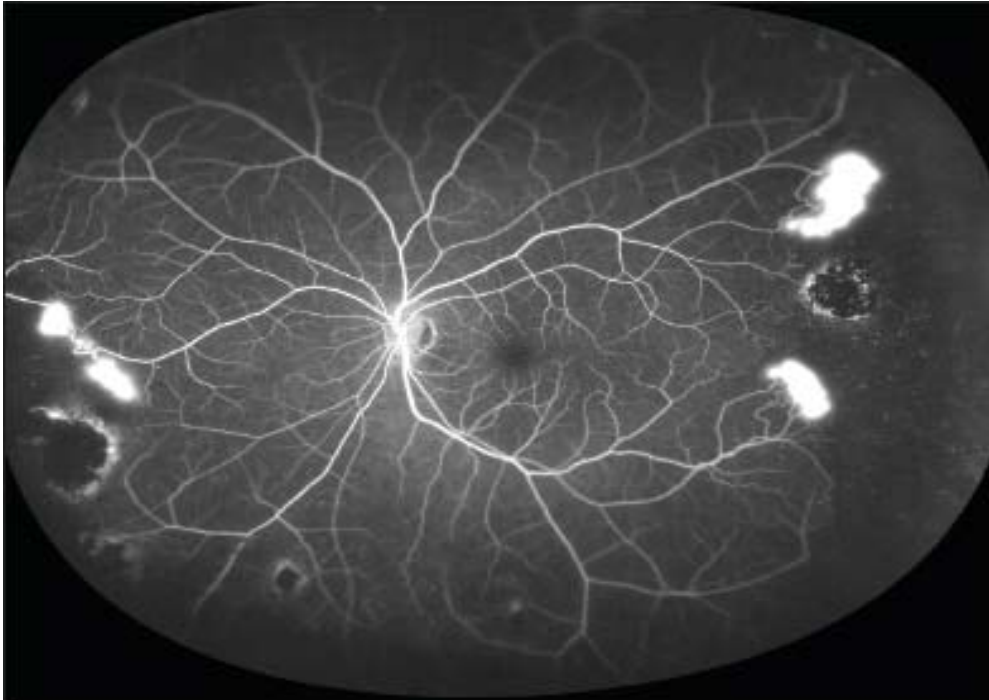

Retinal Ven dal oklüzyonu ve hemisantral retinal ven oklüzyonlarında periferal non-perfüzyon ile maküla ödemi arasında korelasyon

Anti VEGF ile tedavi edilen santral retinal ven oklüzyonlarında periferal non perfüzyon alanı ile görme keskinliği arasında negatif korelasyon

Prasad PS, Oliver SC, Coffee RE, et al. Ultra wide-field angiographic characteristics of branch retinal and hemicentral retinal vein occlusion. *Ophthalmology*. 2010;117:780—4

Spaide RF. Peripheral areas of nonperfusion in treated central retinal vein occlusion as imaged by wide-field fluorescein angiography. *Retina*. 2011;31:829--37





# New Instruments

---

## **FLUORESCCEIN FUNDUS ANGIOGRAPHY WITH SMARTPHONE**

Shin Suto, MD  
Takahiro Hiraoka, MD  
Tetsuro Oshika, MD

*From the Department of Ophthalmology, Faculty of  
Medicine, University of Tsukuba, Ibaraki, Japan.*

tric, Co, Ltd, Osaka, Japan) to control the intensity of light-emitting diode illumination was also attached because iPhone 4S and the other smartphones currently in the market have built-in light-emitting diode illumination of fixed intensity, and there are not currently any publicly available applications allowing the user to reduce the intensity.

First, we evaluated the safety of the device using a spectral radiance meter (CS-2000A; Konica Minolta Holdings, Inc, Tokyo, Japan). We placed the light



Barrier filter

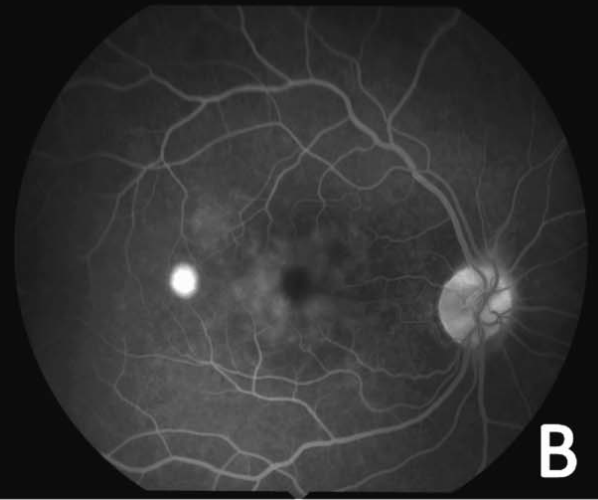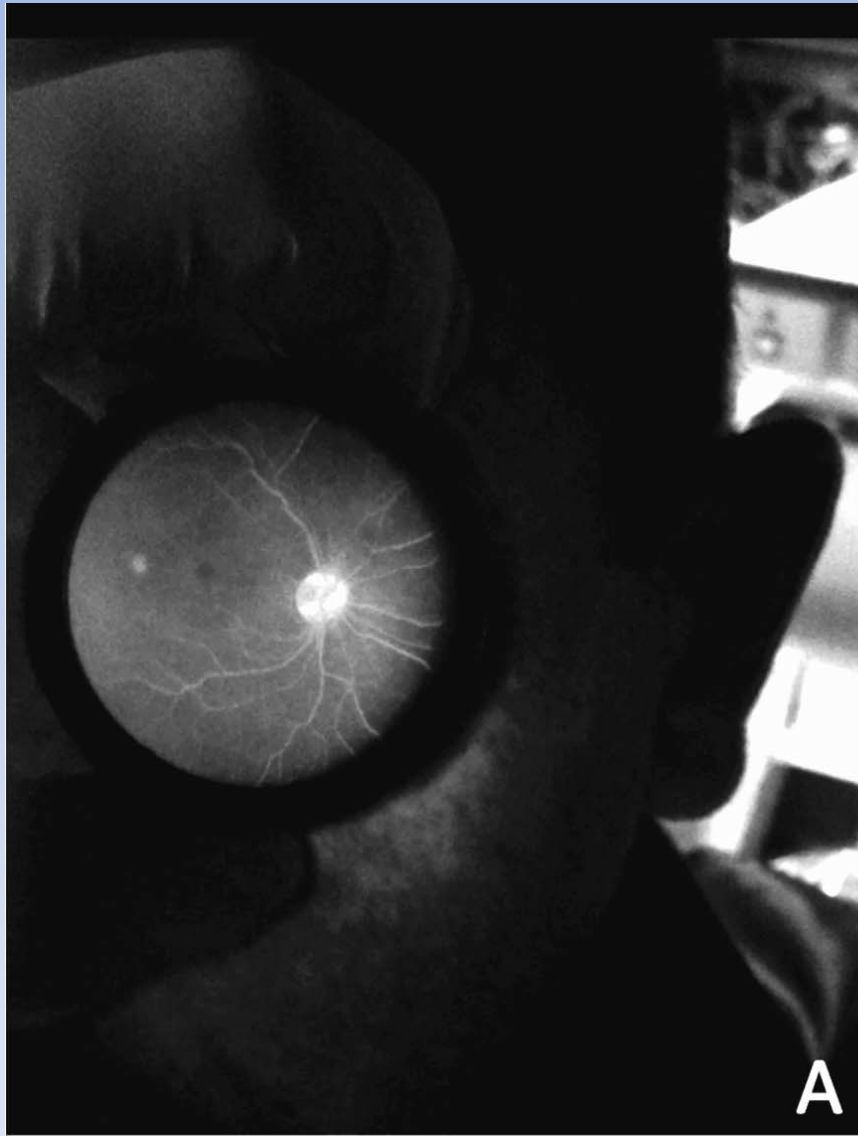
Exciter filter

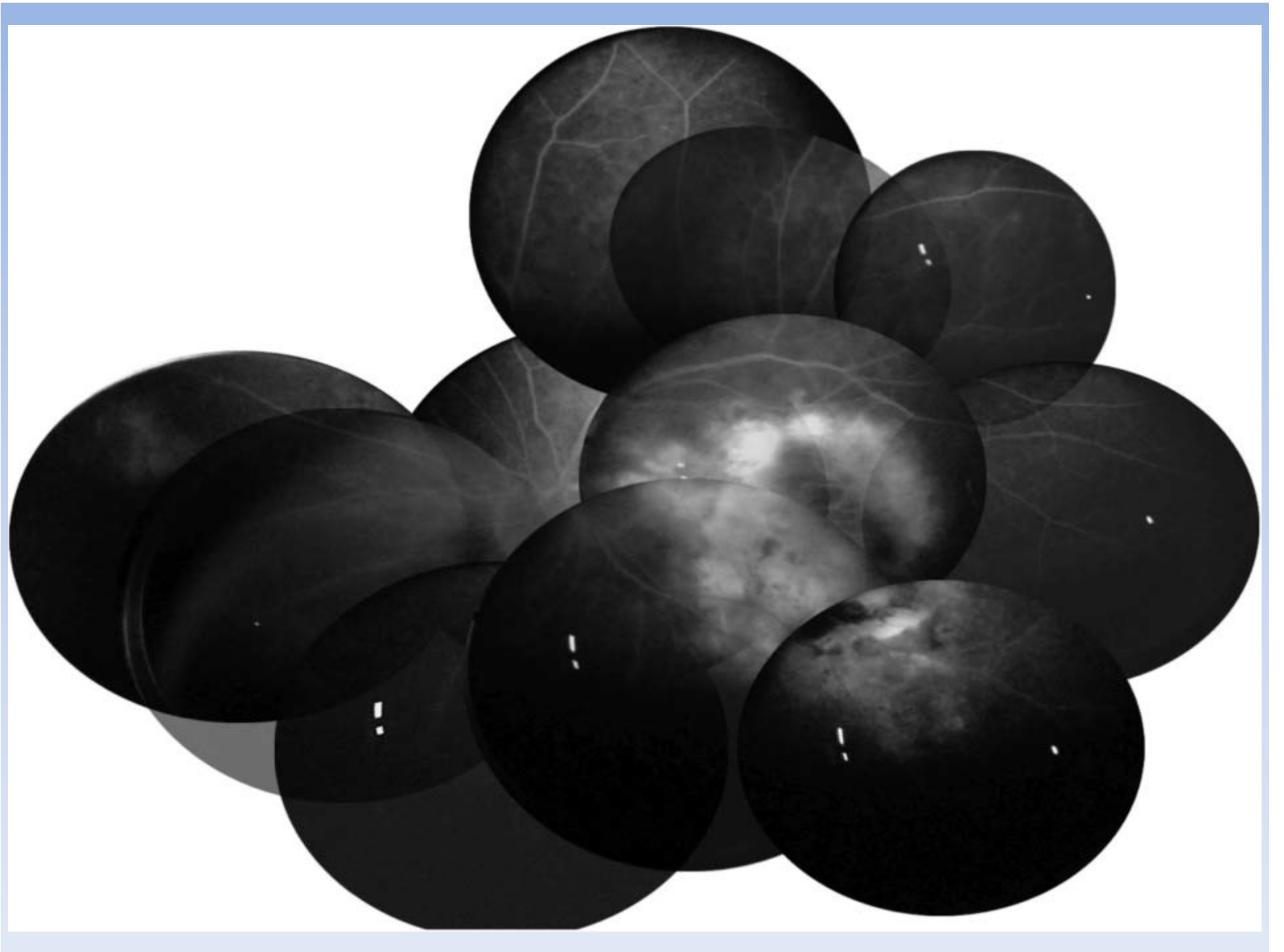
LED

Dial

Battery









## A Method of Photographing Fluorescence in Circulating Blood in the Human Retina

By HAROLD R. NOVOTNY, B.S., AND DAVID L. ALVIS, M.D.

**T**HE PHYSIOPATHOLOGY of the retinal vasculature would be better understood if more were known about blood flow in these vessels. Because of the unique quality of transparency in the eye, methods depending on direct observation of the retinal vessels seem especially inviting. Already reported by various authors are techniques for

emitting wave length was  $520\text{ m}\mu$ , in the green. Kodak wratten filters no. 47 and no. 58, combined with a 3-mm. layer of 0.25 M copper sulfate, were accordingly inserted into the optical system (figs. 1 and 2) at appropriate points.

In order to modify the activating light, the blue no.-47 filter was placed in the path of the beam from the electronic flash and from the incandescent viewing source. This made it possible to see, as well as to photograph, the fluorescence

