



Recurrent Anaphylaxis: An Unruptured Splenic Hydatid Cyst as an Unusual Cause

Tekrarlayan Anafilaksi: Olağandışı Bir Neden Olarak Rüptür Gelişmemiş Splenik Hidatid Kist

Cem Onur KIRAC¹, Ramazan UÇAR², Şevket ARSLAN², Halil İbrahim TAŞCI³, Ahmet Zafer ÇALIŞKANER²

¹ Department of Internal Medicine, Necmettin Erbakan University, Meram Faculty of Medicine, Konya, Turkey
Necmettin Erbakan Üniversitesi, Meram Tıp Fakültesi, İç Hastalıkları Anabilim Dalı, Konya, Türkiye

² Department of Clinical Immunology and Allergy, Necmettin Erbakan University, Meram Faculty of Medicine, Konya, Turkey
Necmettin Erbakan Üniversitesi, Meram Tıp Fakültesi, Klinik İmmünoloji ve Allerji Bilim Dalı, Konya, Türkiye

³ Department of General Surgery, Necmettin Erbakan University, Meram Faculty of Medicine, Konya, Turkey
Necmettin Erbakan Üniversitesi, Meram Tıp Fakültesi, Genel Cerrahi Anabilim Dalı, Konya, Türkiye

ABSTRACT

Anaphylaxis is an acute onset systemic hypersensitivity reaction that may result in death. Drugs, idiopathic triggers, Hymenoptera venom and food are the most common causes of anaphylaxis. In patients with a recurrent history of anaphylaxis and elevated IgE levels without evident etiology, spontaneous hydatid cyst rupture should be considered, especially in endemic areas.

Key words: Anaphylaxis, IgE, hydatid cyst

Received: 06/01/2016 • **Accepted:** 11/05/2016

ÖZ

Anafilaksi ölümlü sonuçlanabilecek ani başlangıçlı bir sistemik aşırı duyarlılık reaksiyonudur. İlaçlar, idiyopatik tetikler, Hymenoptera zehri ve gıdalar anafilaksin en sık görülen nedenleridir. Açık bir etiyojisi olmadan tekrarlayan bir anafilaksi öyküsü ve artmış IgE düzeyleri olan hastalarda hidatid kist rüptürü özellikle hastalığın endemik olduğu bölgelerde akla gelmelidir.

Anahtar kelimeler: Anafilaksi, IgE, hidatid kist

Geliş Tarihi: 06/01/2016 • **Kabul Tarihi:** 11/05/2016

INTRODUCTION

Anaphylaxis is an acute onset systemic hypersensitivity reaction that results from IgE-mediated mast cell and basophil activation and the subsequent release of inflammatory mediators. In a retrospective study, while the incidence of anaphylaxis was 21/100,000 in the 1980s, this number almost doubled and reached 49.8/100,000 in the 1990s. The highest incidence (70/100,000) was observed between 0 and 19 years of age. Under the age of 15, anaphylaxis is more common in males, while over the age of 15 it is more common in females (1). Drugs (58.8%) are the most commonly implicated etiologic agents in adult patients, although there are variations depending

on environmental factors and age. Hymenoptera venom (15.2%), food (6.7%), and anaphylaxis of unknown etiology (idiopathic) (19.3%) are other common factors (2).

IgE is produced by B lymphocytes and plasma cells like other immunoglobulins, but the serum level is very low due to the high affinity of Fc receptors for IgE on mast cells. Allergic diseases (e.g., atopic dermatitis, allergic rhinitis, and asthma), drugs, parasitic infections, immunodeficiencies (e.g., Jobs syndrome and Wiscott-Aldrich syndrome), autoinflammatory diseases (e.g., polyarteritis nodosa and Kawasaki syndrome), and other infections (e.g., leprosy, bronchopulmonary aspergillosis, and aspergilloma) can induce elevated IgE levels (3).

Address for Correspondence/Yazışma Adresi

Cem Onur Kirac

Necmettin Erbakan Üniversitesi, Meram Tıp Fakültesi, İç Hastalıkları Anabilim Dalı, Konya, Türkiye

e-mail: cokirac@gmail.com

Here, we present a case of recurrent idiopathic anaphylaxis with elevated IgE levels and the definitive diagnosis of the patient.

CASE DESCRIPTION

A 28-year-old male was referred to the Allergy and Immunology outpatient clinic at the Meram Faculty of Medicine (Konya, Turkey) for etiologic investigation due to recurrent anaphylaxis episodes (three times in 5 years) and elevated serum IgE levels, with the last episode occurring 5 months prior to referral to the clinic. The patient reported widespread itching, rash, nausea, vomiting, and syncope, which required transfer to the emergency department via ambulance and hospitalization following all episodes. According to the epicrisis of the last episode, during admission the patient was unconscious, had a blood pressure of 70/30 mmHg, and was diagnosed and treated as having anaphylaxis by the emergency department doctor. The patient was monitored in the intensive care unit for 24 h. Cardiac arrest did not occur during any of the anaphylactic reactions.

Two episodes of anaphylaxis developed while the patient was asleep during the second half of the night, and the last one occurred while waiting at the bus stop. The etiology could not be identified in any of the anaphylactic reactions. In addition, the patient's serum IgE level was 3.000 IU/ml 2 weeks ago at a state hospital.

ETIOLOGICAL INVESTIGATION

The patient was working in a state hospital as a member of the data computing staff. The patient had no history of systemic disease and was not using alcohol, cigarettes, or any other drugs (including opiates) regularly or occasionally.

There were no pets in the patient's house, and the patient was unable to define any triggering factors that occurred before the attacks.

The patient was symptom free during admission to our outpatient clinic.

A physical examination revealed an approximately 5 cm palpable spleen below the ribs, and dullness was observed in Traube's space. There were no other pathological findings. All laboratory tests performed to identify the etiology of the anaphylactic reaction were normal except

for an elevated IgE level (20.700 IU/ml). The patient was further evaluated in order to determine the reasons for the elevated IgE level; his medical history was not suggestive of an immunodeficiency, and anti-HIV, CMV IgM, and EBV IgM tests were negative. The patient's eosinophil count was normal, and skin prick tests with inhalant and food allergens were negative. No parasites or ova were observed in a stool examination, and paranasal CT was not compatible with fungal sinusitis. The patient's medical history and physical examination did not indicate the presence of autoinflammatory diseases.

Using abdominal ultrasonography, the long axis of the spleen was approximately 13 cm, and the position and contour of the spleen were normal. However, in the parenchyma of the spleen, there was 7x8 cm lesion that was compatible with a hydatid cyst. An indirect hemagglutination test for hydatid cysts was positive (in 1/2.560 titers, the lowest titer that can be measured). Thorax and abdominal CT examinations were performed in order to investigate other potentially affected tissues. An abdominal CT showed an 84x83 mm calcified cystic lesion in the splenic parenchyma (Figure 1). However, no other lesions were observed outside of the spleen. The etiology of anaphylaxis was attributed to the hydatid cyst and a splenectomy was planned following consultations with general surgery and interventional radiology staff.

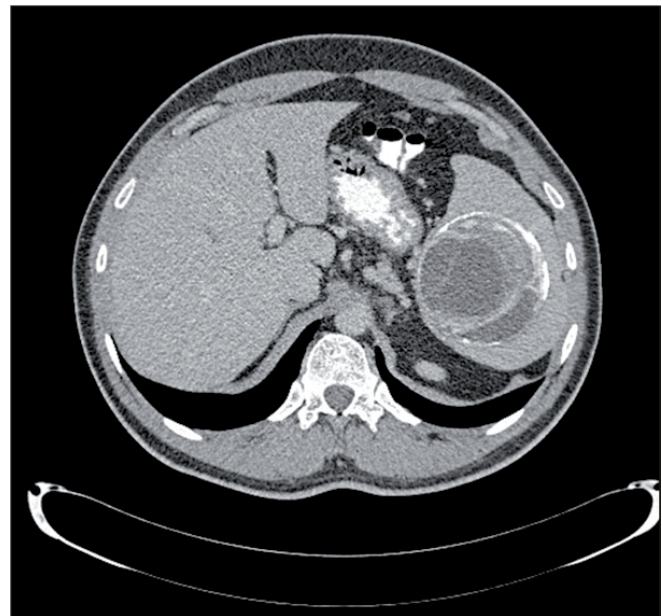


Figure 1. Calcified cystic lesion (84x83 mm) in the splenic parenchyma in abdominal CT.

OPERATION

Laparotomy was selected as the surgical technique to perform a total splenectomy due to the patient's history of recurrent anaphylaxis, difficult location and extension of the hydatid cyst (posteromedial part, covering 60% of the spleen), and the active infection risk of the cyst. Prophylactic methylprednisolone (80 mg, IV; 1 mg/kg) and antihistamines were administered to the patient before the operation. During the operation, a scolocidal injection was not administered due to the risk of cyst material leaking into the peritoneal cavity. The anesthesia team was advised to closely monitor the patient's vital signs during removal of the spleen from the abdominal cavity. There were no complications during or after the operation. Albendazole treatment was started after surgery, and on day 4 post-surgery, the patient's serum level of IgE had decreased (11.100 IU/ml). After 3 months of surgery, the IgE level decreased to 1.050 IU/ml.

GROSS PATHOLOGY and HISTOPATHOLOGY

The dimensions of the spleen were 18x11x9 cm. The integrity of the splenic capsule was disrupted, and there was an off-white/yellow-colored cystic lesion that measured 7x6x6 cm (Figure 2). By microscopy, a calcified cystic lesion with a germinal membrane and cuticle was observed in the splenic parenchyma, and numerous scolexes were present in the cyst.

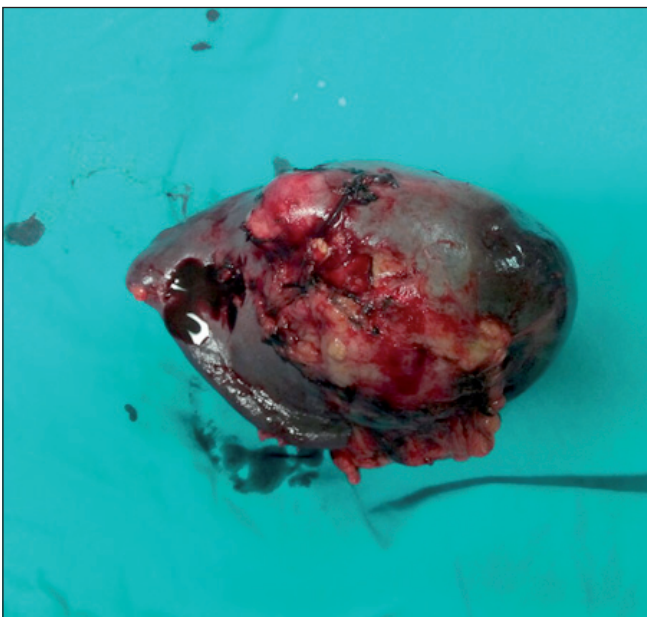

Figure 2. Off-white/yellow-colored cystic lesion in the spleen.

DISCUSSION

Hydatid disease is a parasitic infection caused by *Echinococcus granulosus* that primarily involves the liver (50-77%) and lungs (18-35%), but is rarely observed in other organs, including the spleen (0.5-6%). Splenic involvement is rare due to the life cycle of the parasite. Orally ingested parasite eggs reach the portal system through the intestinal wall. Most of the eggs settle in the liver (50-70%), while others travel to the lungs through the liver sinusoids (20-30%). If the eggs do not settle in these two organs and proceed to the systemic circulation, spleen involvement may occur. In patients with portal hypertension, retrograde transportation to the spleen may occur through the hepatic portal system. Rarely, the spleen may become affected following the rupture of hydatid cysts in the liver (4,5).

Livestock are the most important risk factor for *E. granulosus* infection (6). However, contact with animals is not necessary for transmission. Ingestion of water and/or food contaminated with feces infected with *E. granulosus* larvae and contamination with infected soil are other ways to contract the illness. In the current patient, there was no history of animal contamination.

A hydatid cyst is usually asymptomatic, and is often diagnosed during imaging performed for other reasons. Symptoms may occur due to compression of an adjacent organ or complications (7). Possible complications include a secondary infection of the cyst, intraperitoneal rupture (especially subcapsular cysts), and anaphylactic shock (8,9). As was the case in this particular patient, anaphylaxis may be the only symptom of hydatid cysts (10).

The most common causes of anaphylaxis are drugs in adults and foods in children. Furthermore, many other etiologic factors of anaphylaxis, including hydatid cysts, have been reported. A hydatid cyst can rupture due to trauma or it can occur spontaneously. However, anaphylaxis has been reported due to unruptured hydatid cysts. In the autopsies of two severe anaphylactic reactions, unruptured cysts and cyst contents were detected in the systemic circulation (11,12). In a previous case report, a liver hydatid cyst induced recurrent attacks of anaphylaxis, and these attacks continued due to inadequate treatment of the cyst (13).

The relationship between IgE levels and a hydatid cyst is thought to be more pronounced in patients that exhibit

complications of anaphylaxis (14). Guisantes et al. (15) reported that the IgE levels decreased following surgery in patients with a hydatid cyst. In the current report, the IgE level decreased from 20.700 to 11.100 IU/ml after surgery. Anaphylaxis is a life-threatening condition, so investigating the etiology and obtaining appropriate treatment is crucial. Hydatid cysts should be kept in mind when determining the etiology of anaphylaxis, especially in endemic areas.

REFERENCES

1. Simons FE. Anaphylaxis: Recent advances in assessment and treatment. *J Allergy Clin Immunol* 2009; 124:625-6.
2. Jerschow E, Lin RY, Scaperotti MM, McGinn AP. Fatal anaphylaxis in the United States, 1999-2010: Temporal patterns and demographic associations. *J Allergy Clin Immunol* 2014;134:1318-28.
3. Winter WE, Hardt NS, Fuhrman S. Immunoglobulin E: importance in parasitic infections and hypersensitivity responses. *Arch Pathol Lab Med* 2000;124:1382-5.
4. Akbulut S, Senol A, Ekin A, Bakir S, Bayan K, Dursun M. Primary retroperitoneal hydatid cyst: Report of 2 cases and review of 41 published cases. *Int Surg* 2010;95:189-96.
5. Fernandez-Ruiz M, Guerra-Vales JM, Enguita-Valls AB, Vila-Santos J, Garcia-Borda FJ, Morales-Gutierrez C. Splenic hydatid cyst, a rare location of extrahepatic echinococcosis: Report of six cases. *Eur J Intern Med* 2008;19:51-3.
6. Wang Z, Wang X, Liu X. Echinococcosis in China, a review of the epidemiology of *Echinococcus* spp. *Ecohealth* 2008;5: 115-26.
7. Sachar S, Goyal S, Sangwan S. Uncommon locations and presentations of hydatid cyst. *Ann Med Health Sci Res* 2014;4:447-52.
8. Fanne RA, Khamaisi M, Mevorach D, Leitersdorf E, Berkman N, Laxer U, Maly B. Spontaneous rupture of lung echinococcal cyst causing anaphylactic shock and respiratory distress syndrome. *Thorax* 2006;61:550.
9. Tinsley B, Abbara A, Kadaba R, Sheth H, Sandhu G. Spontaneous intraperitoneal rupture of a hepatic hydatid cyst with subsequent anaphylaxis: A case report. *Case Reports Hepatol* 2013;2013:320418.
10. De Wispelaere L, Vande Velde S, Schelstraete P, Van Renterghem K, Moerman F, Van Biervliet S, Van Winckel M. Anaphylactic shock as a single presentation of *Echinococcus* cyst. *Acta Gastroenterol Belg* 2011;74:462-4.
11. Buyuk Y, Turan AA, Uzun I, Aybar Y, Cin O, Kurnaz G. Non-ruptured hydatid cyst can lead to death by spread of cyst content into bloodstream: An autopsy case. *Eur J Gastroenterol Hepatol* 2005;17:671-3.
12. Hosseini M, Hedjazi A, Bahrami R. Sudden death due to anaphylactic shock in a patient with an intact hepatic hydatid cyst. *Am J Forensic Med Pathol* 2014;35:256-7.
13. Gelincik A, Ozseker F, Buyukozturk S, Colakoglu B, Dal M, Alper A. Recurrent anaphylaxis due to non-ruptured hepatic hydatid cysts. *Int Arch Allergy Immunol* 2007;143:296-8.
14. Li Y, Zheng H, Gu M, Cao X, Wen H, Liu Z, Liu T. Comparisons of serum total IgE, IgG, and IgG1 levels in patients with and without echinococcosis-induced anaphylactic shock. *Am J Trop Med Hyg* 2012;87:104-8.
15. Guisantes JA, Vincente-Garcia F, Abril MJ, Eraso E, Martinez J. Total and specific IgE levels in human hydatid disease determined by enzyme immunoassay: Serological follow-up after surgery. *J Investig Allergol Clin Immunol* 1994;4:301-4.