

Comparison of costal cartilage and Dacron® graft in laryngotracheal reconstruction: an experimental study

Larengotrakeal rekonstrüksiyonda kosta kırıkdağıyla Dacron® greftin karşılaştırması: Deneysel çalışma

Yusuf Baran¹, Kayhan Öztürk², Mustafa Çalık³, Aydan Canbilen⁴, Hıdır Esme³

¹Department of Otorhinolaryngology, Konya Training and Research Hospital, Konya, Turkey

²Department of Otorhinolaryngology, Selçuklu Medical Faculty, Selçuk University, Konya, Turkey

³Department of Thoracic Surgery, Konya Training and Research Hospital, Konya, Turkey

⁴Department of Histology and Embryology, Meram Medical Faculty, Necmettin Erbakan University, Konya, Turkey

Abstract

Objective: To evaluate the use of the Dacron® implant in laryngeal reconstruction and to discuss potential indications of this material in head and neck surgeries.

Methods: Three groups consisting of 12 Wistar albino rats in each were formed, Group 1 was the control group and anterior laryngotracheal reconstruction was performed by transplanting autologous costal cartilage sized 5x5x5 mm obtained by 6 mm longitudinal sectioning extending from cricoid cartilage to the 5th tracheal ring. Group 2: Trachea sectioning was performed in equal lengths as in Group 1, and anterior laryngotracheal reconstruction was carried out by transplanting the same sized homologous cartilage. Group 3: Trachea sectioning was performed in equal lengths as in Group 1 and anterior laryngotracheal reconstruction was carried out by Dacron® graft in the same size. The rats were sacrificed in the 12th week of the implantation, and the groups were compared in terms of their tracheal section area, partial oxygen pressure, epithelialization, neovascularization, inflammatory cell infiltration and new chondrocyte development.

Results: One experimental animal in Group 1 was lost due to pneumothorax on the second day postoperatively. In Group 3, one animal died because of development of granulation and crusting on the 8th day postoperatively. There was no statistically significant difference between the groups in terms of tracheal cross sectional area, and partial oxygen pressure. While there was no significant difference in terms of epithelial development and neovascularization between Groups 2 and 3, while Group 1 was significantly better than Groups 2 and 3. Lymphocytic infiltration is an essential parameter in graft rejection and there was a significant difference between the groups. Group 1 was better than the other two groups but it was determined that Group 3 was considerably different from Group 2. There was a significant difference between Groups 1 and 2 in terms of new chondrocyte development.

Conclusion: Autogenous costal cartilage is an ideal graft material for trachea and larynx since scores of epithelial development, neovascularization and chondrocyte development are better. Dacron® implant can be used safely in laryngeal reconstruction as stenosis, infection and rejection did not occur in Group 3 exposed to Dacron®, and epithelial development and neovascularization occurred satisfactorily in all experimental animals.

Key words: Laryngotracheal reconstruction, Dacron®, anterior laryngotracheal splint.

Özet

Amaç: Larenks rekonstrüksiyonunda Dacron® implant kullanımını değerlendirmek ve bu materyalin baş-boyun cerrahilerinde potansiyel endikasyonlarını tartışmak.

Yöntem: Her biri 12 Wistar albino sıçandan ibaret üç grup oluşturuldu. Grup 1 kontrol grubu olup bu gruptaki sıçanlarda krikoit kırıkdan 5. trakea halkasına kadar 6 mm uzunluğunda kesi yapılarak elde edilen 5x5x5 mm'lik otolog kosta kırıkdağı transplantasyonu yoluyla anterior larengotrakeal rekonstrüksiyon gerçekleştirildi. Grup 2'de, Grup 1'de olduğu gibi trakea eşit uzunluklarda bölümlere ayrıldı ve aynı büyüklükte homolog kırıkdağı nakliyle anterior larengotrakeal rekonstrüksiyon gerçekleştirildi. Grup 3'de trakea, Grup 1'e eşit bölümlere ayrıldı ve aynı büyüklükte bir Dacron® greftiyle rekonstrüksiyon yapıldı. İmplantasyondan sonraki 12. haftada sıçanlar sakrifiye edildi ve hasta gruplar trakea kesit alanı, parsiyel oksijen basıncı, epitelizasyon, neovaskülarizasyon, enflamatuvar hücre infiltrasyonu ve yeni kondrosit oluşumu açısından karşılaştırıldı.

Bulgular: Grup 1'de postoperatif 2. günde pnömotoraks ve Grup 3'de ise 8. günde granülasyon ve krutlanma nedeniyle birer deney hayvanı kaybedildi. Trakea enine kesit alanı ve parsiyel oksijen basıncı açısından gruplar arasında herhangi bir istatistiksel farklılık yoktu. Grup 2 ve Grup 3 arasında epitel gelişimi ve neovaskülarizasyon açısından istatistiksel bir farklılık yoktu ancak Grup 1, diğer iki gruptan anlamlı derecede daha iyi idi. Greft reddinde lenfosit infiltrasyonu önemli bir parametre olup gruplar arasında önemli bir farklılık vardı. Grup 1, diğer 2 gruptan daha iyi olduğu gibi Grup 3'ün, Grup 2'den hatırı sayılır derecede farklı olduğu belirlendi. Yeni kondrosit gelişimi açısından Grup 1. ile Grup 2 arasında anlamlı bir farklılık vardı.

Sonuç: Epitel, neovaskülarizasyon ve kondrosit gelişim skorları daha iyi olduğu için otojen kosta kırıkdağı trakea ve larenks için ideal greft materyalidir. Dacron®'un kullanıldığı grupta stenoz, enfeksiyon ve rejeksiyon olmadığı, tüm deney hayvanlarında epitel gelişimi ve neovaskülarizasyon tatminkâr derecede olduğu için larenks rekonstrüksiyonunda Dacron® implantları güvenle kullanılabilir.

Anahtar sözcükler: Larengotrakeal rekonstrüksiyon, Dacron®, anterior larengotrakeal splint.

Correspondence: Yusuf Baran, MD. Department of Otorhinolaryngology, Konya Training and Research Hospital, Necip Fazıl Mah. Ateşbazı Sok. Meram Yeniyol, 42090, Konya, Turkey.
e-mail: dryusufbaran@gmail.com

Received: April 5, 2013; **Accepted:** June 13, 2013; **Published online:** January 25, 2014

Online available at:
www.jmedupdates.org
doi:10.2399/jmu.2013003001
QR code:



Laryngeal and tracheal reconstructions in head and neck surgeries are sometimes challenging to surgeons and often require complex solutions to restore the functions. A variety of procedures have been employed to correct this condition. One successful method is laryngotracheal reconstruction with interpositional autologous tissues. The ideal grafting material for airway reconstruction should conform to the shape of the airway lumen and maintain structural support of the airway.^[1,2] The graft should have enough structural rigidity to prevent collapse of the lumen, should be resistant to infection and resorption, and should be rapidly epithelialized.

Cartilage has become the predominant material used for lumen augmentation. Reconstruction utilizing autografts may be ideal but there are some disadvantages of autografts, such as donor site morbidity, resorption, prolonged operating time, and replacement by fibrous tissue scar. The use of homologous cartilage may reduce the morbidity associated with harvesting cartilage from a separate surgical site of the patient. Several studies have examined the use of alcohol-preserved homologous cartilage as a graft material.^[1,2] But homologous cartilage has its own risks including transmission of infectious agents and increased antigenic responses resulting in decreased survival of the graft.

Various alloplasts have been investigated. Alloplasts have the following advantages: unlimited availability, lack of donor site morbidity, ease of contouring, preservation of shape and volume over time, and relative simplicity of their implantation.^[3] Many procedures have been described for laryngotracheal reconstruction using ceramic rings, hydroxylapatite, polyethylene, teflon, titanium minipilates, lactosorb, Medpor, and Dacron®.^[4] However these materials are foreign bodies and most alloplasts tolerate infection and exposure poorly. Porous high-density polyethylene terephthalate (Dacron® graft) is well tolerated by surrounding tissue, its porous structure is rapidly infiltrated by host tissues and it resists infection. Since it is a highly stable and flexible material, it can be successfully used in laryngeal reconstruction. The objective of the present study is to examine the survival and histologic changes involved with graft healing of autograft costal cartilage, alcohol-preserved homograft costal cartilage and Dacron® graft transplanted to a rat trachea.

Materials and Methods

Thirty-six male Wistar albino rats weighing between 250 and 300 g with patent airways were used in the study. The experimental protocol was conducted in accordance with the guidelines published in the Guide for the Care and Use of Laboratory Animals (DHEW publication NIH 85-23,

revised 1996, Office of Science and Health Reports, DRR/NIH, Bethesda, MD, USA) and approved by the Committee on Animal Research of the Meram School of Medicine, Selçuk University, Konya, Turkey. The study was done at the Experimental Animal Studies Laboratory of Meram School of Medicine at Selçuk University. The rats were kept in different cages under standard light and temperature conditions. The rats were randomly separated into three groups consisting of twelve rats in each group (Group 1: autograft costal cartilage group; Group 2: homograft costal cartilage; Group 3: Dacron®). Dacron® graft of 0.5×0.5 mm for Group 3, and costal cartilage grafts with the same size for Groups 1 and 2 were prepared. The homografts employed in Group 2 were obtained from the rats in Group 1 that were sacrificed on the 90th day.

Surgical Procedure

Before each surgical procedure the rats were treated with 50 mg/kg cefazolin IM, and anesthetized with 30 mg/kg ketamine IM, and 5 mg/kg xylocaine IM without intubation. The anterior chest and neck of each rat in Group 1 were shaved and washed with povidone-iodine solution. The site overlying the first “floating rib” was infiltrated with a mixture of 1% lidocaine and 1:100,000 epinephrine. A horizontal incision was made and dissection through the intercostal muscles was performed to expose the costochondral graft site. The costochondral graft was harvested with sharp dissection, and care was taken not to disturb the pleura to prevent pneumothorax. The graft was placed in sterile isotonic sodium chloride solution (saline), hemostasis was ensured, and the wound was closed in layers using absorbable sutures. A drain was not used.

A vertical midline cervical incision was then made over the larynx after infiltrating the incision site with 1% lidocaine and 1:100,000 epinephrine. The strap muscles were divided along the median raphe to allow exposure of the larynx, cricoid, and superior trachea. A midline incision was then made through the inferior half of the thyroid cartilage and extended through the cricoid cartilage and the first 5 tracheal rings. The costochondral graft was shaped in an elliptical fashion to allow placement and expansion of the laryngeal, cricoid, and tracheal incisions. The perichondrium was left intact along the graft surface which faced the airway lumen. Costochondral graft sized 0.5×0.5 mm was then attached with 8-10 sutures of 10/0 monofilament nonabsorbable filaments (Prolene™; Ethicon Endo-Surgery, Inc., Cincinnati, OH, USA) using a microsurgery set with the aid of a surgery microscope (Carl Zeiss OPMI 9HC; Carl Zeiss GmbH, Jena, Germany). Strap muscles were closed with 4/0 chromic catgut sutures

reinforcing the graft. The skin incision was closed with 4/0 prolene sutures.

All animals recovered from anesthesia and were looked after in the 'Experimental Animal Studies Laboratory' of Meram School of Medicine at Selçuk University and all survived into the postoperative period.

Homografts were produced by keeping the costal cartilages obtained from the rats in Groups 1 and 2 that were sacrificed on the 90th day in 70% alcohol for two weeks. They were also used in the laryngotracheal reconstruction (LTR) of the rats in Group 2 prepared for the operation using the same procedure. Dacron® grafts were prepared as 0.5x0.5 mm patches and used in the LTR of the rats in Group 3. On the postoperative 90th day, 2 cc intracardiac blood was drawn from all rats under ketamine HCL anaesthesia and blood gas status was analyzed. Animals were sacrificed to evaluate the graft stability, and collapse, in addition histologic examination was performed using a light microscope (BH2 Olympus Photomicroscope; Olympus Corporation, Tokyo, Japan). Duration of the surgery was recorded for three groups.

Macroscopic Examination

After sacrifice of animals, laryngotrachea of each rat was dissected and examined macroscopically to note antero-posterior diameter, lateral diameter, granulation (0 none, 1 mild, 2 moderate, 3 severe), inflammation (0 none, 1 mild, 2 moderate, 3 severe) and luminal obstruction (3 patent; 2 moderately obstructed, 1 obstructed).

Light Microscopic Examination

For each rat the trachea was dissected from larynx to carina and kept in formaldehyde solution. The specimens were embedded in paraffin, and 5 µm sections were placed on glass slides. Each slide was stained with hematoxylin-eosin (H&E) and Masson trichrome and examined by light microscopy. The same specialist, blinded to the group, examined all the sections

Six parameters were investigated in the histopathologic examination. These were epithelialization, neovascularization, chondrocyte development and macrophage, lymphocytic, and neutrophilic infiltrations. In the histopathologic examination, morphologic changes were classified on a scale from 0 to 5 as negative (0), mild (1), mild to moderate (2), moderate (3), moderate to severe (4), and severe (5).

Statistical Analysis

The statistical analysis data were entered into a computer and evaluated with SPSS for Windows (SPSS Inc., Chicago,

IL, USA) 10.0 package program. The data were expressed as mean±standard deviation. The groups were compared with one-way analysis of variance (ANOVA). Tukey HSD was used as post hoc test. Student-t test was used since chondrocyte assesment was done in both groups. When the groups were compared in terms of pre- and postoperative tracheal cross-sectional site (TCS), two-way analysis of variance was used. When results of the analysis of variance were statistically significant, ANOVA, Tukey's HSD tests were used, and Student-t test was employed when pre- and post-operative values were compared in the dependent groups. A p value <0.005 was considered as statistically significant.

Results

A test subject in Group 1 died of pneumothorax on the postoperative 2nd day and another test subject in Group 3 was lost because of granulation on the postoperative 8th day. No complication like bleeding, infection, subcutaneous emphysema and immediate dyspnea was noted after surgical procedures. The skin sutures were removed 7 days after the operation. Mean operative times were 83.3±10.5 mins (Group 1), 43.3±6.15 mins (Group 2), and 36.2±6.4 mins, respectively (Group 3) (Fig. 1). Tracheal stenosis was not detected in any rat. Complication developed in one test subject in Groups 1 and 3.

Tracheal Cross-sectional Site

The mean values were determined as 1; 5.1±0.6, 5.3±0.5 and 5.5±0.5 in Groups 1, 2, and 3, respectively. There was no statistically significant difference between Groups 1 and 2

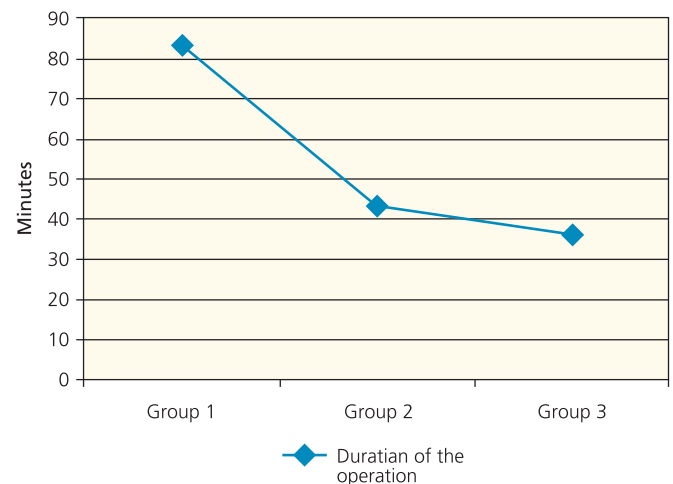


Fig. 1. Comparison of the operative times.

($p=0.801$), Groups 1 and 3 ($p=0.285$), and Groups 2 and 3 ($p=0.620$), respectively in terms of TCS values.

Partial Oxygen Pressure

It was established that there was a similar distribution of partial oxygen pressure ($\text{PaO}_2=\text{mmHg}$) values between groups. The mean values were 89.9 ± 4.2 in Group 1, 91.8 ± 2.6 in Group 2, and 93.4 ± 2.9 in Group 3 without any statistically significant difference between groups ($p>0.05$).

Epithelialization

When the epithelializations of the groups were evaluated, the mean values were 4.5 ± 0.5 in Group 1, 3.4 ± 0.7 in Group 2, and 3.5 ± 0.7 in Group 3. There was a statistically significant difference ($p=0.01$) between Groups 1 and 2, and Groups 1 and 3 ($p=0.02$) without any statistically significant difference between Groups 2 and 3 ($p=0.989$) (Fig. 2).

Neovascularization

When the groups were compared with each other for the development of neovascularization, the mean values were 4.3 ± 0.6 in Group 1, 2.5 ± 0.5 in Group 2, and 3 ± 0.8 in Group 3. While there was no statistically significant difference between Groups 2 and 3 ($p=0.174$), a statistically significant difference existed between Groups 1, and 2 ($p=0.000$), and Group 1 and 3 ($p=0.000$) (Fig. 2).

Neutrophils ($10^6/\text{ml}$)

The mean cell counts of these inflammatory cells were 1.6 ± 0.7 (Group 1), 2.9 ± 0.7 (Group 2), and 2.6 ± 1.0 (Group 3). While there was not a statistically significant difference between Groups 2 and 3 ($p=0.351$), a statistically significant difference was found between Groups 1 and 2 ($p=0.001$), and Groups 1 and 3 ($p=0.000$) (Fig. 3).

Macrophages ($10^6/\text{ml}$)

The mean cell counts of these inflammatory cells were 1.2 ± 0.4 (Group 1), 3 ± 0.7 (Group 2), and 2.4 ± 1.1 (Group 3). While a statistically significant difference was not noted between Groups 2 and 3 ($p=0.946$), a statistically significant difference was detected between Groups 1 and 2 ($p=0.000$), and also Groups 1 and 3 ($p=0.000$) (Fig. 3).

Lymphocytes ($10^6/\text{ml}$)

The mean filtration values of lymphocytes, which are considered as an important parameter especially for graft rejection were 1.4 ± 0.7 in Group 1, 4 ± 0.7 in Group 2, and 2.5 ± 0.7 in Group 3. Accordingly, there was a statistically significant difference between Groups 1 and 2 ($p=0.000$),

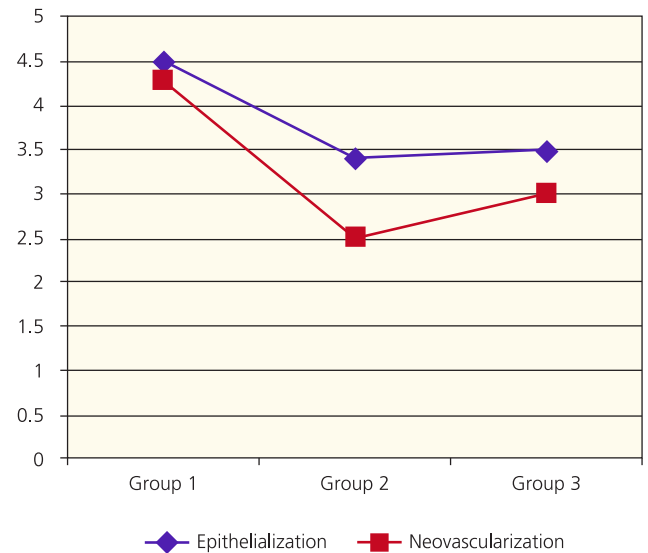


Fig. 2. Assessment of epithelialization and neovascularization in all groups.

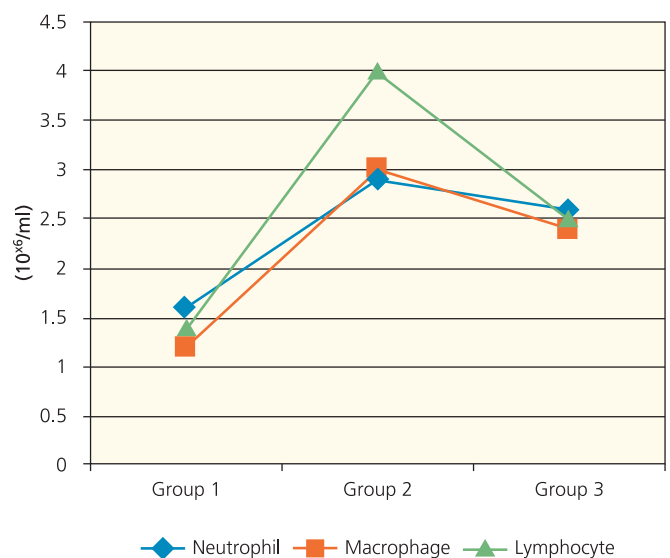


Fig.3. Comparative neutrophil, macrophage, and lymphocyte counts in all groups.

Groups 1 and 3 ($p=0.001$), and Groups 2 and 3 ($p=0.000$) (Fig. 3).

Chondrocytes ($10^6/\text{ml}$)

The mean values of the new chondrocyte development were 4.3 ± 0.6 in Group 1, and 2.5 ± 0.8 in Group 2. Accordingly, there was a statistically significant difference between Groups 1 and 2 ($p=0.000$) (Figs. 4, 5 and 6).

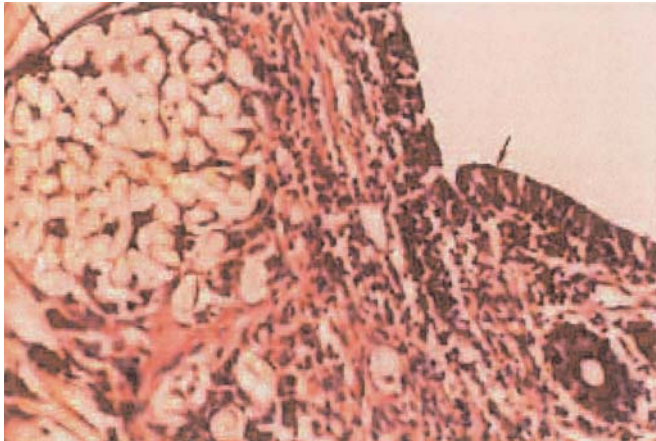


Fig. 4. Epithelialization and intense cell infiltration (arrows) in an animal (#3) who underwent Dacron® grafting (Photomicroscopic magnification 3.3×10 HE staining).

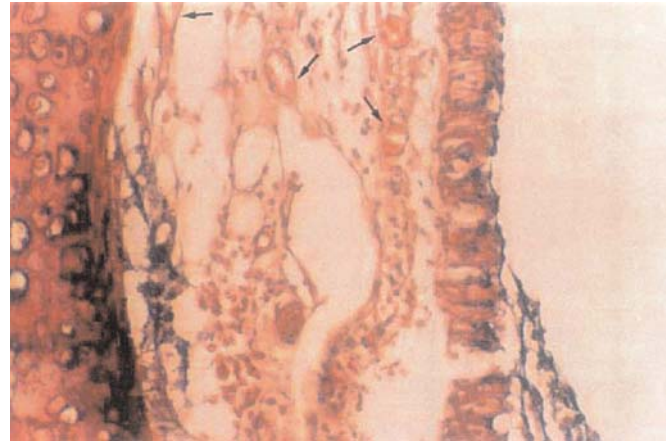


Fig. 5. Neovascularization of pseudostratified epithelium and the development of a new chondrocyte (arrows) in an animal (#9) which underwent autograft implantation (Photomicroscopic magnification 3.3×10 HE staining).

Discussion

Currently, three types of therapeutic procedures exist for subglottic stenosis: laryngotracheal resection and anastomosis, laryngoplasty without segmental resection and with or without bone or cartilage grafting, and an endoscopic procedure that includes dilatation and laser incision.^[5] One of the techniques advised for tracheal reconstruction is resection and primary anastomosis.^[6] Primary anastomosis may not be possible in some patients with relatively non-elastic tissues especially as in the case of elders, in cases with fibrosis development caused by the previous surgical procedures, and long segment tracheal stenosis affected by traumatic, oncologic or congenital pathologies.^[7]

It has been reported in the literature that the best results of grafting have been achieved by using autografts.^[8] Septal cartilage and auricular cartilage are reabsorbed sooner and there is a risk of collapse in lumen as they can not provide enough reinforcing tissues.^[9] Costal cartilage is the most popular autograft material as it is reabsorbed less and has an adequate support. However, it has serious complications such as postoperative pain, pneumothorax, hemothorax and dyspnea.^[10]

Employing rigid grafts in laryngotracheal reconstruction is extremely useful. Reconstruction with auto/homografts or prosthesis is an alternative method mostly discussed nowadays. Reconstruction utilizing autografts may be ideal but there are some disadvantages of automaterials, such as donor site morbidity, reabsorption, prolonged operating time, and replacement by fibrous tissue scar. However, in addition to them, rejection, degeneration and restenosis

have prevalent serious troubles encountered in homo/heterografts.^[11]

Some authors have successfully used autologous composite nasal septal grafts, muscle-pedicle hyoid bone flaps in subglottic and tracheal reconstruction, but we believe that some alloplastic materials should be introduced to the field of laryngology in order to overcome disadvantages of autologous grafts like resorption, risk of infection or necrosis.^[12,13] Various articles have specified the benefits of various implants, but each material has some disadvantages like rejection and extrusion.^[14] The ideal implant to be used in upper airway reconstruction should allow epithelialization, resist infection, cause minimal scarring, be rigid and also

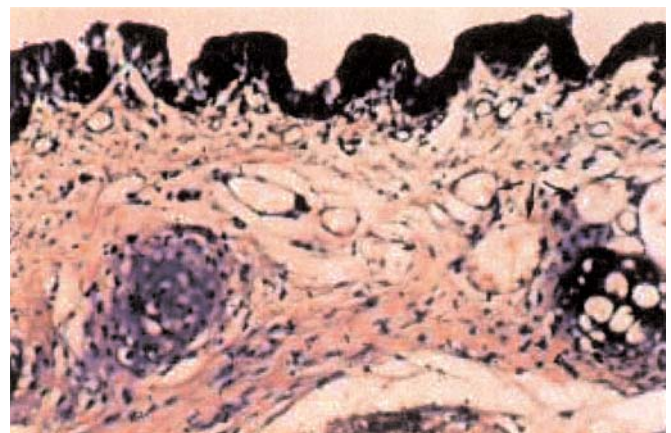


Fig. 6. Epithelialization, development of new chondrocytes and intense cell infiltration in an animal (#8) which underwent homograft implantation (Photomicroscopic magnification 3.3×20 HE staining).

flexible, and allow for single stage repair without stenting. To achieve these purposes, Klein et al. used polyglycolic acid/poly-L-lactic acid copolymer in laryngotracheal reconstruction of rats and noted that the material was safe while maintaining adequate strength and patency.^[15] Mitskavich et al. used microplates in porcine model with subglottic stenosis.^[16] They produced subglottic stenosis and reconstructed the stenotic region with anterior cricoid split and microplate distraction and stabilization. They suggested that this rigid fixation was a viable alternative to traditional methods without stenting or risks of a donor site. Hashem et al. used med-pore implant in laryngotracheoplasty in an animal model and achieved successful results in tracheal reconstruction.^[17]

In the present study we have chosen Dacron® as our graft material because of its good tissue compatibility and widespread clinical use. Dacron® is made of pure medical-grade high-density polyethylene terephthalate with small pores interconnecting in a porous architecture. It is a highly inert synthetic material that allows vascular ingrowth and is biocompatible and stable over many years of use. The porous property of the Dacron® implant allows vascular ingrowth in the implant within 3 to 4 weeks, which provides a stable interface with the surrounding bed and decreases potential susceptibility to infection. Our goal was to address these issues with a material we believe could be as effective as other traditional materials in laryngeal reconstruction.

While there was no statistical significant difference in the partial oxygen pressure between three groups, it was lower in Group 1. Costal cartilage resection in Group 1 may have affected the partial oxygen pressure. Stridor occurred only in one experimental animal on the postoperative 2nd day which did not survive. It was determined in the autopsy that the edges of the ribs perforated pleura in the donor site leading to pneumothorax. We have demonstrated complete epithelialization in the test subjects of all three groups.

Epithelialization and neovascularization were better in Group 1 when compared with the other groups. In Group 1, macrophage, neutrophil and lymphocyte infiltration as a whole were not intense as seen in other groups. Trachea epithelium is the sole factor responsible for this phenomenon. Dysepithelialization of the trachea to be transplanted or immunosuppressive therapy has been advised to prevent rejection occurred as a result of HLA Class II antigen incompatibility.

Although fibroblast migration establishes the required ground for the epithelial growth, fibrovascular proliferation and development of inflammatory submucosal and excessive paratracheal granulation will lead to stenosis if the epithelial

growth is not satisfactory.^[18] Jacobs and Pordebarac reported that epithelialization of an autogen graft is fully achieved within 3 weeks.^[19]

The surface of the graft facing the lumen epithelialized rapidly. This epithelial layer protects the cartilage graft from the infections that may come through the airway. The epithelial layer in Groups 2 and 3, where Dacron® and homografts were used, consisted mostly of globoid cells. Autograft looked like rather a mature respiratory epithelium. We did not use stent in this experimental study and in all groups, uninterrupted epithelialization occurred on the free graft surfaces. Wiatrak et al. reported that stent delayed epithelialization.^[20]

Costal cartilage graft exposed to radiation and homograft auricular cartilage kept in alcohol for laryngotracheal reconstruction were studied in order to reduce the morbidity of the costal cartilage in the donor site. Adlington et al. investigated resorption and fibrosis values in rats during the follow-up of the homolog cartilages prepared using different methods and implanted these homolog costal cartilages (treated preoperatively with formalin, glutaraldehyde and alcohol) subcutaneously.^[21] They did not find any difference in the degree of resorption and fibrosis between the homolog cartilages prepared using different methods. Since cosmetic outcomes of the autolog and homolog cartilages were similar, they stated that homolog cartilages could be preferred.

Keskin et al. compared autolog, and homolog auricular cartilages they prepared keeping them in alcohol in the LTR of the rats.^[22] They established that autografts were superior in that they contained considerably higher percentage of viable cells (95%/30%) with less resorption, fibrosis and necrosis. All autografts, but only 65% of the homografts were epithelized. Both grafts were found inadequate to produce new cartilages.

Dacron® is a synthetic microporous material which has been used in cardiovascular surgery for many years. Since it has a loose textured structure, the reactive tissues around it penetrate into the implant easily, so it is fixated more firmly.^[23] Moreover, micropores on Dacron® can accelerate the migration of epithelial cells. Thus, rapid epithelialization can be thought to occur because it does not cause granulation and stenosis.

Various reinforcing materials (spiral or circular polypropylene or steel rings) were used in order to prevent, and overcome tracheal collapse leading to death with fulminant respiratory failure. Thanks to these improved properties it was observed that Dacron® grafts provided many

ideal prosthetic conditions. In the present study, we used spiral Z-stent Dacron® graft that has been improved recently for tracheal reconstruction.

As a mainspring of tracheal reconstruction failure, the deficiency in revascularization and epithelialization of the graft is considered more important in graft rejection. It can be expected that rapidly developed prosthesis may decrease prosthesis complications considerably. An increase in the diameters of the pores will be helpful for the rapid epithelialization. Kaiser^[18] reported that a 2×2 cm defect of canine cervical trachea was closed with a Dacron® patch having a porosity of 25 to 50 µm or 125 to 150 µm. He observed that the Dacron® patch with smaller pores was rejected, while the patch with larger pores was covered by connective tissues as quickly as 90 days after the operation. Shimizu et al.^[24] reported an optimal pore size of fine Marlex® mesh as approximately 300 µm, for a patch graft implanted to the cervical trachea in dogs. Nelson et al.^[25] worked on bioelectric polyurethane and reported that 60- to 120-µm pores were suitable for a mediastinal tracheal graft with an omental flap in dog models. Tsukada and Osada^[26] compared 300 µm and 25 pores/cm², 2700 µm and 25 pores/cm², 2500 µm and 100 pores/cm², and stent-reinforced prosthesis with 500 µm and 64 pores/cm² Dacron® for ideal pore and density characteristics and achieved the best results with 500 µm pore size and 64 pores/cm² dense stainless-steel spirals covered with a woven Dacron®. We used this stainless-steel spirals covered with Dacron® in our study, too. This stent did not obstruct the pores and led to rapid and relatively uniform tissue ingrowth.

Jacobs et al.^[27] found that two-stage Dacron® implant procedure as a tracheal prosthesis was well tolerated and detected normal respiratory epithelium in the prosthesis implanted in dogs. Varied results have been reported for synthetic materials in the literature. The most common complications of synthetic grafts are the obliteration with granulation tissues, graft rejection, suture deficiency, collapse and infections.^[28] We established in our study that Dacron® tracheal prosthesis was well tolerated in the anterior graft procedure and detected ingrowth of normal respiratory epithelium.

Recurrent granulation tissues, necrosis in the suture line, infection, chronic air leak, hemorrhage and repetitive stenosis did not occur. Stridor and death occurred in only one test subject. All the rest survived 90 days and their lumen widths were similar to those in Group 1. A normal-appearing epithelium grew on these prostheses which is the key to a successful reconstruction.

Rapid epithelialization can be attributed to the fact that the trachea did not undergo segmental resection and graft was applied only on the anterior wall of the trachea. We are of the opinion that this graft material is worth studying and requires new studies investigating long-term outcomes as stenosis, infection and rejection which in our study did not occur with this graft material. Although not as much as in the group where costal cartilage was employed, satisfactory (moderate) epithelialization and neovascularization developed in all test subjects and complication rates were almost identical among three groups.

While the anteroposterior diameter of the trachea decreased postoperatively in all three groups, transverse diameter of the trachea increased slightly in our study. Tracheal cross-sectional site increased considerably in all three groups postoperatively. Stenosis did not develop in any subject except one in Group 3. Autopsy of this animal revealed the formation of a granulation tissue and crust and development of respiratory failure caused by stenosis. There was no statistically significant difference between groups regarding tracheal cross-sectional site.

The airways of the rats in our study before laryngotracheal reconstruction were patent. This can be a proper model for the graft healing in cases with subglottic stenosis. In the literature, there are experimental studies on tracheal surgery in which usually rabbits, cats and dogs have been preferred. However, there are few studies on rats. This can be attributed to the fact that the diameter of rat trachea is small. Nevertheless, rat trachea is an operable material when operation microscope and microsurgery instruments are used. We believe that ethically it will be more appropriate to carry out studies with smaller animals.

Conclusion

Autogenous costal cartilage is an ideal graft material for larynx and trachea as it has minimal cell infiltration and its epithelialization, neovascularization, chondrocyte development scores are better. The most important disadvantages of this graft material are morbidity due to donor site and longer operative times. Cervical or mediastinal emphysema, local and systemic infection did not occur in any test subjects in all three groups whose life spans were equal. Rifting in the anastomosis area and microscopic suture failure did not occur. Excessive granulation tissue developed in one of the subjects in Group 3. There was no significant difference between all groups considering TCS calculated according to the measurements of intraluminal anteroposterior and transverse diameters of normal and tracheal graft segments in the subjects in all three groups. Group 1 was better in

terms of all parameters when TCS were examined histopathologically in three groups. New chondrocyte development was observed in Group 2 that underwent homograft grafting procedures. Since any case of stenosis, infection and rejection was not detected in all groups, and epithelialization and neovascularization occurred adequately (moderate) in all subjects, we think that it is worth to investigate use of Dacron® grafts in further studies with long-term outcomes.

Conflict of Interest: No conflicts declared.

References

- Albert DM, Cotton RT, Conn P. The use of alcohol-stored cartilage in experimental laryngotracheal reconstruction. *Int J Pediatr Otorhinolaryngol* 1989;18:147-55.
- Adlington P, Anscombe AJ, Phillips JJ. Influence of the mode of preparation on the long-term efficacy of homologous costal cartilage implants. *J Laryngol Otol* 1992;106:511-7.
- Ansari K, Asaria J, Hilger P, Adamson PA. Grafts and implants in rhinoplasty-Techniques and long-term results. *Operat Tech Otolaryngol* 2008;19:42-58.
- Amedee RG, Mann WJ, Lyons GD. Tracheomalacia repair using ceramic rings. *Otolaryngol Head Neck Surg* 1992;106:270-4.
- Yamamoto K, Kojima F, Tomiyama K, Nakamura T, Hayashino Y. Meta-analysis of therapeutic procedures for acquired subglottic stenosis in adults. *Ann Thorac Surg* 2011;91:1747-53.
- Richardson MA, Inglis AF Jr. A comparison of anterior cricoid split with and without costal cartilage graft for acquired subglottic stenosis. *Int J Pediatr Otorhinolaryngol* 1991;22:187-93.
- Neville WE, Bolanowski JP, Kotia GG. Clinical experience with the silicone tracheal prosthesis. *J Thorac Cardiovasc Surg* 1990;99:604-13.
- Cotton RT. The problem of pediatric laryngotracheal stenosis: a clinical and experimental study on the efficacy of autogenous cartilaginous grafts placed between the vertically divided halves of the posterior lamina of the cricoid cartilage. *Laryngoscope* 1991;101:1-34.
- Weisberger EC, Nguyen CT. Laryngotracheal reconstruction using a Vitallium alloy miniplate. *Ann Otol Rhinol Laryngol* 1996;105:363-6.
- Zalzal GH. Rib cartilage grafts for the treatment of posterior glottic and subglottic stenosis in children. *Ann Otol Rhinol Laryngol* 1988;97:506-11.
- Beigel A, Müller-Ruchholtz W. Tracheal transplantation. I. The immunogenic effect of rat tracheal transplants. *Arch Otorhinolaryngol* 1984;240:185-92.
- Cansiz H, Yener M, Dereköylü L. Tracheal reconstruction with free composite cartilage graft: a case report. *Kulak Burun Bogaz Ihtis Derg* 2002;9:291-5.
- Cansiz H, Yener HM, Sekercioglu N, Günes M. Laryngotracheal reconstruction with a muscle-pedicle hyoid bone flap: a series of 23 patients. *Ear Nose Throat J* 2004;83:424-7.
- Chan KH, Reilly JS, Hashida Y. A staged laryngotracheal reconstruction using alloplast (Proplast) in the canine model. *Int J Pediatr Otorhinolaryngol* 1990;18:227-39.
- Klein AM, Graham VL, Gulleth Y, Lafreniere D. Polyglycolic acid/poly-L-lactic acid copolymer use in laryngotracheal reconstruction: a rabbit model. *Laryngoscope* 115:583-7.
- Mitskavich MT, Rimell FL, Shapiro AM, Post JC, Kapadia SB. Laryngotracheal reconstruction using microplates in a porcine model with subglottic stenosis. *Laryngoscope* 1996;106:301-5.
- Hashem FK, Al Homsy M, Mahasin ZZ, Gammass MA. Laryngotracheoplasty using the Medpor implant: an animal model. *J Otolaryngol* 2001;30:334-9.
- Kaiser D. Alloplastic replacement of canine trachea with Dacron. *Thorac Cardiovasc Surg* 1985;33:239-43.
- Leake D, Habal M, Pizzoferrato A, Vespucci A. Prosthetic replacement of large defects of the cervical trachea in dogs. *Biomaterials* 1985;6:17-22.
- Wiatrak BJ, Albert DM, Holmes DK, Cotton RT. Cartilage graft epithelialization. A preliminary study using a goat model. *Arch Otolaryngol Head Neck Surg* 1993;119:777-81.
- Adlington P, Anscombe AJ, Phillips JJ. Influence of the mode of preparation on the long-term efficacy of homologous costal cartilage implants. *J Laryngol Otol* 1992;106:511-7.
- Keskin IG, Oz F, Oz B, Oktem F, Gustafson M. Tracheal reconstruction using alcohol-stored homologous cartilage and autologous cartilage in the rabbit model. *Int J Pediatr Otorhinolaryngol* 2000;56:161-7.
- Keskin G, Üstündağ E, Boyacı Z, Özkarakas H, Kaur A. İshiki tip I larengoplastide Dacron® ve gore-tex kullanımı: Deneysel bir çalışma. *Türk Otolarengoloji Arşivi* 2000;38:159-64.
- Shimizu Y, Tamura K, Kato H, Teramatsu T, Hino T. Study on the artificial trachea using mesh. *Jpn J Artif Organs (Jinkou Zouki)* 1983;12:486-9.
- Nelson RJ, Goldberg L, White RA, Shors E, Hirose FM. Neovascularity of a tracheal prosthesis/tissue complex. *J Thorac Cardiovasc Surg* 1983;86:800-8.
- Tsukada H, Osada H. Experimental study of a new tracheal prosthesis: pored Dacron tube. *J Thorac Cardiovasc Surg* 2004;127:877-84.
- Jacobs JR. Investigations into tracheal prosthetic reconstruction. *Laryngoscope* 1988;98:1239-45.
- Ergin NT, Koç C, Demirhan B, Dal T. Tracheal reconstruction with a vascularized cartilage flap in rabbits. *Ann Otol Rhinol Laryngol* 1998;107:571-4.

This is an open access article distributed under the terms of the Creative Commons Attribution-NonCommercial-NoDerivs 3.0 Unported (CC BY-NC-ND3.0) Licence (<http://creativecommons.org/licenses/by-nc-nd/3.0/>) which permits unrestricted noncommercial use, distribution, and reproduction in any medium, provided the original work is properly cited.

Please cite this article as: Baran Y, Öztürk K, Çalık M, Canbilen A, Esmel H. Comparison of costal cartilage and Dacron® graft in laryngotracheal reconstruction: an experimental study. *J Med Updates* 2013;3(3):101-108.