

Evaluation of The Effect of Intraocular Silicone Oil on Retinal Nerve Fiber Layer Thickness in Patients Treated with Pars Plana Vitrectomy and Endolaser for Rhegmatogenous Retinal Detachment

Pars Plana Vitrektomi ve Endolazer Tedavisi Uygulanan Regmatojen Retina Dekolmanlı Olgularda İntraoküler Silikon Yağının Retinal Sinir Lifi Kalınlığına Etkisinin Değerlendirilmesi

Enver MİRZA¹, Mehmet Kemal GÜNDÜZ², Günhal ŞATIRTAV³, Hürkan KERİMOĞLU², Günsu Deniz MİRZA⁴

ABSTRACT

Purpose: To evaluate the effect of silicone oil (SiO) on retinal nerve fiber layer thickness (RNFLT) by using optical coherence tomography in patients who underwent pars plana vitrectomy and SiO injection for retinal detachment.

Material and Methods: A total of 50 eyes of 50 patients were retrospectively enrolled in this study. 34 patients (68%) were male, 16 patients (32%) were female. SiO was injected in 50 eyes and the healthy fellow eyes (50 eyes) were evaluated as controls. RNFLT measurements were compared with the control eyes, one and three months after PPV and one month after SiO removal.

Results: In siliconized eyes the temporal, inferotemporal, nasal, inferonasal quadrants and global measurements were significantly thicker at first month after PPV compared to controls ($p < 0.001$, $p = 0.001$, $p = 0.044$, $p = 0.002$, $p < 0.001$ respectively). Temporal quadrant and global measurements were significantly thicker at third month after PPV ($p = 0.001$, $p = 0.034$). At first month after SiO removal, the temporal, nasal quadrants, global measurements were significantly thicker ($p = 0.004$, $p = 0.01$, $p = 0.018$). Also siliconized eyes RNFLT measurements were evaluated between first, second and third visit separately. Almost there was no significant difference in quadrants for the measurements of the subsequent visits.

Conclusions: A transient increase in RNFLT in some of the quadrants compared to the control eyes was found in the study due to the presence of SiO in the globe.

Key Words: Pars plana vitrectomy, rhegmatogenous retinal detachment, silicone oil, retinal fiber layer thickness.

ÖZ

Amaç: Retina dekolmanı nedeniyle pars plana vitrektomi yapıp silikon yağı tamponadı verilen hastalarda silikon yağının retinal sinir lifi tabakası (RSLT) kalınlığına etkisinin optik koherens tomografi ile değerlendirilmesi.

Materyal ve Metod: 50 hastanın 50 gözü çalışmaya katıldı. 34 hasta (%68) erkek, 16 hasta (%32) kadındı. 50 göze silikon verildi ve diğer sağlam gözler (50 göz) kontrol olarak değerlendirildi. Silikonize gözlerin PPV'den bir ay ve üç ay sonra ve silikon alımından bir ay sonraki RSLT ölçümleri kontrol gözlerin ölçümleriyle kıyaslandı.

Bulgular: Silikonize gözlerin PPV'den bir ay sonraki RSLT ölçümlerinde kontrol gözlerle kıyasla temporal, inferotemporal, nazal, inferonazal kadrantlarının ve global olarak istatistiksel olarak anlamlı kalın olduğu görüldü ($p < 0.001$, $p = 0.001$, $p = 0.044$, $p = 0.002$, $p < 0.001$).

1- Uz. Dr., Necmettin Erbakan Üniversitesi Meram Tıp Fakültesi, Göz Hastalıkları Anabilim Dalı, Konya, Türkiye

2- Prof. Dr., Necmettin Erbakan Üniversitesi Meram Tıp Fakültesi, Göz Hastalıkları Anabilim Dalı, Konya, Türkiye

3- Doç. Dr., Necmettin Erbakan Üniversitesi Meram Tıp Fakültesi, Göz Hastalıkları Anabilim Dalı, Konya, Türkiye

4- Asist. Dr., Necmettin Erbakan Üniversitesi Meram Tıp Fakültesi, Göz Hastalıkları Anabilim Dalı, Konya, Türkiye

Geliş Tarihi - Received: 15.11.2017

Kabul Tarihi - Accepted: 20.11.2017

Ret-Vit 2018; 27: 231-238

Yazışma Adresi / Correspondence Address:

Enver MİRZA

Necmettin Erbakan Üniversitesi Meram Tıp Fakültesi, Göz Hastalıkları Anabilim Dalı, Konya, Türkiye

Phone: +90 505 226 6292

E-mail: envermirza@gmail.com

sırasıyla). PPV'den üç ay sonraki ölçümlerde global olarak ve özellikle temporal kadranın istatistiksel olarak anlamlı kalın olduğu görüldü ($p=0.034, p=0.001$). Silikon alımından bir ay sonra temporal, nazal kadranın ve global olarak RSLT ölçümlerinin anlamlı kalın olduğu görüldü ($p=0.004, p=0.01, p=0.018$). Birinci, ikinci ve üçüncü vizitte yapılan silikonize gözlerin RSLT ölçümleri ayrıca kendi içlerinde de değerlendirildi ve ayrı ayrı kıyaslandığında istatistiksel olarak anlamlı kalınlık farklılığı olmadığı görüldü.

Sonuç: Silikonun göz içinde bulunduğu süre içerisinde bazı kadranlarda kısa süreli olsa da kontrol gözlerle kıyasla kalınlık artışı olduğu görülmüştür.

Anahtar Kelimeler: Pars plana vitrektomi, regmatojen retina dekolmanı, silikon yağı, retina sinir lifi kalınlığı.

INTRODUCTION

Retinal detachment (RD), which is defined as the detachment of neurosensory retina from the retinal pigment epithelium, is a pathological condition that can cause blindness due to the functional loss of retina if left untreated. The incidence of RD is reported as 0.01%.¹

In the treatment of RD, different surgical methods may be performed including pneumatic retinopexy, conventional retinal detachment surgery with scleral buckling and pars plana vitrectomy (PPV). Together with PPV, some intraocular endotamponades such as silicone oil (SiO), perfluorocarbons, gas or air, may be used to enhance the retina attachment and improve the long term anatomical and functional success. Although SiO is one of the most commonly preferred intraocular endotamponades, some complications, side effects and toxic effects such as glaucoma, cataract and keratopathy have been reported. In addition, some rare complications due to the mechanical effects of SiO such as retinal vein-artery occlusion, retinal hemorrhage and optic atrophy have also been reported.²

In this study, the effects of SiO on peripapillary retinal nerve fiber layer thickness (RNFLT) were evaluated by spectral domain optical coherence tomography (OCT) in patients who underwent PPV due to rhegmatogenous RD.

MATERIAL and METHOD

Fifty eyes of 50 patients who underwent PPV and SiO endotamponade injection and subsequent SiO removal for rhegmatogenous RD between June 2013 and May 2015 in our clinic were included in the study. The patients with media opacity such as cataract, corneal blurring or inflammatory conditions, other retinal diseases, uveitis or optic disk abnormalities and patients with visual acuity of light perception or hand movements in postoperative period were excluded from the study.

Sixteen (32%) patients were female and 34 (68%) patients were male. The contralateral eyes served as controls. Best corrected visual acuity (BCVA - LogMAR), intraocular pressure (IOP), biomicroscopic and funduscopy findings were recorded preoperatively, one month after PPV and one month after SiO removal.

The operations were performed under subtenon anaesthesia

with standard 25 G PPV and SiO injection. Following core vitrectomy and meticulous shaving of peripheral retina, the retina was reattached with decalin (perfluorocarbon) and endolaser photocoagulation was performed around the retinal tears and 360 degree on peripheral retina and pathological areas, followed by SiO injection. Heavy SiO (1387 cst density 1.06 g/cm³) was preferred in patients with retinal breaks located at the inferior 120 degrees and standard SiO (1000 cst density 0.971 g/cm³) was preferred in superior retinal breaks. The retina was completely reattached in all eyes included in the study. Follow up examinations were performed on the next day, in the first month, and once a month till the removal of SiO and monthly after SiO removal for an average of three months.

Anatomical success was defined as the reattachment of the retina after the extraction of SiO in postoperative period of PPV. The patients without anatomical success were not included in the study. IOP was measured with Goldmann applanation tonometry after topical 0.5% proparacaine HCl administration. The eyes with the IOP measurements of greater than 22 mmHg were diagnosed with secondary glaucoma. Nuclear or posterior subcapsular opacities developed in the follow-up period were classified as complicated cataract.

In all cases, peripapillary RNFLT was measured with Spectralis OCT (Spectralis OCT, Heidelberg Engineering, Heidelberg, Germany). Spectralis OCT uses an algorithm that identifies the centre of the optic nerve head and automatically places a calculation circle of 3,6 mm diameter around it. The RNFLT values were recorded as superotemporal, temporal, inferotemporal, superonasal, nasal, inferonasal quadrants and globally. All scans were performed by the same operator.

All statistical analyses of this study were performed with SPSS 16.0 package program. Categorical data were defined as the frequency and percentage rates, while numerical data were reported as mean \pm standard deviation (median, min, max) in independent samples tests. The distributions of continuous variables were analyzed with Kolmogorov-Smirnov test. Independent samples Student t-test was used to compare the numerical data of two groups. One-way and two way variation analysis of repeated measures was used to determine the differences of measurements obtained in altered time intervals. The study was approved by the Medical, Surgical and Drug Investigations Ethical Committee of

Necmettin Erbakan University Meram Medical Faculty. The study allied to the tenets of the Declaration of Helsinki.

RESULTS

Fifty eyes of 50 patients (34 males, 16 females) were enrolled in the study. Demographic data and clinical characteristics are given in Table 1.

In the two way variance analysis, RNFLT measurements were evaluated between siliconized eyes and control eyes at every visit. A patient's OCT scan, is demonstrating the RNFLT measurement between siliconized eye and control eye, as presented in Figure 1. At first month after PPV, the temporal, inferotemporal, nasal, inferonasal quadrants and global measurements were significantly thicker compared to controls ($p < 0.001$, $p = 0.001$, $p = 0.044$, $p = 0.002$, $p < 0.001$ respectively). At third month after PPV, temporal quadrant and global measurements were significantly thicker compared to controls ($p = 0.001$, $p = 0.034$). At first month after SiO removal, the temporal and nasal quadrants, and global measurements were significantly thicker compared to controls ($p = 0.004$, $p = 0.01$, $p = 0.018$) (Figure 2, Table 2).

Also RNFLT measurements of siliconized eyes were compared between first month after PPV and third month after PPV. At first month after PPV only nasal quadrant measurements were significantly thicker compared to third month after PPV measurements ($p = 0.030$) but there was no significant difference of any quadrant between first month after PPV and first month after SiO removal measurements or between third month after PPV and first month after SiO removal measurements (Figure 3).

When RNFLT measurements were compared between the standard and heavy SiO eyes, there was a significant difference in inferonasal quadrant at first month after PPV ($p = 0.027$). There was no significant difference in other quadrants for the measurements of the subsequent visits.

BCVA, IOP values before PPV, one month after PPV and one month after SiO removal are shown in Table 3. BCVA values were increased after PPV and SiO removal. In fifteen of the standard siliconized eyes and in two of the heavy siliconized eyes, phacoemulsification surgery was performed after PPV. In 32 patients, topical antiglaucomatous medications were required for the IOP regulation. The incidence of raised IOP at one month after PPV was 64% (Standard SiO $n = 25$, heavy SiO $n = 7$). After SiO removal, topical antiglaucomatous medications requirement was 26% (Standard SiO $n = 8$, heavy SiO $n = 5$).

The mean duration of SiO in the operated eyes ranged between 82-287 days (Table 1). The mean duration of SiO was 119 days in standard SiO group and 90 days in heavy SiO group. The mean number of laser photocoagulation spots were 2354.17 ± 854.24 (Table 1). The mean number of laser photocoagulation spots were 2481 in standard SiO group and 1948 in heavy SiO group. There was no significant correlation between the increase of RNFLT and number of photocoagulation spots. The number of laser photocoagulation spots and the duration of SiO in eyes were significantly higher in standard SiO group ($p = 0.017$ and $p = 0.028$).

DISCUSSION

SiO, first used by Cibis in vitreoretinal surgery, is one of the most commonly preferred intraocular endotamponades in the treatment of complicated RD cases.³ SiO is in use with an increasing rate, especially in proliferative vitreoretinopathy, proliferative diabetic retinopathy, degenerative myopia, RD with giant tears, ocular trauma or complicated RD cases since it has high anatomical and functional success rates.^{4,5} The superiority of SiO to gas endotamponade is always controversial. In the Silicone Oil Study⁶, in eyes with advanced PVR, the functional and anatomical success of SiO was higher than SF₆ gas and similar to that of C₃F₈ gas.⁷ Lee et al⁸ reported that in patients who required RD repair, SF₆ or C₃F₈

Table 1. Demographic data and clinical characteristics

	N	%
Gender (Male/Female)	34/16	68/32
Operated Eye (Right/Left)	33/17	66/34
SiO type (Standard/Heavy)	37/13	74/26
Phakic/Pseudophakic	26/24	52/48
	Mean±sd	Median, min, max
Age (years)	55,56±12,27	58, 26, 77
SiO duration (days)	120.07±41.18	105, 82, 287
Laser photocoagulation spots	2354,17±854,243	2127, 614, 4650

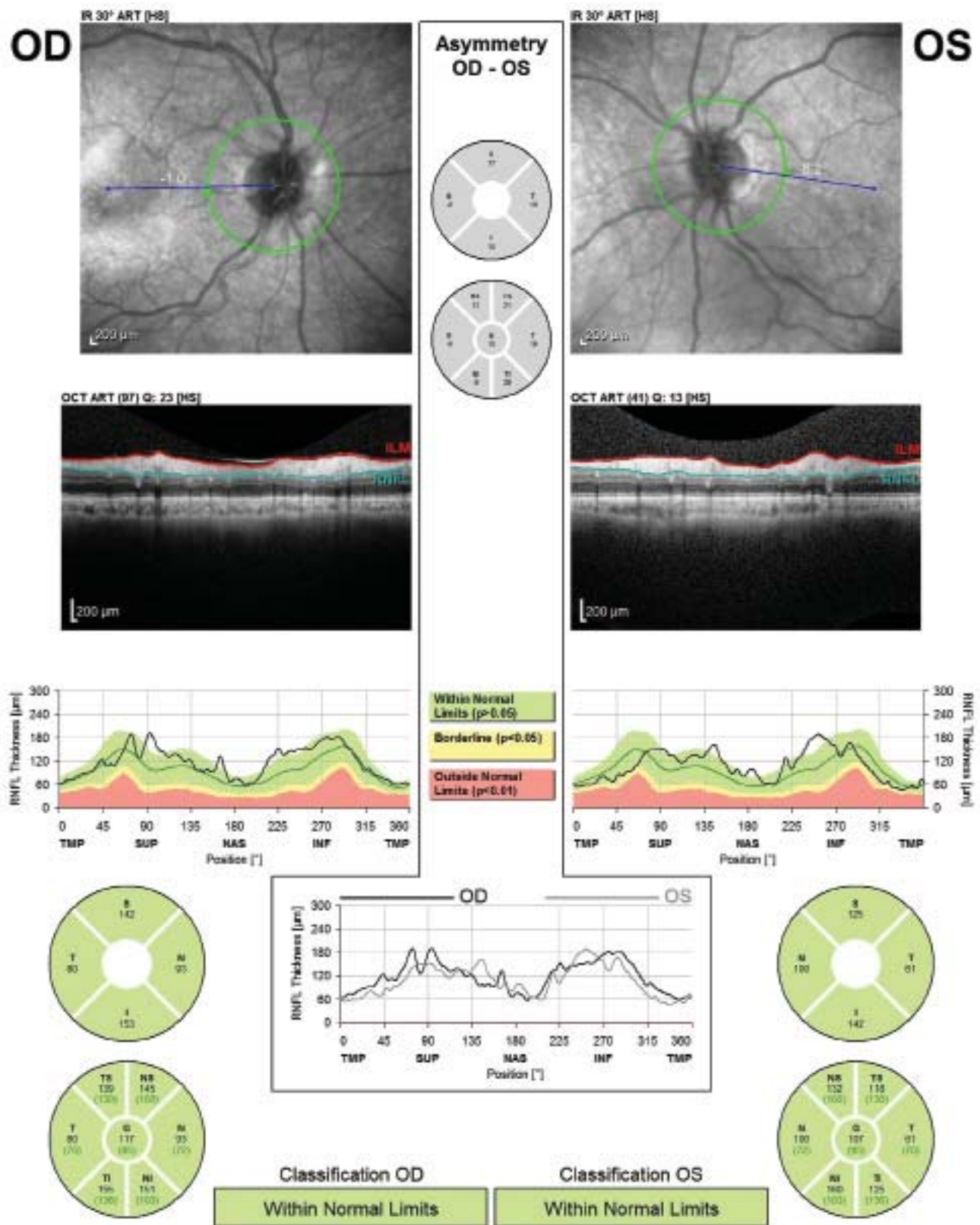


Figure 1. A patient's OCT scan, RNFLT measurement of siliconized eye (OD) and control eye (OS).

gases were used and in 6 months of follow-up, there was no difference between operated eyes and control eyes regarding the RNFLT. In 12 and 24 months of follow-up, there was a decrease in RNFLT measurements in affected eyes.

Although postoperative anatomical and functional success rates are increased with the SiO usage, it also has some toxic effects and complications. The most commonly observed effects are cataract, secondary glaucoma and keratopathy

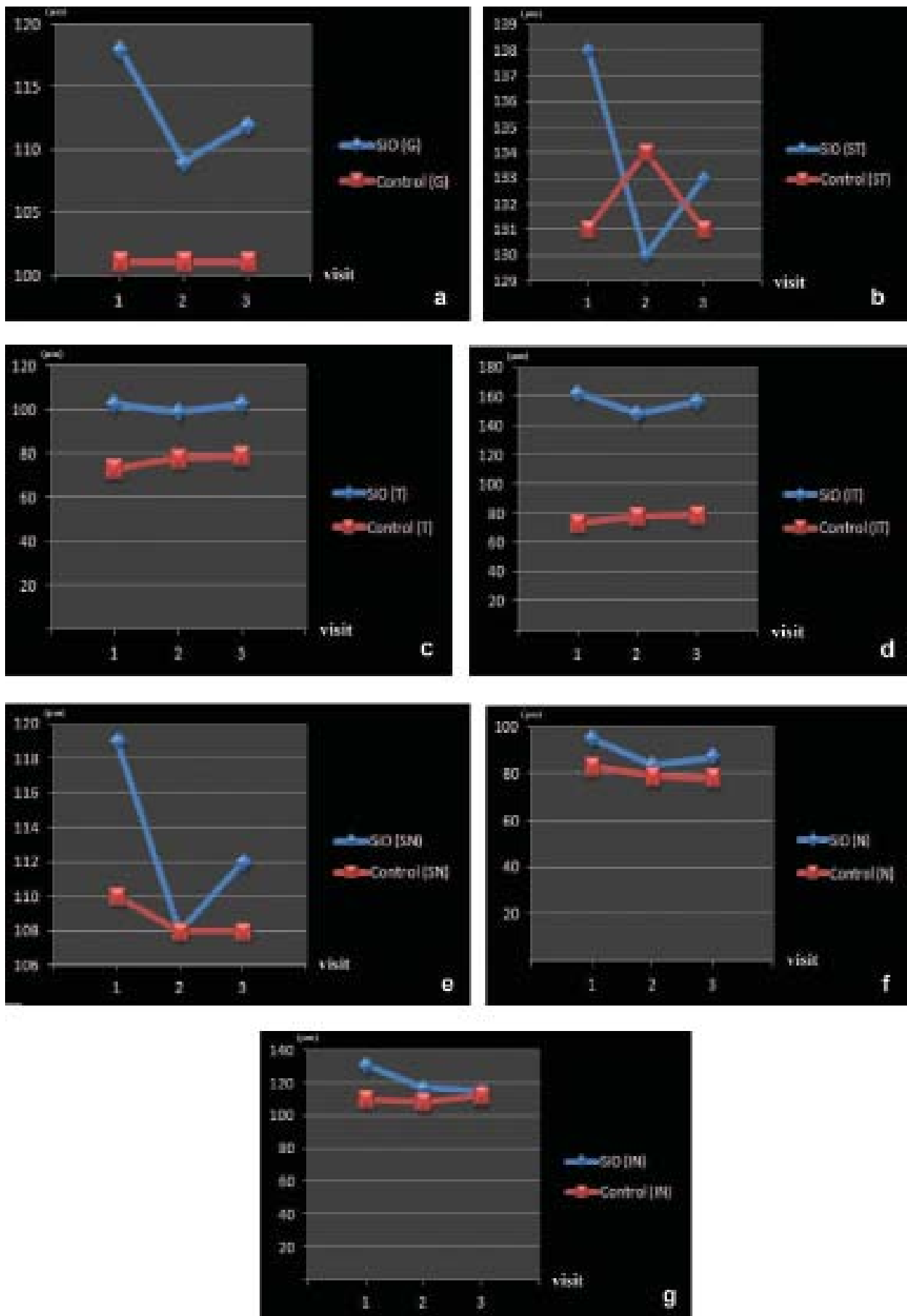


Figure 2. Difference of RNFLT measurements between siliconized eyes and control eyes in 7 quadrants at three visits. **a)** Globally, **b)** In superotemporal quadrants, **c)** In temporal quadrants, **d)** In inferotemporal quadrants, **e)** In superonasal quadrants, **f)** In nasal quadrants, **g)** In inferonasal quadrants

Table 2. Peripapillary RNFLT measurements of siliconized eyes and control eyes				
		Siliconized	Control	
		Mean±sd	Mean±sd	P
1 month after PPV (µm)				
	Global	118.76±25.31	101.24±15.83	<0.001
	Superotemporal	138.78±32.43	131.54±27.16	0.188
	Temporal	103.14±39.26	73.28±16.92	<0.001
	Inferotemporal	162.04±45.46	140.84±25.71	0.001
	Superonasal	119.94±28.69	110.58±27.79	0.058
	Nasal	95.44±24.05	83.64±33.83	0.044
	Inferonasal	131.92±40.87	110.96±28.99	0.002
3 months after PPV (µm)				
	Global	109.10±21.85	101.40±18.33	0.034
	Superotemporal	130.74±38.09	134.80±31.91	0.570
	Temporal	99.40±39.05	78.00±30.30	0.001
	Inferotemporal	148.92±38.46	144.26±27.56	0.366
	Superonasal	108.6±31.80	108.6±25.62	0.999
	Nasal	84.88±21.44	79.02±20.70	0.120
	Inferonasal	117.12±37.63	108.84±27.75	0.125
1 month after SiO removal (µm)				
	Global	112.86±29.94	101.64±15.22	0.018
	Superotemporal	133.76±48.93	131.00±19.28	0.691
	Temporal	103.46±46.67	79.08±38.89	0.004
	Inferotemporal	156.42±46.92	145.60±27.60	0.121
	Superonasal	112.22±35.39	108.20±21.99	0.340
	Nasal	87.84±22.27	78.38±15.23	0.010
	Inferonasal	115.62±37.02	112.8±29.63	0.665

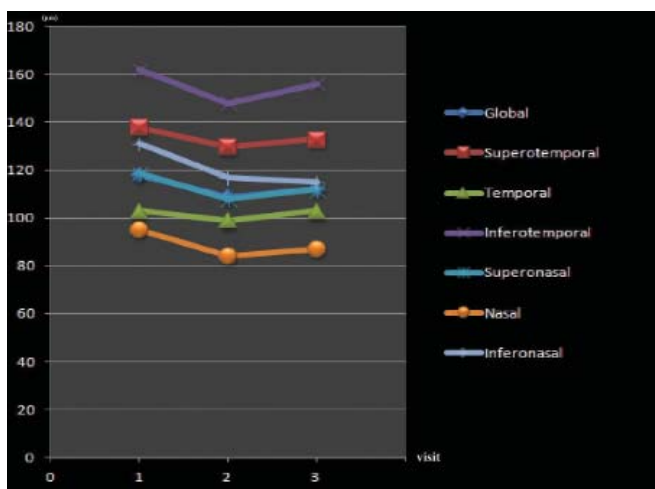


Figure 3. Difference of siliconized eyes RNFLT measurements in 7 quadrants at three visits.

while optic atrophy has also been rarely reported.² IOP elevations may also be seen due to SiO usage. After SiO usage, IOP increase was observed in 56% and among those 22% were reported to require treatment.⁹ The angle closure may be caused by the mechanical effect of SiO pushing the lens iris diaphragm anteriorly or total closure of pupil area by SiO in anterior chamber. The IOP increases seen in postoperative early periods may easily be controlled with topical antiinflammatory or antiglaucomatous agents even if it is not due to a mechanical cause.¹⁰ In this study, topical antiglaucomatous treatment was prescribed in 32 (64%) patients after PPV, and, continuation of topical treatment was required in 13 (26%) patients after SiO removal.

Infiltration of SiO into the retina and posterior migration in the optic nerve has been observed in a number of case series, several histopathological studies, performed in animal

Table 3. BCVA and IOP values			
	Total	Standard SiO	Heavy SiO
		LogMar BCVA±sd	
Pre-operative	1.01±0.67	1.04±0.72	0.95±0.56
1 month after PPV	0.65±0.72	0.63±0.72	0.72±0.72
1 month after SiO removal	0.36±0.55	0.31±0.55	0.53±0.61
		IOP±sd	
Pre-operative	14.02±2.81	14.06±2.89	13.62±2.82
1 month after PPV	14.07±5.50	15.23±4.92	13.08±5.35
1 month after SiO removal	14.24±3.18	15.44±2.72	12.08±3.50

models and on enucleated eyes. Papp et al¹¹ demonstrated that vitrectomy combined with heavy SiO endotamponade causes a severe loss of the myelinated optic nerve fibres in adult rabbits. Wickham et al¹² have shown that SiO may be sequestered in varied ocular tissues like iris, ciliary body, trabecular meshwork and retina by electron microscopy. Also Wickham et al¹³ have demonstrated that SiO infiltrates ERMs, produces an inflammatory reaction and this response can be observed within 1 month after SiO injection and continues after SiO removal. Budde et al¹⁴ reported that in 14 of 74 enucleated eyes, optically empty vacuoles regarded as SiO vacuoles with an associated inflammatory reaction were observed in the retrolaminar optic nerve. Errera et al¹⁵ detected small hyperreflective areas likely small bubbles of emulsified silicone intraretinally, subretinally, and underneath epiretinal membranes in eyes that have had SiO endotamponade using spectral domain OCT.

Some authors consider that raised IOP is the main factor for the migration of SiO into intraocular tissues. In a histopathological study of enucleated SiO-filled eyes, SiO vacuoles were seen in the optic nerve in eyes with neovascular glaucoma.¹⁶ There was no definite histopathological correlation between duration of endotamponade and distribution of SiO vacuoles. Knorr et al¹⁷ showed that the presence of SiO vacuoles in the retina as early as four weeks after SiO injection and in the optic nerve with raised IOP. Also, they concluded that there was no clinicohistopathological correlation between the presence of vacuoles in the retina or optic nerve and the duration and viscosity of intraocular SiO. In our study, all patients with >22 mmHg IOP was medically regulated immediately, hence we could not evaluate the effect of elevated IOP on RNFLT in siliconized eyes.

Maia et al¹⁸ performed RNFLT evaluation with time-domain OCT at the first week as well as the first, third and sixth months after panretinal photocoagulation (PRP). They demonstrated that there was no reduction of RNFLT had not been observed in the short and medium term of photocoagulation, however a significant increase in temporal

RNFLT was observed up to six months post-PRP, without any reduction in RNFLT after six months. In a time-domain OCT based retrospective chart review conducted by Kim et al¹⁹ statistically significant decrease in the average RNFLT at two years after PRP treatment was reported, whereas the mean RNFLT score slightly increased during the initial three months after photocoagulation. Authors reported statistically significant reduction in RNFLT within the superior and inferior quadrants at two years post-PRP as well as a borderline significant decrease of nasal quadrant at two years after photocoagulation; however no reduction in RNFLT within the temporal quadrant was not observed up to 36 months post-PRP. Increase in RNFLT at the third month of follow-up may be related to laser induced intraretinal inflammation which triggers increased capillary permeability and ensues axonal edema due to the cytokine release. Significant RNFLT decrease at the sixth month of follow-up can be attributed to axonal loss secondary to direct or indirect effects of PRP treatment. Ozdek et al²⁰ reported that argon laser treatment for DR causes reduction in the average RNFLT and this decrease also could be interpreted as a loss in RNFLT depending on the damage caused by the laser. This can be the rationale underlying the optic atrophy that develops after PRP in some patients. Also DR caused a significant decrease in RNFLT and it has been shown that there can be a reduction in RNFLT even without retinopathy.^{21,22}

Recently Geber et al²³ evaluated only the median peripapillary RNFLT in 57 patients with SiO endotamponade and reported that the median peripapillary RNFLT was significantly thicker in comparison with fellow unoperated eyes over a 6 month period. In our study we performed RNFLT measurements in 7 quadrants and also compared siliconized eyes RNFLT measurements with separately at three sequential visits but almost there was no significant difference between siliconized eyes RNFLT measurements in comparison with these visits and additionally in some quadrants of the siliconized eyes RNFLT measurements were significantly thicker in comparison with control eyes.

In light of all these reports, the transient increase in RNFLT in some of the quadrants compared to the control eyes in our study may be attributed to several factors. The increase may be due to infiltration of ocular tissues with SiO particles as shown by previously discussed reports,¹²⁻¹⁵ or it may be a transient increase related to the laser induced inflammation as discussed by Kim et al¹⁹ One of the factors that could be taken into consideration is the possible preoperative misinterpretation of the measurements due to the presence of SiO in the ocular media. Further studies are needed to evaluate the accuracy and reliability of RNFLT measurements in the presence of intraocular SiO.

CONCLUSIONS

In conclusion we showed that the time elapsed SiO endotamponade onset caused a transient increase in some of the quadrants of RNFLT at the first and third months after PPV which returned to baseline values after the SiO removal. There was no significant difference in quadrants for siliconized eyes RNFLT measurements of the subsequent visits and there was no difference between standard and heavy SiO concerning RNFLT measurements. It might be prudent and necessary to integrate RNFLT measurements in management of patients with RD operated with PPV, SiO injection and removal. In this study, complications such as cataract and secondary glaucoma incidence were consistent with the previous studies. Nevertheless, there are several limitations of this study. The pathological effect of the detached retina itself on RNFLT, the surgical repair and the endolaser photocoagulation may have been responsible for some of the reported changes. Concerning these factors further studies are needed to evaluate the effect of SiO on RNFLT in a prospective trial with larger sample size.

REFERENCES/ KAYNAKLAR

1. Haimann NH, Burton TC, Brown CK. Epidemiology of retinal detachment. *Arch Ophthalmol.* 1982; 100: 289-92.
2. Caswell AG, Gregor ZJ. Silicone oil removal I. The effect on the complications of silicone oil. *Br J Ophthalmol.* 1987; 71: 71: 893-7.
3. Cibis PA, Becker B, Okun E, Canaan S. The use of liquid silicone in retinal detachment surgery. *Arch Ophthalmol.* 1962; 68: 590-9.
4. Antoszyk AN, McCuen BW II, de Juan E Jr, Machemer R. Silicone oil injection after failed primary vitreous surgery in severe ocular trauma. *Am J Ophthalmol* 1989; 107:537-43.
5. Sima P, Zoran T. Long term results of vitreous surgery for proliferative diabetic retinopathy. *Doc Ophthalmol.* 1994; 87: 223-32.
6. The Silicone Study Group: Vitrectomy with silicone oil or perfluoropropane gas in eyes with severe proliferative vitreoretinopathy: results of a randomized clinical trial. *Silicone Study Report 2. Arch Ophthalmol.* 1992; 110:780-92.
7. Kaynak S. Göziçi tamponatlarında komplikasyonlar. *Ret-Vit* 2000; Özel sayı: 138-52.
8. Lee YH, Lee JE, Shin YI, Lee KM, Jo YJ, Kim JY. Longitudinal changes in retinal nerve fiber layer thickness after vitrectomy for rhegmatogenous retinal detachment. *Invest Ophthalmol Vis Sci.* 2012; 53: 5471-4.
9. deCorral LR, Cohen SB, Peyman GA. Effect of intravitreal silicone oil on intraocular pressure. *Ophthalmic Surg.* 1987; 18: 446-9.
10. Honavar SG, Goyal M, Majji AB, Sen PK, Naduvilath T, Dandona L. Glaucoma after pars plana vitrectomy and silicone oil injection for complicated retinal detachments. *Ophthalmology.* 1999; 106: 169-76.
11. Papp A, Kiss EB, Timár O, Szabo E, Bercki A, Toth J, Pali J. Long-term exposure of the rabbit eye to silicone oil causes optic nerve atrophy. *Brain Research bull.* 2007; 74: 130-3.
12. Wickham L, Asaria RH, Alexander R, Luthert P, Charteris DG. Immunopathology of intraocular silicone oil: Enucleated eyes. *Br J Ophthalmol* 2007; 91: 253-7.
13. Wickham L, Asaria RH, Alexander R, Luthert P, Charteris DG. Immunopathology of intraocular silicone oil: Retina and epiretinal membranes. *Br J Ophthalmol.* 2007; 91: 258-62.
14. Budde M, Cursiefen C, Holbach LM, Naumann GO. Silicone oil-associated optic nerve degeneration. *Am J Ophthalmol.* 2001; 131: 392-4.
15. Errera MH, Liyanage SE, Elgohary M, Day AC, Wickham L, Patel PJ, Sahel JA, Pauges M, Ezra E, Sullivan PM. Using spectral-domain optical coherence tomography imaging to identify the presence of retinal silicone oil emulsification after silicone oil tamponade. *Retina.* 2013; 33: 1567-73.
16. Biswas J, Verma A, Davda MD, Ahuja S, Pushparaj V. Intraocular tissue migration of silicone oil after silicone oil tamponade: A histopathological study of enucleated silicone oil-filled eyes. *Indian J Ophthalmol.* 2008; 56: 425-8.
17. Knorr HL, Seltsam A, Holbach L, Naumann GO. Intraocular oil tamponade. A clinic-pathologic study of 36 enucleated eyes. *Ophthalmologie* 1996; 93: 130-8.
18. Maia OO Jr, Vessani RM, Takahashi WY, Susanna R Jr. Examination of the retinal nerve fiber layer in diabetic retinopathy treated by argon laser panphotocoagulation. *Arq Bras Oftalmol* 2008; 71: 187-90.
19. Kim J, Woo SJ, Ahn J, Park KH, Chung H, Park KH. Long-term temporal changes of peripapillary retinal nerve fiber layer thickness before and after panretinal photocoagulation in severe diabetic retinopathy. *Retina* 2012; 32: 2052-60.
20. Özdek Ş, Özdoğan S, Önoğlu M, Gürelik G, Hasanreisioğlu B. Panretinal fotokoagülasyonun retina sinir lifi tabakası üzerine etkisinin NFA-GDX ile değerlendirilmesi. *Ret-Vit* 2003; 11: 250-5.
21. Özdek SC, Lonzeville Y, Önoğlu M, Yetkin I, Hasanreisioğlu B. Assessment of nerve fiber layer in diabetic patients with scanning laser polarimetry. *Eye.* 2002, 16: 761-5.
22. Lopes de Faria JM, Russ H, Costa VP. Retinal nerve fiber layer loss in patients with type I diabetes mellitus without retinopathy. *Br J Ophthalmol.* 2002; 86: 725-8.
23. Geber MZ, Bencic G, Vatavuk Z, Ivekovic R, Friberg TR. Retinal nerve fiber layer thickness measurements after successful retinal detachment repair with silicone oil endotamponade. *Br J Ophthalmol.* 2015; 99: 853-8.