

# Clinical Outcomes of Large Meningomyelocele Defect Repair by Bilateral Fasciocutaneous Rotation and Advancement Flaps with Perforators

## Geniş Meningomyelosele Defektlerinin Perforatörlü Bilateral Fasyokutan Rotasyon ve İlerletme Flepleri ile Onarımının Klinik Sonuçları

Mustafa Kürşat Evrenos<sup>1</sup>, Haldun Onuralp Kamburoğlu<sup>2</sup>, Mehmet Seçer<sup>3</sup>, Kadir Çınar<sup>4</sup>, Mehmet Dadacı<sup>5</sup>, Bilseve İnce<sup>5</sup>

<sup>1</sup>Department of Plastic, Reconstructive and Aesthetic Surgery, Celal Bayar University School of Medicine, Manisa, Turkey

<sup>2</sup>Department of Plastic, Reconstructive and Aesthetic Surgery, Hacettepe University School of Medicine, Ankara, Turkey

<sup>3</sup>Clinic of Neurosurgery, Dr. Ersin Arslan Training and Research Hospital, Gaziantep, Turkey

<sup>4</sup>Clinic of Neurosurgery, Private Sani Konukoğlu Hospital, Gaziantep, Turkey

<sup>5</sup>Department of Plastic, Reconstructive and Aesthetic Surgery, Necmettin Erbakan University School of Medicine, Konya, Turkey

113

### Abstract

**Objective:** Neural tube defects occur in approximately one in 1000 live births in the US. Myelomeningocele (MMC) is the most common and severe form of spina bifida aperta. In this study, we present a surgical modification of the bilateral fasciocutaneous rotation and advancement flap technique in MMC patients.

**Material and Methods:** Twenty-four patients (12 male, 12 female) with MMC who were operated on between August 2011 and June 2013 were retrospectively evaluated. Presence of hydrocephalus, the neurological status, and the level and size of the MMC were recorded. We used bilateral perforator-based fasciocutaneous rotation and advancement flaps for defects larger than 3 cm in width, or in the presence of prominent kyphosis together with any defect size.

**Results:** The follow-up period ranged from eight days to two years. One patient died on the eighth day after surgery because of sepsis secondary to aspiration pneumonia. One patient had cerebrospinal fluid accumulation under the repair zone. In another patient, cerebrospinal fluid leakage through the repaired incision was observed on the ninth day after surgery. Three patients had minimal wound dehiscence at the distal end of the suture line.

**Conclusion:** In this study, 24 patients were treated with the described perforator-based technique by preserving at least one perforator vessel on each side. Reconstruction of MMC defects with paraspinal fasciocutaneous rotation and advancement flaps is still one of the best choices for closing moderate-to-large defects without using skin graft, and the safety of the flaps increases by preserving the perforators.

**Keywords:** Myelomeningocele, meningomyelocele, fasciocutaneous flap, perforator flap

### Öz

**Amaç:** Nöral tüp defektleri Amerika Birleşik Devletleri'nde yılda 1000 canlı doğumda bir ortaya çıkmaktadır. Myelomeningosel, Spina Bifida Aperta deformitesinin en yaygın ve en ağır formudur. Bu çalışmada, myelomeningosel hastalarında bilateral fasyokutanöz rotasyon ve ilerletme flebi tekniğinin cerrahi modifikasyonunu sunuyoruz.

**Gereç ve Yöntemler:** Ağustos 2011 ile Haziran 2013 arasında opere edilen 24 myelomeningosel hastası (12 erkek, 12 kız) retrospektif olarak analiz edildi. Hidrosefali varlığı, nörolojik durum ve myelomeningoselin düzeyi ve boyutu kaydedildi. Defekt boyutunun 3 cm'den daha geniş olduğu ya da kifoz deformitesinin eşlik ettiği durumlarda, perforatör bazlı bilateral fasyokutan rotasyon flebi kullanıldı.

**Bulgular:** Takip süresi sekiz gün ile iki yıl arasında gerçekleşti. Bir hasta postoperatif sekizinci günde aspirasyon pnömonisine sekonder sepsis nedeniyle kaybedildi. Bir hastada onarım bölgesi altında beyin omurilik sıvısı birikimi saptandı. Bir hastada ise postoperatif dokuzuncu günde onarım hattından beyin omurilik sıvısı sızıntısı gözlemlendi. Üç hastada onarım hattı distalinde minimal dehissans gözlemlendi.

**Sonuç:** Bu çalışmada 24 hastada defekt rekonstrüksiyonu, her bir tarafta en az bir perforatörün korunduğu perforatör bazlı teknik ile gerçekleştirildi. Paraspinal fasyokutan rotasyon ve ilerletme flepleri, geniş myelomeningosel defektlerin onarımında greft kullanımına gerek bırakmayan en uygun rekonstrüksiyon seçeneğidir ve perforatör korunması ile flep güvenliği artar.

**Anahtar Sözcükler:** Meningomyelosele, myelomeningosel, fasyokutan flep, perforatör flep

*Cite this article as:* Evrenos MK, Kamburoğlu HO, Seçer M, Çınar K, Dadacı M, İnce B. Clinical Outcomes of Large Meningomyelocele Defect Repair by Bilateral Fasciocutaneous Rotation and Advancement Flaps with Perforators. *Turk J Plast Surg* 2017; 25(3): 113-119.

Correspondence Author / Sorumlu Yazar: Mustafa Kürşat Evrenos, MD E-mail / E-posta: mkevrenos@hotmail.com



Content of this journal is licensed under a Creative Commons Attribution-NonCommercial 4.0 International License.

Received / Geliş Tarihi: 02.10.2016  
Accepted / Kabul Tarihi: 20.02.2017

**INTRODUCTION**

Neural tube defects occur in approximately one in 1000 live births in the US.<sup>1</sup> Failure of fusion of the vertebral arches during primary neurulation at 18-28 days after fertilization seems to be responsible for these kinds of defects.<sup>2</sup> Myelomeningocele (MMC) is the most common and severe form of spina bifida aperta. The etiology of neural tube defects can be genetic, environmental (geographical conditions), social (low socio-economic status), and folic acid deficiency. The main objective in closing MMC defects is to preserve the function of the neural tissues and to prevent secondary infections.<sup>3</sup> Many techniques have been described to close these defects, including primary closure or composite soft tissue transfer. This variety of surgical approaches is the result of the anatomical factors such as localization and size of the defect.<sup>4</sup>

There are two main goals when closing these defects. The first is to provide a generous, durable, and tension-free soft tissue and skin coverage over the repaired dura. This is especially important to minimize the risk of cerebrospinal fluid (CSF) leakage and infection. The second is to restore the natural soft

tissue contours and to minimize morbidity secondary to the local rearrangement of the muscles and soft tissues.<sup>5</sup> Generally, the musculocutaneous and random, or perforator-based fasciocutaneous flaps are regarded as robust and reliable. The integument situated between the iliac crest and the costal margin has the potential of a versatile flap (with blood supply from the lumbar and intercostal arteries). Additionally, the scar can be very well concealed if the flap is appropriately designed. In this study, we present our series of patients who were treated with bilateral fasciocutaneous flaps in which at least one regional perforator vessel was preserved.

**MATERIAL AND METHODS**

Parents of all patients were given information about the surgical techniques before operation, and their approvals were obtained and maintained in accordance with the principles of the World Medical Association Declaration of Helsinki "Ethical Principles for Medical Research Involving Human Subjects" (amended in October 2013). Twenty-four consecutive MMC patients were operated on with this technique between August 2011 and June 2013. All patients' age, gender, concom-

Table 1. Patient records

Patient	Age at surgery	Gender	Localization	Defect size	Number of defects	Concomitant problems
1	3 days	M	TL	4.6x7.8 cm	One	Paraplegia, sphincter disorder
2	5 days	F	TL	5.2x8.4 cm	One	Paraplegia, sphincter disorder
3	4 days	M	TL	5.1x6.4 cm	One	Paraplegia
4	4 days	F	TL	5.2x5.8 cm	One	Paraplegia
5	4 days	M	TL	6.1x9.8 cm	One	Paraplegia
6	4 days	M	TL	4.8x7.4 cm	One	Paraplegia
7	5 days	F	TL	5.2x6.8 cm	One	Paraplegia
8	4 days	F	TL	10.2x15.4 cm	One	Arnold Chiari type 2
9	3 days	F	L	4.3x5.1 cm	One	Paraplegia
10	4 days	M	TL	6.3x8.8 cm	One	Arnold Chiari type 2
11	3 days	F	TL	4.4x8.3 cm	One	Paraplegia
12	4 days	M	TL	7.2x8.6 cm	One	Paraplegia
13	4 days	F	TL	5.1x7.2 cm	One	Paraplegia, sphincter disorder
14	4 days	M	L	4.2x4.8 cm	One	Paraplegia
15	5 days	F	TL	7.1x12.3 cm	One	Paraplegia, sphincter disorder
16	4 days	M	TL	6.0x7.4 cm	One	Paraplegia, sphincter disorder
17	3 days	M	TL	4.2x9.1 cm	One	Paraplegia, spinal lordosis, and kyphosis
18	3 days	F	L	4.3x4.6 cm	One	Paraplegia
19	4 days	M	L	4.1x4.9 cm	One	Paraplegia
20	5 days	M	T / TL	2.1x2.2/4.6x6.8 cm	Two	Paraplegia, spinal lordosis, and kyphosis
21	3 days	F	L	3.2x4.0 cm	One	Kyphosis, paraplegia
22	4 days	F	L	3.0x3.6 cm	One	Kyphosis
23	5 days	M	TL	8.2x11.4 cm	One	Paraplegia
24	4 days	F	TL	5.2x8.2 cm	One	Paraplegia

M: male; F: female; TL: thoracolumbar; L: lumbar

itant anomalies and other diseases, and size and location of the defect were recorded (Table I). All patients had surgery in their first five days of life. Dural repairs were performed by the neurosurgery team. A concomitant ventriculo-peritoneal shunt was placed in order to manage prominent hydrocephalus if present. No drains were used in any of the cases. Postoperatively, all patients were followed up in the neonatal intensive care unit for at least 3 days in a prone position.

### Operative Technique

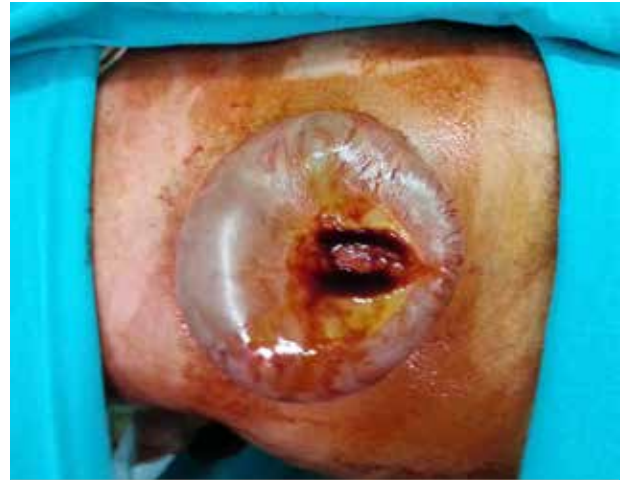The operation was performed under general anesthesia while the patient was lying in a prone position (Figure 1). The skin incision was performed along the midline just proximal to the MMC sac. The incision was carried caudally and away from the midline along the side to dissect the sac. A circumferential incision was made around the neural placode by saving as much skin as possible. Dura mater was opened by dissecting the skin and the dorsal fascia. The neural placode was placed into the vertebral column, and a watertight dural repair was made using bilateral turnover dorsal thoraco-lumbar fascia flaps (Figure 2). A bovine dura graft for dura repair was used in one patient who had a double-level defect and sac.

After dural repair, soft tissue reconstructions were performed. In every case, the surgical goal was to cover the defect with tension-free soft tissues in order to create durable, reliable soft tissue closure while maintaining robust blood supply. Doppler ultrasonography was not needed and was not used for perforator marking. The flaps were planned so that the two flaps rotated in opposite directions, and their designs were oriented based on the skin reserve vector to enable closure with minimal tension. Incisions were made from the midline. Meticulous dissection and tissue decollation with scissors were performed carefully from the medial to the lateral, and from the distal to the base of the flaps. Superiorly dorsal intercostal perforator vessels and inferiorly lumbar perforators were isolated and protected, especially at the base of the flaps. Approximations of the flaps to the midline were done. In cases which flaps were needed for more mobilization or for back-cut incision, the perforators located at the distal part of the flaps were cut accordingly. The design and mobilization of flaps should be equal for wound tension (Figure 3). Simple interrupted sutures (4/0 poliglecaprone 25, Ethicon, USA) were used for closure (Figure 4, 5).

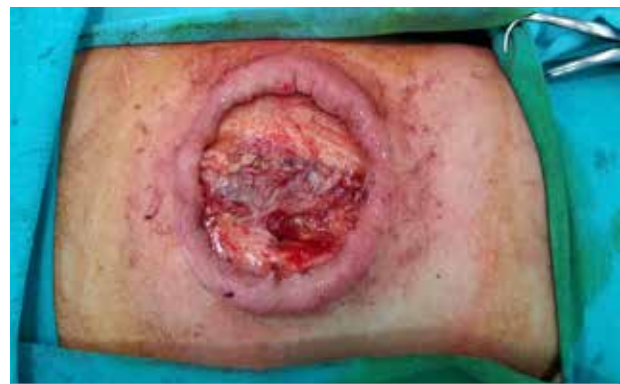### RESULTS

Twelve of the patients were male and 12 were female. One patient had a double-level sac (Figure 6). Eighteen of the sacs were located in the thoracolumbar region, and six were located in the lumbosacral region. Seven cases had an isolated meningocele sac, and two cases had lumbar kyphosis. Other concomitant anomalies are listed in Table I.

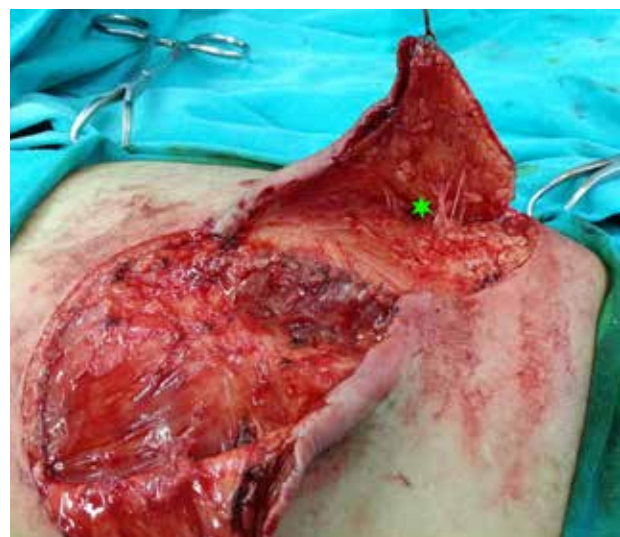
The mean operation time for soft tissue reconstruction was 50 minutes and ranged from 35 to 85 minutes. Intraoperative or postoperative transfusion was not required. The postoperative follow-up period was between eight days



**Figure 1.** Operative position of the lumbar myelomeningocele

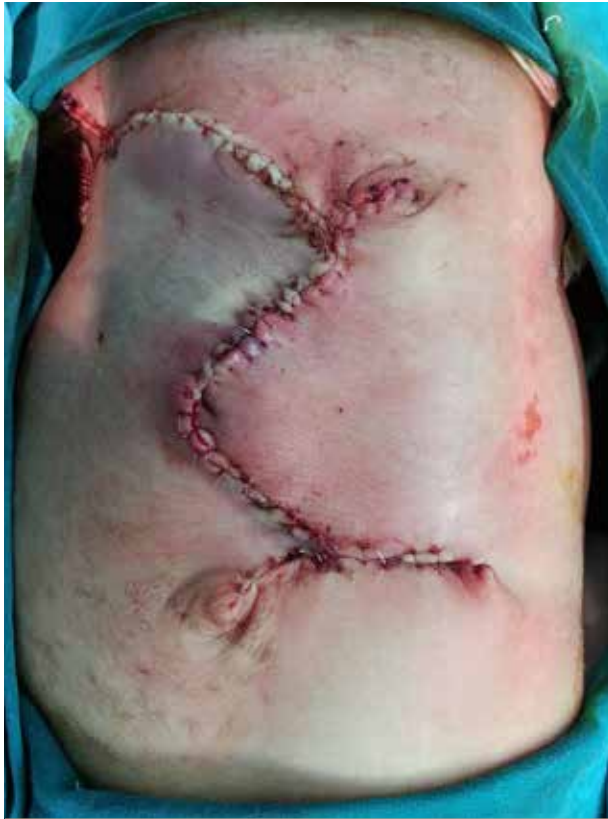

**Figure 2.** The defect after dural repair

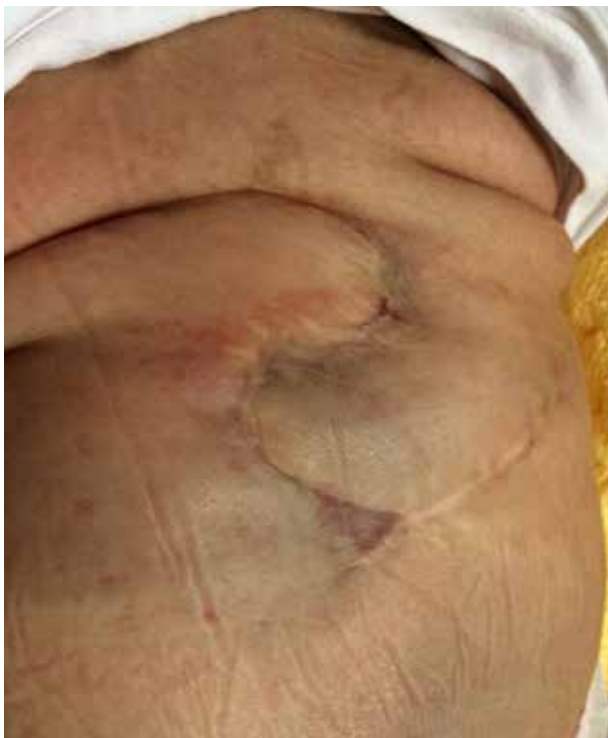

**Figure 3.** Elevated fasciocutaneous flaps. Note that perforators were preserved under the elevated flap (green star)

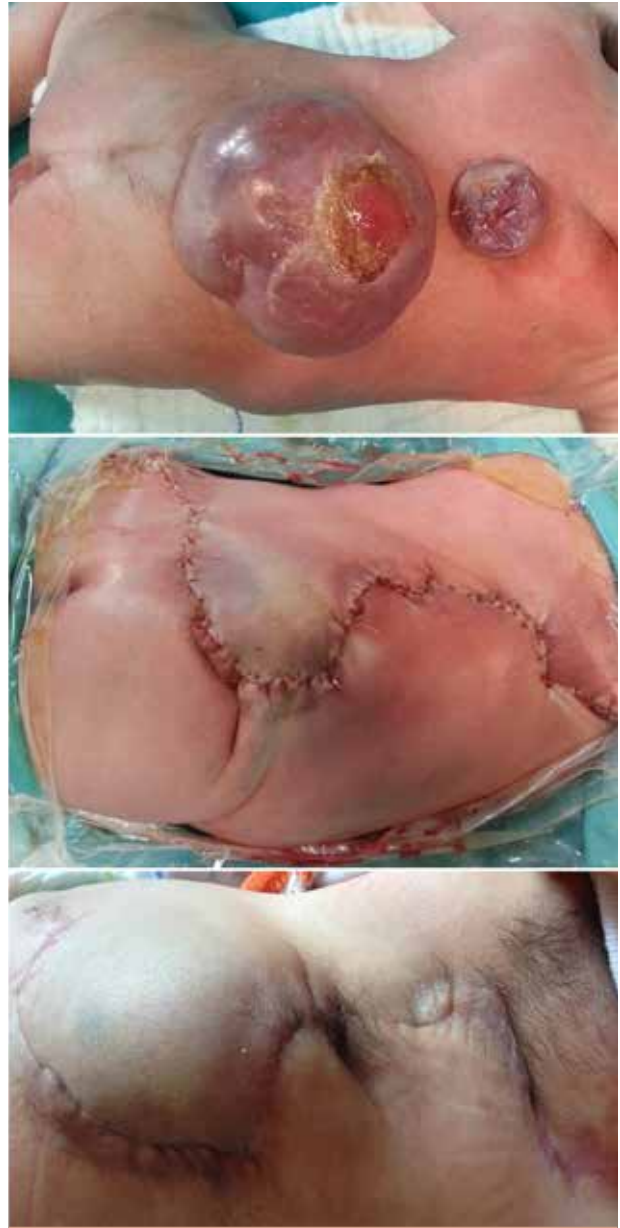and two years with a mean of nine months. Major complications were defined as partial or total flap loss, midline wound dehiscence overlying the neural elements, wound infection leading to meningitis or ventriculitis, and CSF fis-



**Figure 4.** View of the repaired defect at the end of the procedure (although tips of the flaps would be whitened at the end of the procedure, there was no problem during wound healing)



**Figure 5.** Long-term result of the same patient (2 years after surgery)



**Figure 6.** Photographs of the double-level myelomeningocele. Pre-operative view (a), just after the reconstruction was performed (b), and the post-operative 1-year result (c)

**Table II.** Complications and their treatments

Patient	Complication	Treatment
2	Wound dehiscence	Secondary healing
10	Wound dehiscence	Secondary healing
15	CSF leakage from incision	Dural re-repair, Rotation flap
16	Wound dehiscence	Secondary healing
17	Exitus	-
20	Subcutaneous CSF collection	Shunt placement

tula. Minor complication was defined as wound dehiscence that could be healed with wound dressing only. One patient died on the eighth day after surgery because of sepsis related to aspiration pneumonia. One patient had CSF accumulation under the repair zone and was treated by ventriculoperitoneal shunt placement. In another patient, CSF leakage through the repaired incision was observed on the ninth day after surgery. This patient was treated by dural re-repair and ventriculoperitoneal shunt placement. Three patients had minimal wound dehiscence at the distal end of the suture line, and were followed up and healed by secondary intention (Table II).

## DISCUSSION

Neurosurgical principles in repairing MMC are well defined and accepted. These consist of preserving and reducing neural elements to the vertebral column and a four-layer closure that consists of dura, fascia, subcutaneous tissue, and skin.<sup>6</sup> Repairing soft tissue defects immediately after dura closure is critical for the neurological functional outcome, and prevents development of meningitis.<sup>7</sup> McCraw et al.<sup>8</sup> noted that immediate defect repair maximized neurological salvage by preventing both infection and neural desiccation. Most defects can be repaired by primary closure with or without wound edge undermining. On the other hand, approximately 25% of the patients require soft tissue reconstruction.<sup>9,10</sup> There are many options for the reconstruction of large defects, such as skin grafting, local and regional fasciocutaneous flaps, musculocutaneous flaps, and perforator flaps.<sup>6,9-28</sup>

Skin grafting is a simple technique, but does not provide sufficient tissue to protect neural structures. Infections and ulcerations are also seen in the long-term follow up.<sup>11</sup> V-Y advancement flaps are an option, but require advancing the suture line over the dural repair zone. Suture lines overlying the repair zone make CSF leakage and infection more likely.<sup>13,14</sup> A major problem with the musculocutaneous flaps is that important muscles (like the latissimus dorsi) are sacrificed, and such muscles might be essential in paraplegic patients.<sup>8,27</sup> Longer operation time and bleeding are the other problems that should be kept in mind when performing these techniques.<sup>29</sup>

Dorsal intercostal and lumbar perforator flaps, which are based on the rich vascular network of the thoracic and lumbosacral area (supplied by perforator vessels), are used to reconstruct large defects of up to 9 cm x 10 cm.<sup>26,27</sup> The major problems with these flaps are the anatomical variation of their perforator location, as well as the anatomical variation of the vessels' calibration. Also, these perforator flaps are generally designed unilaterally, and this might result in unequal tension distribution at wound sites with the increase of defect size. Reconstruction of defects larger than 9 cm x 10 cm may need skin grafting for flap donor area reconstruction. Additionally, the procedure requires significant experience and specialized surgical equipment.

Therefore bilateral fasciocutaneous transposition flaps are much more preferred in the reconstruction of MMC defects.

The donor sites of these flaps are repaired with skin grafts.<sup>12,30</sup> Cruz used double rhomboid transposition flaps without grafts.<sup>31</sup> Haktanir et al.<sup>32</sup> and Ozcelik et al.<sup>33</sup> used bilateral fasciocutaneous transposition flaps to reconstruct defects of up to 80 cm<sup>2</sup> without any major complications. This is a simple and versatile technique which only requires a correct and appropriate design. The key point is that skin laxity should be taken into account when planning these flaps.

In this study, combining these two ideas, we created and used fasciocutaneous flaps with at least one perforator vessel. For the superior-based flap, the lumbar or dorsal intercostal perforators were preserved, and for the inferior-based flap the gluteal and lumbar perforators were preserved until the full flap dissection was completed for each flap. Following the dissection, both flaps were mobilized to the defect from equal distances. Where flap mobility diminished because of the perforator vessels, the vessels were cut accordingly from distal to proximal until sufficiently mobilized. Most of the perforators were located approximately 5 cm laterally from the vertebral column.<sup>34</sup> This modification assures robust vascular circulation.

This technique has several advantages. (1) Primary closure can easily be performed even in large defects without using a skin graft for the donor site. (2) The surgeon can adjust the flaps (even with back-cut incisions) according to skin laxity. (3) Reconstruction outcome is better than a single flap, which can result in a significant dog ear. (4) Flap tension is distributed equally into two different vectors instead of one. (5) No vertical suture line overlaps the cord closure. (6) Operation time is shorter. (7) Flap circulation is safer than a random-based design.

The disadvantages of this technique are a large and bilaterally incised area, bilaterally sacrificed donor areas, and increased risk of large dead space. Another disadvantage of the technique is the learning curve. It is very easy to perform the procedure, but flap design is somewhat challenging. If the flap is not planned properly, there will be excessive tension at the distal end of the flaps. We did not need Doppler ultrasonography for perforator marking. At least two or more perforators can be found by careful dissection starting from distal-to-proximal and medial-to-lateral of the flaps. We could reconstruct defects up to 150 cm<sup>2</sup>.

In our study, one patient died on the eighth day after surgery because of aspiration pneumonia proven by x-ray on the second day after surgery. One patient had CSF leakage nine days after surgery with a 3-mm skin fistula at the proximal repair zone of the vertebral column. Dural re-repair was performed and a VP shunt was placed, and the repair zone was covered by a rotation and advancement flap. No recurrence was seen. Three patients had minimal wound dehiscence at the distal wound edges with a maximum size of 2 cm after being discharged from the hospital. They were treated with local wound care and healed within two weeks. Wound complications, including CSF leakage, are a significant cause of morbidity in newborns undergoing MMC repair. Prior studies

have reported a rate of CSF leakage after MMC closure in the range of 1-3%.<sup>35,36</sup> The rate of major flap necrosis requiring debridement, soft tissue rearrangement, or skin grafting has been reported to be in the range of 1-8%.<sup>14,35</sup> In our study, there was no partial or complete flap loss. CSF leakage and wound dehiscence rates were seen to be consistent with the literature.

## CONCLUSION

In this study, 24 patients were treated with the described technique by preserving at least one perforator vessel on each side. We think that bilateral perforator-based fasciocutaneous rotation and advancement flaps are the best choice for closing moderate-to-large defects without using a skin graft. With accurate and precise design and a careful surgical technique, fasciocutaneous flaps can easily cover large defects without any flap necrosis.

**Ethics Committee Approval:** Authors declared that the research was conducted according to the principles of the World Medical Association Declaration of Helsinki "Ethical Principles for Medical Research Involving Human Subjects" (amended in October 2013).

**Informed Consent:** Written informed consent was obtained from patients' parents who participated in this study.

**Peer-review:** Externally peer-reviewed.

**Author contributions:** Concept - M.K.E.; Design - M.K.E., H.O.K.; Supervision - M.D., B.İ.; Resource - M.K.E.; Materials M.K.E., M.S., K.Ç.; Data Collection and/or Processing - M.K.E., M.S., K.Ç.; Analysis and/or Interpretation - M.K.E., H.O.K., B.İ.; Literature Search - M.K.E.; Writing Manuscript - M.K.E.; Critical Reviews - M.D.

**Conflict of Interest:** No conflict of interest was declared by the authors.

**Financial Disclosure:** The authors declared that this study has received no financial support.

**Etik Komite Onayı:** Yazarlar çalışmanın World Medical Association Declaration of Helsinki "Ethical Principles for Medical Research Involving Human Subjects" (amended in October 2013) prensiplerine uygun olarak yapıldığını beyan etmişlerdir.

**Hasta Onamı:** Yazılı hasta onamı bu çalışmaya katılan hastanın ailesinden alınmıştır.

**Hakem Değerlendirmesi:** Dış bağımsız.

**Yazar Katkıları:** Fikir - M.K.E.; Tasarım - M.K.E., H.O.K.; Denetleme - M.D., B.İ.; Kaynaklar - M.K.E.; Malzemeler - M.K.E., M.S., K.Ç.; Veri Toplanması ve/veya İşlemesi - M.K.E., M.S., K.Ç.; Analiz ve/veya Yorum - M.K.E., H.O.K., B.İ.; Literatür Taraması - M.K.E.; Yazıyı Yazan - M.K.E.; Eleştirel İnceleme - M.D.

**Çıkar Çatışması:** Yazarlar çıkar çatışması bildirmemişlerdir.

**Finansal Destek:** Yazarlar bu çalışma için finansal destek almadıklarını beyan etmişlerdir.

## REFERENCES

1. Hertzler DA 2nd, DePowell JJ, Stevenson CB, Mangano FT. Tethered cord syndrome: a review of the literature from embryology to adult presentation. *Neurosurgical Focus* 2010; 29(1): E1. [CrossRef]
2. Zambelli H, Carelli E, Honorato D, Marba S, Coelho G, Carnevalle A, et al. Assessment of neurosurgical outcome in children prenatally diagnosed with myelomeningocele and development of a protocol for fetal surgery to prevent hydrocephalus. *Childs Nerv Syst* 2007; 23(4): 421-5. [CrossRef]
3. El-khatib HA. Large thoracolumbar meningomyelocele defects: incidence and clinical experiences with different modalities of latissimus dorsi musculocutaneous flap. *Br J Plast Surg* 2004; 57(5): 411-7. [CrossRef]
4. Cheek WR, Laurent JP, Cech DA. Operative repair of lumbosacral myelomeningocele. Technical note. *J Neurosurg* 1983; 59(4): 718-22. [CrossRef]
5. Lien SC, Maher CO, Garton HJ, Kasten SJ, Muraszko KM, Buchman SR. Local and regional flap closure in myelomeningocele repair: a 15-year review. *Childs Nerv Syst* 2010; 26(8): 1091-5. [CrossRef]
6. Patterson TJ. The use of rotation flaps following excision of lumbar myelo-meningoceles: an aid to the closure of large defects. *Br J Surg* 1959; 46: 606-8. [CrossRef]
7. Cohen AR RS. Early management of myelomeningocele. In: McLone DG, editor. *Pediatric Neurosurgery*. Philadelphia: Saunders; 2001.p.241-59.
8. McCraw JB, Penix JO, Freeman BG, Vincent MP, Wirth FH. Soft-tissue repair of myelomeningocele defects using bilateral latissimus dorsi and trapezius musculocutaneous flaps. *Ann Plast Surg* 1987; 18(2): 147-55. [CrossRef]
9. Davies D, Adendorff DJ. A large rotation flap raised across the midline to close lumbo-sacral meningomyeloceles. *Br J Plast Surg* 1977; 30(2): 166-8. [CrossRef]
10. Ulusoy MG, Kocer U, Sungur N, Karaaslan O, Kankaya Y, Ozdemir R, et al. Closure of meningomyelocele defects with bilateral modified V-Y advancement flaps. *Ann Plast Surg* 2005; 54(6): 640-4. [CrossRef]
11. Luce EA, Walsh J. Wound closure of the myelomeningocele defect. *Plast Reconstr Surg* 1985; 75(3): 389-93. [CrossRef]
12. Bajaj PS, Welsh F, Shadid EA. Versatility of lumbar transposition flaps in the closure of meningomyelocele skin defects. *Ann Plast Surg* 1979; 2(2): 103-8. [CrossRef]
13. Lapid O, Rosenberg L, Cohen A. Meningomyelocele reconstruction with bilobed flaps. *Br J Plast Surg* 2001; 54(7): 570-2. [CrossRef]
14. Campobasso P, Pesce C, Costa L, Cimaglia ML. The use of the Limberg skin flap for closure of large lumbosacral myelomeningoceles. *Pediatr Surg Int* 2004; 20(2): 144-7. [CrossRef]
15. Ohtsuka H, Shioya N, Yada K. Modified Limberg flap for lumbosacral meningomyelocele defects. *Ann Plast Surg* 1979; 3(2): 114-7. [CrossRef]
16. Komuro Y, Yanai A, Koga Y, Seno H, Inoue M. Bilateral modified V-Y advancement flaps for closing meningomyelocele defects. *Ann Plast Surg* 2006; 57(2): 195-8. [CrossRef]
17. Mutaf M, Bekerecioglu M, Erkutlu I, Bulut O. A new technique for closure of large meningomyelocele defects. *Ann Plast Surg* 2007; 59(5): 538-43. [CrossRef]
18. Desprez JD, Kiehn CL, Eckstein W. Closure of large meningomyelocele defects by composite skin-muscle flaps. *Plast Reconstr Surg* 1971; 47(3): 234-8. [CrossRef]
19. Ramirez OM, Ramasastry SS, Granick MS, Pang D, Futrell JW. A new surgical approach to closure of large lumbosacral meningomyelocele defects. *Plast Reconstr Surg* 1987; 80(6): 799-809. [CrossRef]
20. Schefflan M, Mehrhof AI, Jr., Ward JD. Meningomyelocele closure with distally based latissimus dorsi flap. *Plast Reconstr Surg* 1984; 73(6): 956-9. [CrossRef]

21. Hayashi A, Maruyama Y. Bilateral latissimus dorsi V-Y musculocutaneous flap for closure of a large meningomyelocele. *Plast Reconstr Surg* 1991; 88(3): 520-3. [\[CrossRef\]](#)
22. VanderKolk CA, Adson MH, Stevenson TR. The reverse latissimus dorsi muscle flap for closure of meningomyelocele. *Plast Reconstr Surg* 1988; 81(3): 454-6. [\[CrossRef\]](#)
23. Moore TS, Dreyer TM, Bevin AG. Closure of large spina bifida cystica defects with bilateral bipediced musculocutaneous flaps. *Plast Reconstr Surg* 1984; 73(2): 288-92. [\[CrossRef\]](#)
24. Gutman MJ, Goldschlager T, Fahardieh RD, Ying D, Xenos C, Danks RA. Keystone design perforator island flap for closure of myelomeningocele. *Childs Nerv Syst* 2011; 27(9): 1459-63. [\[CrossRef\]](#)
25. Kato H, Hasegawa M, Takada T, Torii S. The lumbar artery perforator based island flap: anatomical study and case reports. *Br J Plast Surg* 1999; 52(7): 541-6. [\[CrossRef\]](#)
26. El-Sabbagh AH, Zidan AS. Closure of large myelomeningocele by lumbar artery perforator flaps. *J Reconstr Microsurg* 2011; 27(5): 287-94. [\[CrossRef\]](#)
27. Isik D, Tekes L, Esegolu M, Isik Y, Bilici S, Atik B. Closure of large myelomeningocele defects using dorsal intercostal artery perforator flap. *Ann Plast Surg* 2011; 67(2): 159-63. [\[CrossRef\]](#)
28. de Weerd L, Weum S. The butterfly design: coverage of a large sacral defect with two pedicled lumbar artery perforator flaps. *Br J Plast Surg* 2002; 55(3): 251-3. [\[CrossRef\]](#)
29. Mutaf M, Temel M, Gunal E. The reading man flap for closure of large meningomyelocele defects. *J Plast Reconstr Aesthet Surg* 2012; 65(5): 578-83. [\[CrossRef\]](#)
30. Iacobucci JJ, Marks MW, Argenta LC. Anatomic studies and clinical experience with fasciocutaneous flap closure of large myelomeningoceles. *Plast Reconstr Surg* 1996; 97(7): 1400-8; discussion 1409-1410. [\[CrossRef\]](#)
31. Cruz NI, Ariyan S, Duncan CC, Cuono CB. Repair of lumbosacral myelomeningoceles with double Z-rhomboid flaps. Technical note. *J Neurosurg* 1983; 59(4): 714-17. [\[CrossRef\]](#)
32. Haktanir TN, Eser O, Demir Y, Aslan A, Koken R, Melek H. Repair of wide myelomeningocele defects with the bilateral fasciocutaneous flap method. *Turk Neurosurg* 2008; 18(3): 311-5.
33. Ozcelik D, Yildiz KH, Is M, Dosoglu M. Soft tissue closure and plastic surgical aspects of large dorsal myelomeningocele defects (review of techniques). *Neurosurg Rev* 2005; 28(3): 218-25. [\[CrossRef\]](#)
34. Minabe T, Harii K. Dorsal intercostal artery perforator flap: anatomical study and clinical applications. *Plast Reconstr Surg* 2007; 120(3): 681-9. [\[CrossRef\]](#)
35. Lanigan MW. Surgical repair of myelomeningocele. *Ann Plast Surg* 1993; 31(6): 514-21. [\[CrossRef\]](#)
36. Talamonti G, D'Aliberti G, Collice M. Myelomeningocele: long-term neurosurgical treatment and follow-up in 202 patients. *J Neurosurg* 2007; 107(5 Suppl): 368-86. [\[CrossRef\]](#)