



# Effects of modified step Le Fort I advancement surgery on nostril area and inferior nasal structures volume in class III patients: a retrospective clinical study

Nihat Akbulut<sup>1</sup> · Sibel Akbulut<sup>2</sup> · Seval Bayrak<sup>3</sup> · Esengül Şen<sup>4</sup> · Ahmet Altan<sup>5</sup> · Gizemnur Kaymaz<sup>4</sup> · Sefa Çolak<sup>4</sup>

Received: 7 February 2022 / Accepted: 28 December 2022 / Published online: 17 January 2023  
© The Author(s), under exclusive licence to Springer-Verlag GmbH Germany, part of Springer Nature 2023

## Abstract

**Objective** The effect of the modified step Le Fort I osteotomy on the inferior nasal structures and the nostril area was evaluated.

**Materials and methods** This study included 24 patients who had modified step Le Fort I osteotomy. Inferior nasal concha volume (INCV), meatus nasi inferior volume (MNIV), the sum of both structures volume (TV), and nostril area (NA) were evaluated in pre- (T0) and postoperative (T1) periods.

**Results** For all patients, NA increased both on the right side ( $p = 0.011$ ) and left side ( $p = 0.050$ ) after surgery. The INCV and TV values were lower in T1 than those in T0; however, a statistically significant decrease of INCV and TV was found only in the right side of males ( $p = 0.039$  and  $p = 0.050$ , respectively). No significant difference was found in MNIV between T0 and T1 measurements ( $p > 0.05$ ).

**Conclusion** Maxillary advancement with the modified step Le Fort I osteotomy technique increased the NA, which may have a positive effect on breathing function. On the other hand, although TV tended to decrease, MNIV did not change after surgery as the same decreasing tendency also existed in INCV.

**Clinical relevance** Step Le Fort I advancement surgery technique usually affects nasal structures positively regarding the nasal airway.

**Keywords:** Nasal cavity · Nasal concha · Nasal airway obstruction · LeFort osteotomy · Orthognathic surgical procedures

## Introduction

Dentofacial deformities occur due to hereditary disorders and acquired or environmental causes [1]. In the course of the appropriate time of the patient's life, these deformities should be treated in orthodontics or surgery-assisted orthodontics named orthognathic surgeries [2]. Orthognathic surgeries are usually carried out as single jaw or bimaxillary, and bilateral sagittal split ramus osteotomies for mandibular deformities, Le Fort I, and its modifications for maxillary deformities are used [3].

Classic Le Fort I and modifications such as high, step, modified step, and quadrangular Le Fort I surgery have been used in mid-facial dentofacial deformity corrections [2]. Modified step Le Fort I osteotomy technique has been used by various authors up to days [4, 5]. Step osteotomy has some advantages including not to auto-rotate the mandible superiorly and anteriorly, and not further repositioning [6]. Moreover, the other important advantage of the step

✉ Seval Bayrak  
dtseval@hotmail.com

<sup>1</sup> Oral and Maxillofacial Surgery Department, Dentistry Faculty, Ondokuz Mayıs University, Samsun, Turkey

<sup>2</sup> Orthodontics Department, Dentistry Faculty, Ondokuz Mayıs University, Samsun, Turkey

<sup>3</sup> Oral and Maxillofacial Radiology Department, Dentistry Faculty, Bolu Abant İzzet Baysal University, Golkoy, Bolu, Turkey

<sup>4</sup> Oral and Maxillofacial Surgery Department, Dentistry Faculty, Tokat Gaziosmanpaşa University, Tokat, Turkey

<sup>5</sup> Oral and Maxillofacial Surgery Department, Dentistry Faculty, Necmettin Erbakan University, Konya, Turkey

osteotomy is that it supports the tip of the nose much more than the classical Le Fort I [4]. Izgi et al. [4] reported soft to hard tissue ratios of the nose tip between 42% and 49% with modified step osteotomy, while the same ratios were reported between 16 and 35% in classical Le Fort I cases [3, 7–9].

Nasal size, shape, and proportions can be affected by age, sex, and ethnicity [10, 11]. Sforza et al. [11] reported that nasal volume, area, and linear distances increased while nasal tip angle decreased from childhood to old age. Also, the Le Fort I surgery technique influences the nasal shape and function along with the facial appearance [3, 4, 12–26]. Some nasal effects like increased nasolabial angle, upward and forward movement of the nasal tip, increased alar base width, and widened nostrils were reported after maxillary advancement surgery [21]. Furthermore, airway volumes are reported to be affected after orthognathic surgery, which may be of clinical significance, especially in patients who are predisposed to obstructive sleep apnea [27].

The effects of Le Fort I surgery on nasal structures and shape were evaluated in terms of function and airway flow resistance, and esthetic aspect by various tests and techniques. Nigro et al. [28] reported the Cottle test, nasal endoscopy, and anterior rhinoscopy as subjective, and CT scans, MRI investigation, and speaking and acoustic rhinomanometry as more objective methods in the nasal shape and passage evaluation. Mirmohamadsadeghi et al. [20] used rhinometry and acoustic rhinometry tools; Worasakwutiphong et al. [25] used a novel three-dimensional photographic imaging technique; Bohluli et al. [29] used the External Nasal Valve Efficacy Index to calculate the external nasal valve, including the nostril, anterior portion of INC, and septum nasi; Atakan et al. [14], Dantas et al. [15], and Izgi et al. [4] used conventional imaging methods such as posteroanterior and lateral cephalometric radiographs; Yamashita et al. [26], El-Anwar et al. [30], Jeong et al. [17], Fastuca et al. [31], and Allar et al. [12] used CBCT or CT tools in their nasal shape and structure evaluations of the orthognathic cases.

Besides the nasal effects of orthognathic surgery, there are many complications, if it is carried out bimaxillary as well, such as relapse of the planned movements of jaws, infection, loss of tooth vitality, vascular problems, a bad split of related bones, malunion of osteotomy lines, recovery or revealing of TMD attributed to orthognathic surgery, bone necrosis, and paraesthesia as other neurologic changes [32]. In terms of these problems, the patients must be followed up regularly by using physical control, if it is not possible, at least the teledentistry method should be used [33].

The purpose of the present study was to evaluate the changes in nasal structures such as nostril area, the volume of inferior nasal concha and meatus nasi inferior, and the total volume of both structures after modified step Le Fort I surgery by using CT and CBCT scans.

## Materials and methods

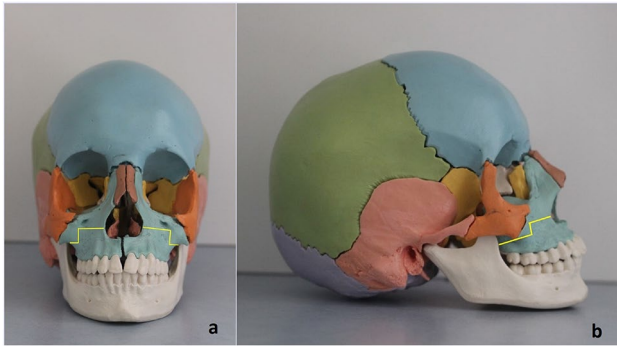
A power analysis was performed using G\*Power Software version 3.1.9.2 (Universität Düsseldorf, Germany). A minimum sample size of 5 subjects was calculated to give 80% power to detect significant differences at a significance level of 0.05, considering the meatus nasi inferior area [20]. The Institutional Review Board and Clinical Ethics committee of Tokat Gaziosmanpasa University Medicine Faculty approved this retrospective clinical study, which was conducted according to the principle and revisions of the Helsinki Declaration.

The study was conducted on patients who had orthognathic surgery between 2013 and 2019, in the Dentistry Faculty of Tokat Gaziosmanpasa University. Skeletal class III patients who had bimaxillary or just maxillary surgery, but had modified step Le Fort I osteotomy, including only maxillary advancement movement were recruited. The patients who had CT or CBCT records just before and at least 6 months after surgery were included in the study. Besides, the patients who had an operation history in the nasal region, nasal cavity walls that had been affected by cysts, tumors, and surrounding structure's pathologies, and whose area to be examined cannot be seen due to artifact or insufficient image that could not cover the whole nasal region, were excluded.

All included patients had orthodontic treatment before the orthognathic surgery. All patients had been consulted to the Ear, Nose, and Throat (ENT) clinic of the same university hospital before the orthognathic surgeries due to possible nasal pathologies. Following the ENT clinic approval, which means there has not been any nasal pathology, the patients had surgery.

### Modified step Le Fort 1 osteotomy technique

Modified step Le Fort I osteotomies, including inferior horizontal line (IHL) under the zygomatic buttress and superior horizontal line (SHL) at just the base of the pyriform aperture, have originated from the study of Bennett and Wolford [6]; however, we have used modified step Le Fort I osteotomy much like the study of Catherine and Scolozzi [5]. The present study's technique differencing about the SHL at the lateral piriformis level was at least 5–10 mm above the nasal base and just inferior to the concha nasalis inferior (Fig. 1). In detail, routine mucoperiosteal elevation in both sides of the maxilla including the nasal mucosa until the hard and soft palate junction, anterior nasal spine, nasal pyriform aperture, anterior maxillary lateral wall, zygomaticomaxillary buttress, and pterygomaxillary junction region was performed. Following the whole mucoperiosteal elevation, the osteotomies were



**Fig. 1** Modified step Le Fort I osteotomy line diagram, **a** frontal view, **b** profile view

carried out at the lateral wall of the maxilla in both SHL and IHL until the pterygomaxillary junction by using the piezosurgery technique. The osteotomies of the lateral nasal walls, nasal septum, and pterygomaxillary junctions on both sides were performed by the suitable osteotomes. Down fracture of the maxilla was firstly done by using digital pressure to the anterior portion of the maxilla and complete mobilization of it was also done by using a hook and other mobilizers such as Rowe and Tessier spreading forceps. Then, maxilla-mandibular fixation (MMF) was done by orthodontics prepared splint, and the internal rigid fixation was performed with 4-hole, 2-mm L-plates, at the paranasal step, and the zygomatic buttress inferior step, respectively. To achieve good esthetic, the cinch suture in the alar base region with 2.0 PDS suture, V-Y advancement closure at the lip with 4.0, and the rest of the vestibular closure with 3.0 resorbable sutures were done. If these class III dentofacial deformity cases include bimaxillary intervention in their orthognathic planning, the classic bilateral sagittal split ramus osteotomies were done as well. All surgical procedures were performed by the same experienced oral and maxillofacial surgeon (NA). In addition, the team participating in the operations consisted of the same surgeons (AA and ES).

### Radiologic procedures and nasal structures related measurements

Depending on their referral center of orthodontics, some patients had traditional CT and others had CBCT images, just before for orthognathic surgery planning and at least 6

months after for controlling. Pre-treatment (T0) and post-treatment (T1) images were obtained with the same device and with the same parameters. In addition, since CT and CBCT clearly show the correct dimensions and boundaries of the examined objects in three dimensions in all three planes, without distortion and magnification, the real-size measurements could be achieved in the images obtained with both devices [34, 35].

CT images were obtained via GE Optima CT 660 (GE Medical Systems, USA) with 70 mA, 120 kVp, and 256 × 256 matrix. On the other hand, CBCT images were acquired with Galileos (Sirona Dental System, Bensheim, Germany) unit at 15 × 15 mm Field of View, 98 kVp, 15–30 mA, 0.25 mm<sup>3</sup> voxel size, 2–5-s radiation, and 14-s scanning periods.

DICOM files of the CT and CBCT images were transferred to the 3D-DOCTOR (3D-DOCTOR Able Software Corp., Lexington, KY) software. Volume calculations were performed by using the Cavalieri Principle which is a stereological method. The outer boundaries of the region of interest were drawn manually on each radiographic section. The program automatically gave the total volume of ROI by multiplying the total area with section thickness by using the planimetry method.

Inferior nasal structure volumes (mm<sup>3</sup>) including inferior nasal concha volume (INCV), meatus nasi inferior volume (MNIV), and total volume (INCV + MNIV, TV), and the nostril area (NA, mm<sup>2</sup>) was measured on the CT and CBCT images by using related software mentioned detail below.

### INCV measurements

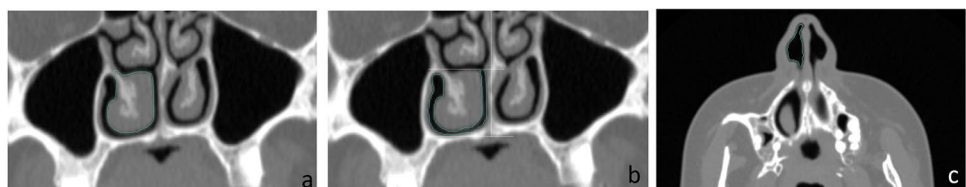INCV was calculated on the coronal plane on consecutive sections with a thickness of 1 mm without the interval. The borders were drawn manually on all sections where INC was seen (Fig. 2a), and the software automatically calculated the INCV.

This volume calculation procedure was repeated and recorded for the right and left inferior nasal concha T0 and T1 images.

### MNIV measurements

A line parallel to the floor of the nasal cavity and perpendicular to the nasal septum and sagittal plane was drawn at the highest level of the superior border of the INC. The

**Fig. 2** Green lines demonstrate boundaries of the inferior nasal concha (**a**), meatus nasi inferior (**b**), and nostril (**c**) on the right side determined by the planimetry method on 3D-Doctor Program



boundaries of the air space in the area below this line were drawn manually (Fig. 2b). MNIV was calculated by the software automatically after this process was repeated in all sections where INC was seen. This procedure was performed on the right and left sides to calculate the MNIV on T0 and T1 images and recorded.

### TV measurements

The sum of the MNIV and INCV was recorded as the nasal cavity or total volume (TV) for the right and left sides.

### Nostril area measurements

The border of the nostril was drawn manually in the axial images where it appears widest and completely visible and the area was calculated by the software automatically (Fig. 2c). The area of the nostril was calculated and recorded for T0 and T1 images on both left and right sides.

The measurements were carried out by a maxillofacial radiologist and the measurements were repeated 2 weeks later in 15 randomly selected images to test the intra-observer reliability.

### Statistical analysis

IBM SPSS (Statistical Package for the Social Sciences, version 20.0, IBM Corp, Armonk, NY, USA) software was used for statistical calculation. The descriptive statistics belonging to obtained data were calculated as a mean  $\pm$  standard deviation, count, and frequencies. The normality of variables was examined by the Shapiro-Wilk test. Because of obtaining normal distributions of the data, paired sample *t*-test was used in the comparison between T0 and T1 measurements. The effects of sex (male, M; female, F) and advancement amount on the measured parameters were investigated by the sample *t*-test. The paired Student's *t*-test was used to assess the method error. The statistical significance level was considered as  $p < 0.05$ .

### Results

Twenty-four patients (13 female, 11 male) with a mean age of  $21.1 \pm 4.8$  years were included in the study. Four of them had only maxillary advancement, and 20 of them had maxillary advancement and mandibular setback surgery. Intraoperatively and postoperatively, there was not any encountered complication by the patients and regular follow-up period going on. The intra-observer analysis showed no statistically significant differences ( $p > 0.05$ ).

The comparison between T0 and T1 measurements for each parameter (INCV, MNIV, NA, and TV) on the left

and right sides were given in Table 1. The NA values were higher at T1 than those at T0 both on the right and left sides ( $p = 0.01$  and  $p = 0.05$ , respectively). No significant difference was found between T0 and T1 regarding INCV, MNIV, and TV parameters both on the right and left sides ( $p > 0.05$ ) (Table 1).

The comparison between right and left side measurements were compared separately in T0 and T1, and the results were given in Table 2. The INCV values of the right side were higher and the MNIV values of the right side were lower than those on the left side at T0 ( $p = 0.045$  and  $p = 0.049$ , respectively). On the other hand, there was no statistically significant difference between the right and left sides at T1, regarding all measured parameters ( $p > 0.05$ ) (Table 2).

The mean maxillary advancement amount was  $5.75 \pm 1.51$  mm. The classification was made considering the amount of maxillary advancement, and the patients who had  $\leq 5$  mm advancement surgery were assigned to the lower advancement group (LA) and  $> 5$  mm were assigned to the higher advancement group (HA). The number of patients in the LA group was 11, and it was 13 in the HA group. The comparison of the INCV, MNIV, TV, and NA changes (T1–T0) between LA and MA groups was given in Table 3. No significant difference was found between the LA and HA groups for all parameters ( $p > 0.05$ ) (Table 3).

Comparison between the T0 and T1 measurements separately in female and male patients were given in Table 4. The NA measurements of both the right and left sides in females were found to be increased from T0 to T1 ( $p = 0.034$  and  $p$

**Table 1** Comparison of the measurements between T0 and T1 time points

	Side		Mean	SD	p
INCV (mm <sup>3</sup> )	Right	T0	5361.7	1645.6	0.147
		T1	4947.2	1323.3	
	Left	T0	4711.4	1698.4	0.519
		T1	4452.9	1538.3	
MNIV (mm <sup>3</sup> )	Right	T0	3028.6	744.6	0.852
		T1	3089.8	833.0	
	Left	T0	3452.3	1009.4	0.877
		T1	3492.4	1345.4	
TV (mm <sup>3</sup> )	Right	T0	8420.2	1866.0	0.159
		T1	8037.1	1415.8	
	Left	T0	8163.8	1928.7	0.398
		T1	7855.3	1778.5	
NA (mm <sup>2</sup> )	Right	T0	204.3	51.4	0.011*
		T1	235.0	77.9	
	Left	T0	194.5	49.5	0.050*
		T1	229.5	99.4	

INCV, inferior nasal concha volume; MNIV, meatus nasi inferior volume; TV, total volume; NA, nostril area; SD, standard deviation; \*statistically significant

**Table 2** Comparison of the measurements between the right and left sides

		Side	Mean	SD	p
INCV (mm <sup>3</sup> )	T0	Right	5361.7	1645.6	0.045*
		Left	4711.4	1698.4	
	T1	Right	4947.2	1323.3	0.233
		Left	4452.9	1538.3	
MNIV (mm <sup>3</sup> )	T0	Right	3058.5	744.6	0.049*
		Left	3452.8	1009.4	
	T1	Right	3089.8	833.0	0.220
		Left	3402.4	1345.4	
TV (mm <sup>3</sup> )	T0	Right	8420.2	1866.0	0.124
		Left	8163.8	1928.7	
	T1	Right	8037.1	1415.8	0.754
		Left	7855.3	1778.5	
NA (mm <sup>2</sup> )	T0	Right	204.3	51.4	0.481
		Left	194.5	49.5	
	T1	Right	235.0	77.9	0.582
		Left	229.5	99.4	

INCV, inferior nasal concha volume; MINV, meatus nasi inferior volume; TV, total volume; NA, nostril area; SD, standard deviation; \*statistically significant

= 0.007, respectively). The INCV and TV measurements on the right side of males were found to be decreased from T0 to T1 ( $p = 0.039$  and  $p = 0.050$ , respectively). Other than the above, there was not any statistically significant difference (Table 4).

**Table 3** Comparison of the treatment outcomes (T1–T0) between the groups LA and HA

	T1–T0 difference	Groups	n	Mean	SD	p
INCV (mm <sup>3</sup> )	Right	LA	11	– 708.78	1360.90	0.338
		HA	13	– 165.33	1350.70	
	Left	LA	11	– 412.53	1786.14	0.728
		HA	13	– 128.24	2117.14	
MINV (mm <sup>3</sup> )	Right	LA	11	1.36	960.09	0.872
		HA	13	56.49	693.70	
	Left	LA	11	– 364.48	1501.82	0.377
		HA	13	216.19	1630.08	
TV (mm <sup>3</sup> )	Right	LA	11	– 707.42	1001.47	0.267
		HA	13	– 108.81	1476.35	
	Left	LA	11	– 777.01	1534.50	0.237
		HA	13	87.96	1889.67	
NA (mm <sup>2</sup> )	Right	LA	11	12.32	13.86	0.113
		HA	13	46.37	70.68	
	Left	LA	11	19.30	33.18	0.417
		HA	13	48.27	111.74	

LA, lower amounts of advancement; HA, higher amounts of advancement; INCV, inferior nasal concha volume; MINV, meatus nasi inferior volume; TV, total volume; NA, nostril area; n, noun; SD, standard deviation

The treatment outcomes (T1–T0) between female and male patients were statistically compared as well. No significant difference was found between the treatment outcomes of male and female patients ( $p > 0.05$ ).

### Discussion

Le Fort I or its modifications and bilateral sagittal split ramus osteotomy have been used reliably as a single or double jaw surgery for skeletal class III patients for many years [3, 21]. In this study, without any intraoperative and post-operative follow-up period complications, only four patients had modified Le Fort I advancement surgery, and the rest of the patients ( $n = 20$ ) underwent bimaxillary surgery.

Le Fort I or modified osteotomy is a surgery technique to correct maxillary or midface deformity that affects the nasal shape and functions [14]. For evaluation of the nasal function and/or shape, the Cottle test, nasal endoscopy, and anterior rhinoscopy were reported as subjective, while CT scans, MRI investigation, speaking, and acoustic rhinomanometry were suggested as the more objective methods [28]. Therefore, to evaluate the nasal airway function in the present study, CT and CBCT images and the related software (3D-DOCTOR Able Software Corp., Lexington, KY, USA), one of the objective methods, were used for measuring NA, INCV, MNIV, and TV.

NA is the exterior entrance of the nasal cavity, and it is named the external nasal valve [13, 18, 20, 28]. The nasal tip elevation and nasal rim width were analyzed in

**Table 4** Comparison of the measurements between the T0 and T1 time points separately in female and male patients

Sex		Side		n	Mean	SD	<i>p</i>			
Female	INCV (mm <sup>3</sup> )	Right	T0	13	4904.6	1208.2	0.589			
			T1	13	4643.2	1240.9				
		Left	T0	13	4603.2	1681.7	0.999			
			T1	13	4603.5	1405.2				
		MNIV (mm <sup>3</sup> )	Right	T0	13	3016.2	777.4	0.705		
				T1	13	3121.1	919.6			
	Left		T0	13	3281.5	979.3	0.911			
			T1	13	3228.4	1247.7				
	TV (mm <sup>3</sup> )	Right	T0	13	7920.8	1536.0	0.715			
			T1	13	7764.4	1294.9				
		Left	T0	13	7884.7	1907.8	0.923			
			T1	13	7832.0	1564.2				
	NA (mm <sup>2</sup> )	Right	T0	13	206.5	39.3	0.034*			
			T1	13	226.3	43.7				
		Left	T0	13	190.7	47.3	0.007*			
			T1	13	221.7	49.4				
			Male	Right	T0	11		5901.8	1970.8	0.039*
					T1	11		5306.5	1384.8	
Left	T0	11	4839.3	1790.9	0.337					
	T1	11	4274.8	1734.7						
MNIV (mm <sup>3</sup> )	Right	T0	11	3108.6	738.2	0.757				
		T1	11	3052.7	760.5					
	Left	T0	11	3654.3	1053.5	0.920				
		T1	11	3608.1	1486.4					
TV (mm <sup>3</sup> )	Right	T0	11	9010.0	2114.2	0.050*				
		T1	11	8359.3	1545.0					
	Left	T0	11	8493.7	1991.8	0.229				
		T1	11	7882.9	2082.6					
NA (mm <sup>2</sup> )	Right	T0	11	201.6	64.8	0.078				
		T1	11	245.3	107.0					
	Left	T0	11	199.0	53.9	0.309				
		T1	11	238.7	140.1					

INCV, inferior nasal concha volume; MINV, meatus nasi inferior volume; TV, total volume; NA, nostril area; *n*, noun; SD, standard deviation; \*statistically significant

the literature, and it was suggested that if the nasal tip is elevated or especially the nasal rim width is enlarged, the NA increases [14, 15, 25, 26, 36]. To control nasal alar base or rim widening, the cinching suture and V-Y closure were used in the present study; nevertheless, both the right and left NA values were found to be increased. The reason for the increase in the NA may be the effect of maxillary advancement with the step osteotomy technique used in the present study. Izgi et al. [4] stated that the modified step technique more supports the nasal tip which may cause the NA increase in line with the present study. Park et al. [21] reported that Le Fort I surgery with advancement and impaction process caused nostril area and nasal width increase, and Ledezma-Khamashta et al. [18] reported that maxillary advancement decreased the nasal airway

resistance due to the widening of the external nasal valve and opening of the internal valve, in line with the present study. Mirmohamadsadeghi et al. [20] reported that maxillary advancement and impaction of the maxilla increased the nasal valve, which matches with the NA enlargement in the present study. Moreover, Worasakwutiphong et al. [25] reported that two-jaw surgery increased the nostril appearance; however, they moved the maxilla in a clockwise rotation different from the present study.

The other important finding of the present study was that while TV and INCV tended to decrease, MNIV did not change significantly after surgery. The reason for this result may be that despite the tendency of the nasal airway to increase with advancement, a significant increase in MNIV could not be seen postoperatively due to the decrease in TV.

Mirmohamadsadeghi et al. [20] measured the anterior portion of the inferior nasal concha area and anterior portion of the isthmus (like inferior nasal concha and meatus nasi inferior volume in the present study) in their maxillary superior repositioning Le Fort I cases. In line with our results, they found a decrease in the inferior nasal concha area, while the isthmus area was not decreased in their cases with impaction < 6.5 mm. Erbe et al. [16] reported the intranasal dimension diminished after maxillary advancement and impaction (< 5 mm) surgery, similar to the decrease of TV in the present study. In contrast, Pourdanesh et al. [22] reported that the total cross-sectional diameter of the inferior nasal concha did not show any remarkable changes, and the total cross-sectional diameter of the isthmus nasi increased significantly. On the other hand, Almuzian et al. [37] found that inferior nasal space got narrowed after advancement and impaction of the maxilla, and they indicated the impaction as the reason and commented that only maxillary advancement increases the inferior nasal space.

Regarding the comparison of the right and left side measurements, the INCV values of the right side and the MNIV values of the left side were higher than the counterpart side at T0. On the other hand, there was no statistically significant difference in the comparisons of the INCV and MNIV values between the right and left sides at T1, which means that step Le Fort I advancement surgery caused a decrease of INCV in both sides, and this decrease in the right side was much than the other side. So, MNIV became equal on both sides after surgery.

The effect of maxillary advancement amount on inferior nasal structures was also examined. However, it was not encountered a significant difference in the efficiency of treatment between the groups created according to the advancement amounts. As a limitation, the small sample size may be the reason for this result. Besides, compatible with the current results, Erbe et al. [16] reported that after Le Fort I osteotomy, there was no remarkable change in nasal function regardless of the advancement or impaction amount. Contrarily, Dantas et al. [15] reported that there were modifications in the nasal tip, nasal width increase, and upward nasal rotation, according to the amount of maxillary advancement and anterior or posterior impaction. Khamashta-Ledezma et al. [18] and Schendel and Carlotti [23] also stated on the amount of maxillary advancement that if the alar base widening was not desired, the maxillary surgery or the excessive movement of the maxilla should have not been the choice.

The last important findings are as follows: the NA measurements were found to be increased in females, while the increase was not significant in males. Also, the INCV and TV values on the right side were found to be decreased in males, while it was not the case for females. It means that the NA, INCV, and TV parameters give different responses to the modified step Le Fort I surgical movement according to sex. Schendel

and Carlotti [23] suggested being careful about advancing the maxilla in patients having small noses relative to their faces, especially in a male patient in whom the augmentation was not been planned. This suggestion is compatible with our results since the TV of the males was found to be decreased in the present study. However, when we compared the treatment efficiency between the sexes, no significant difference was found. In line with this result, Mirmohamadsadeghi et al. [20] reported in their advancement and impaction cases that there was no difference between female and male cases in terms of INC and MNI area, and airway resistance.

There have been some limitations of the present study as small sample size, no existence of a conventional Le Fort I osteotomy group to compare, and the retrospective character of the research instead of prospective. In addition, in the presented study, the second radiological scans were taken 6 months after surgery. Although the mentioned period is short, the age-related changes in nasal structures could not be considered due to the lack of an untreated control group. Moreover, as the present study was focused on the nasal changes that might affect breathing function, the other soft tissue changes in facial or nasal structures were not evaluated.

## Conclusion

With the limitations stated above, the present study revealed important findings, which were home message as follows; NA values increased significantly on both sides of all patients after modified Le Fort I advancement surgery. This effect was more evident in female patients than those in males. MNIV values increased; however, the increase was not statistically significant. INCV and TV values decreased in patients after surgery; however, it was statistically significant in male patients only. So, this result should be taken into account, especially in males with small noses. The amount of maxillary advancement did not affect the parameters measured. The efficiency of the treatment (T1–T0) did not change according to the sexes.

With the contribution of the present findings, future studies should be done with larger sample sizes and prospective and randomized controlled aspects.

## Declarations

**Ethical approval** The Institutional Review Board and Clinical Ethics committee of Tokat Gaziosmanpasa University Medicine Faculty approved this retrospective clinical study (Registration number: 20-KAEK-269).

**Informed consent** Not applicable.

**Conflict of interest** The authors declare no competing interests.

## References

- Minervini G, Romano A, Petrucci M, Maio C, Serpico R, Di Stasio D, Lucchese A (2018) Oral-facial-digital syndrome (OFD): 31-year follow-up management and monitoring. *J Biol Regul Homeost Agents* 32:127–130
- Akbulut N, Kursun Cakmak ES, Bayrak S (2020) Assessment of maxillary sinus changes after Le Fort I osteotomy surgery. *J Craniofac Surg* 31:497–501. <https://doi.org/10.1097/SCS.00000000000006659>
- Altug-Atac AT, Bolatoglu H, Memikoglu UT (2008) Facial soft tissue profile following bimaxillary orthognathic surgery. *Angle Orthod* 78:50–57. <https://doi.org/10.2319/122206-525.1>
- Neslihan I, Akbulut S, Akbulut N (2021) Soft tissue response after maxillary step surgery with or without ANS reduction. *Cumhuriyet Dent J* 24:121–128. <https://doi.org/10.7126/cumudj.810461>
- Catherine Z, Scolozzi P (2019) Modified Le Fort I step osteotomy for improvement of paranasal flatness in maxillary deficiency: technical note and series of 24 cases. *J Stomatol Oral Maxillofac Surg* 120:559–565. <https://doi.org/10.1016/j.jormas.2019.07.003>
- Bennett MA, Wolford LM (1985) The maxillary step osteotomy and Steinmann pin stabilization. *J Oral Maxillofac Surg* 43:307–311. [https://doi.org/10.1016/0278-2391\(85\)90297-6](https://doi.org/10.1016/0278-2391(85)90297-6)
- Chew MT (2005) Soft and hard tissue changes after bimaxillary surgery in Chinese class III patients. *Angle Orthod* 75:959–963. [https://doi.org/10.1043/0003-3219\(2005\)75\[959:SAHTCA\]2.0.CO;2](https://doi.org/10.1043/0003-3219(2005)75[959:SAHTCA]2.0.CO;2)
- Louis PJ, Austin RB, Waite PD, Mathews CS (2001) Soft tissue changes of the upper lip associated with maxillary advancement in obstructive sleep apnea patients. *J Oral Maxillofac Surg* 59:151–156. <https://doi.org/10.1053/joms.2001.20485>
- Soncul M, Bamber MA (2004) Evaluation of facial soft tissue changes with optical surface scan after surgical correction of Class III deformities. *J Oral Maxillofac Surg* 62:1331–1340. <https://doi.org/10.1016/j.joms.2004.04.019>
- Leong SC, Eccles R (2009) A systematic review of the nasal index and the significance of the shape and size of the nose in rhinology. *Clin Otolaryngol* 34:191–198. <https://doi.org/10.1111/j.1749-4486.2009.01905.x>
- Sforza C, Grandi G, De Menezes M, Tartaglia GM, Ferrario VF (2011) Age- and sex-related changes in the normal human external nose. *Forensic Sci Int* 204:205. <https://doi.org/10.1016/j.forsciint.2010.07.027>
- Allar ML, Movahed R, Wolford LM, Oliver DR, Harrison SD, Thiesen G, Kim KB (2019) Nasolabial changes following double jaw surgery. *J Craniofac Surg* 30:2560–2564. <https://doi.org/10.1097/SCS.00000000000005876>
- Altman JJ, Oeltjen JC (2007) Nasal deformities associated with orthognathic surgery: analysis, prevention, and correction. *J Craniofac Surg* 18:734–739. <https://doi.org/10.1097/SCS.0b013e3180684328>
- Atakan A, Ozcirpici AA, Pamukcu H, Bayram B (2020) Does Le Fort I osteotomy have an influence on nasal cavity and septum deviation? *Niger J Clin Pract* 23:240–245. [https://doi.org/10.4103/njcp.njcp\\_355\\_19](https://doi.org/10.4103/njcp.njcp_355_19)
- Dantas WR, Silveira MM, Vasconcelos BC, Porto GG (2015) Evaluation of the nasal shape after orthognathic surgery. *Braz J Otorhinolaryngol* 81:19–23. <https://doi.org/10.1016/j.bjorl.2014.08.005>
- Erbe M, Lehotay M, Gode U, Wigand ME, Neukam FW (2001) Nasal airway changes after Le Fort I-impaction and advancement: anatomical and functional findings. *Int J Oral Maxillofac Surg* 30:123–129. <https://doi.org/10.1054/ijom.2000.0001>
- Jeong HI, Lee HS, Jung YS, Park HS, Jung HD (2017) Nasal soft tissue change following bimaxillary orthognathic surgery. *J Craniofac Surg* 28:605–608. <https://doi.org/10.1097/SCS.00000000000003736>
- Khamashta-Ledezma L, Naini FB, Manisali M (2017) Review of nasal changes with maxillary orthognathic surgery. *J Istanbul Univ Fac Dent* 51:52–61. <https://doi.org/10.17096/jiufd.09789>
- Lee HJ, Park HS, Kyung HM, Kwon TG (2015) Soft tissue changes and skeletal stability after modified quadrangular Le Fort I osteotomy. *Int J Oral Maxillofac Surg* 44:356–361. <https://doi.org/10.1016/j.ijom.2014.10.019>
- Mirmohamadsadeghi H, Zanganeh R, Barati B, Tabrizi R (2020) Does maxillary superior repositioning affect nasal airway function? *Br J Oral Maxillofac Surg* 58:807–811. <https://doi.org/10.1016/j.bjoms.2020.04.020>
- Park SB, Yoon JK, Kim YI, Hwang DS, Cho BH, Son WS (2012) The evaluation of the nasal morphologic changes after bimaxillary surgery in skeletal class III malocclusion by using the superimposition of cone-beam computed tomography (CBCT) volumes. *J Craniofac Surg* 40:87–92. <https://doi.org/10.1016/j.jcms.2011.05.008>
- Pourdanesh F, Sharifi R, Mohebbi A, Jamilian A (2012) Effects of maxillary advancement and impaction on nasal airway function. *Int J Oral Maxillofac Surg* 41:1350–1352. <https://doi.org/10.1016/j.ijom.2012.03.024>
- Schendel SA, Carlotti AE Jr (1991) Nasal considerations in orthognathic surgery. *Am J Orthod Dentofacial Orthop* 100:197–208. [https://doi.org/10.1016/0889-5406\(91\)70056-3](https://doi.org/10.1016/0889-5406(91)70056-3)
- Turvey TA, Hall DJ, Warren DW (1984) Alterations in nasal airway resistance following superior repositioning of the maxilla. *Am J Orthod Dentofacial Orthop* 85:109–114. [https://doi.org/10.1016/0002-9416\(84\)90002-2](https://doi.org/10.1016/0002-9416(84)90002-2)
- Worasakwutiphong S, Chuang YF, Chang HW, Lin HH, Lin PJ, Lo LJ (2015) Nasal changes after orthognathic surgery for patients with prognathism and Class III malocclusion: analysis using three-dimensional photogrammetry. *JFMA* 114:112–123. <https://doi.org/10.1016/j.jfma.2014.10.003>
- Yamashita Y, Iwai T, Honda K, Fujita K, Imai H, Takasu H, Omura S, Hirota M, Mitsudo K (2020) Effectiveness of subspinal Le Fort I osteotomy in preventing postoperative nasal deformation. *J Plast Reconstr Aesthet Surg* 73:1326–1330. <https://doi.org/10.1016/j.bjps.2020.02.014>
- Steegman R, Hogeveen F, Schoeman A, Ren Y (2022) Cone beam computed tomography volumetric airway changes after orthognathic surgery: a systematic review. *Int J Oral Maxillofac Surg*. <https://doi.org/10.1016/j.ijom.2022.05.013>
- Nigro CE, Nigro JF, Mion O, Mello JF Jr (2009) Nasal valve: anatomy and physiology. *Braz J Otorhinolaryngol* 75:305–310. [https://doi.org/10.1016/s1808-8694\(15\)30795-3](https://doi.org/10.1016/s1808-8694(15)30795-3)
- Bohluli B, Varedi P, Kahali R, Bagheri SC (2015) External Nasal Valve Efficacy Index: a simple test to evaluate the external nasal valve. *Int J Oral Maxillofac Surg* 44:1240–1245. <https://doi.org/10.1016/j.ijom.2015.05.007>
- El-Anwar MW, Hamed AA, Abdulmonaem G, Elnashar I, Elfiki IM (2017) Computed tomography measurement of inferior turbinate in asymptomatic adult. *Int Arch Otorhinolaryngol* 21:366–370. <https://doi.org/10.1055/s-0037-1598649>
- Fastuca R, Lorusso P, Lagravere MO, Michelotti A, Portelli M, Zecca PA, D'Antò V, Miliati A, Nucera R, Caprioglio A (2017) Digital evaluation of nasal changes induced by rapid maxillary expansion with different anchorage and appliance design. *BMC Oral Health* 17:113. <https://doi.org/10.1186/s12903-017-0404-3>
- Neeraj RSG, Dixit A, Agarwal P, Chowdhry R, Chug A (2021) Relapse and temporomandibular joint dysfunction (TMD) as post-operative complication in skeletal class III patients undergoing bimaxillary orthognathic surgery: a systematic review. *J Oral Biol Craniofac Res* 11:467–475. <https://doi.org/10.1016/j.jobcr.2021.06.003>

33. Minervini G, Russo D, Herford AS, Gorassini F, Meto A, D'Amico C, Cervino G, Cicciu M, Fiorillo L (2022) Teledentistry in the management of patients with dental and temporomandibular disorders. *BioMed Res Int* 2022:7091153. <https://doi.org/10.1155/2022/7091153>
34. Markic G, Muller L, Patcas R, Roos M, Lochbuhler N, Peltomaki T, Karlo CA, Ullrich O, Kellenberger CJ (2015) Assessing the length of the mandibular ramus and the condylar process: a comparison of OPG, CBCT, CT, MRI, and lateral cephalometric measurements. *Eur J Orthod* 37:13–21. <https://doi.org/10.1093/ejo/cju008>
35. Guyader E, Savean J, Clodic C, Letellier P, Meriot P, Marianowski R (2018) Three-dimensional reconstruction of the temporal bone: comparison of in situ, CT, and CBCT measurements. *Eur Ann Otorhinolaryngol Head Neck Dis* 135:393–398. <https://doi.org/10.1016/j.anorl.2018.08.013>
36. Rosen HM (1988) Lip-nasal aesthetics following Le Fort I osteotomy. *Plast Reconstr Surg* 81:171–182. <https://doi.org/10.1097/00006534-198802000-00005>
37. Almuzian M, Almukhtar A, Ju X, Al-Hiyali A, Benington P, Ayoub A (2016) Effects of Le Fort I osteotomy on the nasopharyngeal airway-6-month follow-up. *J Oral Maxillofac Surg* 74:380–391. <https://doi.org/10.1016/j.joms.2015.06.172>

**Publisher's note** Springer Nature remains neutral with regard to jurisdictional claims in published maps and institutional affiliations.

Springer Nature or its licensor (e.g. a society or other partner) holds exclusive rights to this article under a publishing agreement with the author(s) or other rightsholder(s); author self-archiving of the accepted manuscript version of this article is solely governed by the terms of such publishing agreement and applicable law.