

Treatment of arteriovenous fistula aneurysms in hemodialysis patients and introduction of Tan-Gor skin flap technique

Arteriyovenöz fistül anevrizmalarının tedavisi ve Tan-Gör cilt flebi tekniğinin tanımlanması

Ömer Tanyeli, Niyazi Görmüş

Department of Cardiovascular Surgery, Necmettin Erbakan University Meram Medical Faculty, Konya, Turkey

ABSTRACT

Objectives: In this study, we present our experience with arteriovenous fistula (AVF) aneurysm treatment and introduce a new technique, Tan-Gor technique, for the resection of giant AVF aneurysms.

Patients and methods: Between January 2011 and December 2015, a total of 48 patients (26 females, 22 males; mean age 51.5 years; range, 16 to 85 years) who were operated for either AVF aneurysms or high-flux AVFs were retrospectively analyzed. Fifty surgical procedures were performed including 40 (80%) in the left upper extremity, nine (18%) in the right upper extremity, and one (2%) in the left lower extremity.

Results: Of all operations, 64% (n=32) were performed over the cephalic veins. Of these patients, 22 had aneurysmectomy and excision, six had plication, four had banding, and two had both banding and plication. Fourteen operations were performed on the basilic vein: six patients had aneurysmectomy alone, four had aneurysmectomy and graft interposition, two had plication, one had banding, and one had both banding and plication.

Conclusion: Preservation of the AVFs should be the first choice in aneurysmal dilatation of AVFs. When reconstruction of the AVF is not possible and surgical aneurysmectomy is a must, this novel technique can be safely performed via excision of the vein with overlying skin to decrease complications, to reduce operational time, and to improve wound healing and cosmetic results.

Keywords: Aneurysm; arteriovenous fistula; chronic renal failure; hemodialysis.

ÖZ

Amaç: Bu çalışmada, arteriyovenöz fistül (AVF) anevrizma tedavisine ilişkin deneyimlerimiz sunuldu ve dev AVF anevrizmalarının rezeksiyonlarında yeni bir teknik olan Tan-Gör tekniği tanıtıldı.

Hastalar ve Yöntemler: Ocak 2011 - Aralık 2015 tarihleri arasında AVF anevrizması veya yüksek debili AVF nedeniyle ameliyat edilen toplam 48 hasta (26 kadın, 22 erkek; ort. yaş 51.5 yıl; dağılım 16-85 yıl) retrospektif olarak incelendi. Kırk (%80) sol üst ekstremité, dokuz (%18) sağ üst ekstremité ve biri (%2) sol alt ekstremité olmak üzere, toplamda 50 cerrahi işlem uygulandı.

Bulgular: Tüm ameliyatlarda %64'ü (n=32) sefalik venlere uygulandı. Bu hastaların 22'sine anevrizmektomi ve eksizyon, altısına plikasyon, dördüne banding ve ikisine banding ile birlikte plikasyon işlemi uygulandı. On dört ameliyat basilik venlere uygulandı; altı hastaya yalnızca anevrizmektomi, dördüne anevrizmektomi ile birlikte greft interpozisyonu, ikisine plikasyon, birine banding ve birine de banding ile birlikte plikasyon uygulandı.

Sonuç: Arteriyovenöz fistüllerin anevrizmal dilatasyonlarında ilk seçenek AVF'nin korunması olmalıdır. Arteriyovenöz fistüllerin rekonstrüksiyonunun mümkün olmadığı ve anevrizmektominin zorunlu olduğu durumlarda, komplikasyonların azaltılması, ameliyat süresinin kısaltılması, yara iyileşmesi ve kozmetik sonuçların iyileştirilmesi için, bu yeni teknik, venin üzerindeki deri ile birlikte eksizyonuyla güvenli bir şekilde gerçekleştirilebilir.

Anahtar sözcükler: Anevrizma; arteriyovenöz fistül; kronik böbrek yetmezliği; hemodiyaliz.

Received: January 09, 2018 Accepted: February 06, 2018

Correspondence: Ömer Tanyeli, MD. Necmettin Erbakan Üniversitesi Meram Tıp Fakültesi, Kalp ve Damar Cerrahisi Anabilim Dalı, 42080 Akyokuş, Konya, Turkey.
e-mail: otanyeli@gmail.com

Citation:

Tanyeli Ö, Görmüş N. Treatment of arteriovenous fistula aneurysms in hemodialysis patients and introduction of Tan-Gor skin flap technique. Damar Cer Derg 2018;27(1):8-16.

This paper was presented at the 14th Congress of Asian Society for Vascular Surgery & 16th Congress of Turkish Society for Vascular and Endovascular Surgery & 8th Asian Venous Forum & 7th Congress of Turkish Society for Phlebology, October 26-29, 2013, Held in Istanbul, Turkey.

Upper extremity native arteriovenous fistulas (AVFs) are the most commonly used dialysis access in end-stage renal disease (ESRD) patients for hemodialysis (HD). Although renal transplantation is the preferred choice of treatment, due to lack of renal donors, renal replacement by HD is the standard treatment of choice, until an ESRD patient becomes a recipient. During this period of time, ESRD patients have few options for HD, such as creation of native AVFs, use of either temporary or permanent HD catheters, or peritoneal dialysis. If the patient's vasculature is suitable, the autogenous AVFs are commonly created from the non-dominant arm starting from the elbow region by radiocephalic (snuff box, Brescia-Cimino, and high radiocephalic), brachiocephalic, and brachio basilic fistula formation. If maturation fails or when AVF thrombosis is observed, AVF creation is performed from the upper level or alternatively the dominant arm is used. If the venous structures are not suitable, vascular grafts are used for the AVF formation. Although native AVFs have better patency rates and less infectious complications than the AV grafts, none of the HD accesses are without complications. Native AVFs are likely to have the fewest complications.^[1] Dysfunction of these fistulas is the most common reason for a second intervention and for recurrent hospitalization. Approximately one-third of AVFs develop a complication during its life span.^[1] The most frequent complications are aneurysm formation, vascular steal syndrome, venous hypertension, hemorrhage, infection, and neurological disorders.^[2] Due to recurrent puncture sites, aneurysm formation is one of the most common complications with high flow AVFs in these patients.

In this study, we aimed to present our experience with AVF aneurysm treatment and to introduce a new technique for the removal of giant AVF aneurysms, which we call the Tan-Gor skin flap technique.

PATIENTS AND METHODS

Between January 2011 and December 2015, a total of 845 operations were performed in our department for the vascular access, including the formation of new AVFs or revision surgery. The study was conducted in accordance with the principles of the Declaration of Helsinki.

All patients were referred to our clinic either from the department of nephrology or from other HD centers. Our database was searched retrospectively

to identify the patients who were operated due to high-flux AVFs or venous aneurysms complicating AVFs. A venous aneurysm was defined as a fusiform or saccular dilatation having a three-fold increase in diameter immediately after the proximal segment of the AVF. A venous aneurysm was accepted as an indication for operation, if it was associated with active bleeding or rupture of the aneurysm (emergency surgery), low flux or thrombosis as a result of aneurysm-related stenosis, erosion of the overlying skin, pain over the skin of the aneurysm or high-flux AVFs resulting in cardiac problems. A total of 48 patients (26 females, 22 males; mean age 51.5 years; range, 16 to 85 years) were included in the study. All operations were performed by a single team of cardiovascular surgeons. All patients received 1 g of cefuroxime intravenously immediately prior to the operation and 5,000 IU of heparin before clamping the AVF.

Regardless of the cause, our first aim in AVF aneurysms was to preserve the native AVF. In the case of high-flux AVFs, the major complaints were fatigue, pulsatile masses, and pain over the enlarged vein. Each patient was examined by color Doppler ultrasonography to measure the blood flow rate before the operation. If the patients had a flow rate of more than 1,300 mL/min without an intraluminal thrombus and skin erosion, banding of the AVF over the venous segment close to the AV anastomosis site was performed in the patients with suitable anatomy. The reduction of the AV flow rate was first measured manually and, then, a hemostatic clip was placed for appropriate sizing of the band. The band was, then, sutured by 6/0 prolene suture over the venous segment of the AVF to avoid migration. After the procedure was completed, the flow rate was measured by color Doppler ultrasonography. The procedure was considered successful, if the flow rate was less than 800 mL/min. If the patient also had aneurysmal dilatation to be reconstructed, aneurysm plication was performed during the same session. Using this technique, six cephalic (two radiocephalic and four brachiocephalic) and three basilic vein AVFs (brachio basilic) were reconstructed.

In the first few operations, AVF aneurysms were resected using classical incision over the aneurysmal dilatation of the AVF. Initially, the skin was freed from the underlying arterialized vein. After clamping the proximal and distal portion of the aneurysm, either a banding or polytetrafluoroethylene (PTFE) graft interposition were performed in suitable patients. After

the procedure, excessive tissue over the aneurysmal segment was also resected. This technique carried a high risk of bleeding due to tissue adhesions and it was also time-consuming. Then, it was realized that, if we did not touch the skin over the aneurysm, the resection period would be easier. As a result, in giant aneurysm formations, a novel technique was performed to avoid direct contact with the aneurysmatic vein via excision of the vein with the skin flap.

In this technique, before the operation, a careful examination was performed both manually and with Doppler ultrasonography. The venous segment was examined all along its course and the skin was marked with a pen to describe the skin incision from the lateral aspects of the aneurysm in a fish-mouth pattern. If the aneurysm was too long, two small separate incisions were performed. Under this approach, we leave the excessive skin tissue over the aneurysmal segment of the AVF and start the dissection from the medial and lateral aspects of the vein; therefore, the most difficult part of the operation is skipped by avoiding direct contact with the firm adhesions between the vein and skin. In this way, the size of the skin was reduced. Then, the proximal portion of the AVF was secured with nylon tape, and the aneurysmal segment of the

arterialized vein was dissected up to the healthy zone by electrocautery and fine scissors from the lateral and posterior portions of the aneurysm. After completely freeing the vein, the aneurysm was resected with the overlying skin flap. Later, if there were enough healthy vein segments, an 8 mm PTFE or biological graft was interpositioned for vascular access continuity in suitable patients. Finally, subcutaneous tissue approximation was performed and the skin was closed after placing a Hemovac drain by running cutaneous sutures. This technique, which we call the Tan-Gor skin flap technique, was not previously described. Interposition of a vascular graft using this technique is shown in Figures 1 and 2.

All the patients were retrospectively evaluated in terms of the AVF aneurysm site, surgical methods, and by duration of operation. Unfortunately, certain data regarding the first few operations performed using the classical technique was missing. Therefore, only the duration variables of operations with this new technique were able to be evaluated.

Statistical analysis

Statistical analysis was performed using the IBM SPSS version 20.0 (IBM Corp., Armonk, NY, USA).

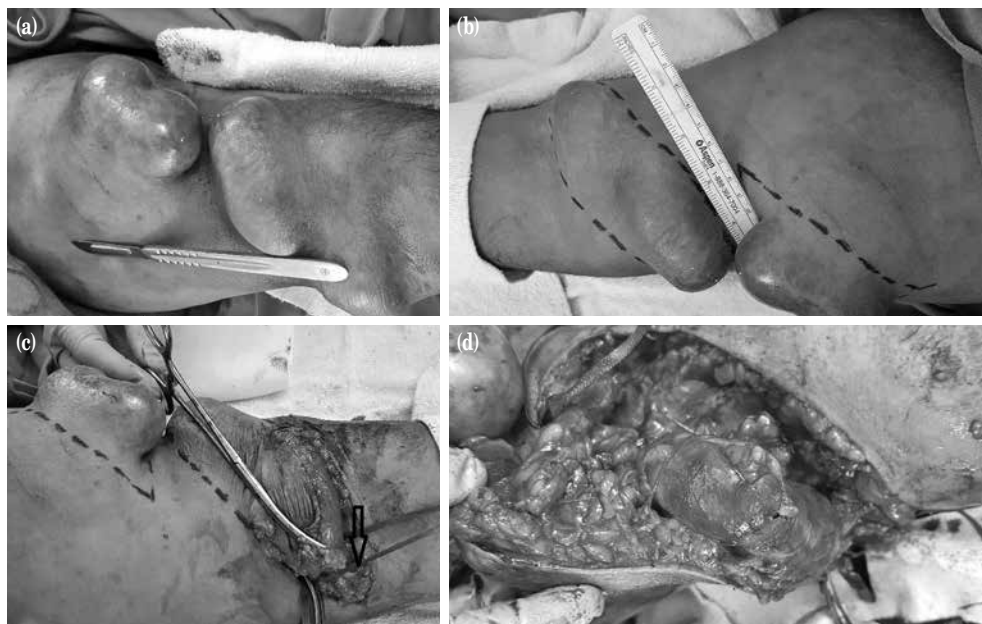


Figure 1. Operative steps concerning the skin flap technique. (a) A giant thrombosed brachiocephalic arteriovenous fistula and planned surgical incisions are drawn by a surgical pen intraoperatively. (b) Skin incision is made in a fish-mouth pattern, and proximal part of the arteriovenous fistula is secured by nylon tape. (c, d) Lateral aspect of the aneurysm is resected using electrocautery from a distance to the native arteriovenous fistula avoiding direct contact to the dense fibrous tissues over the aneurysm.

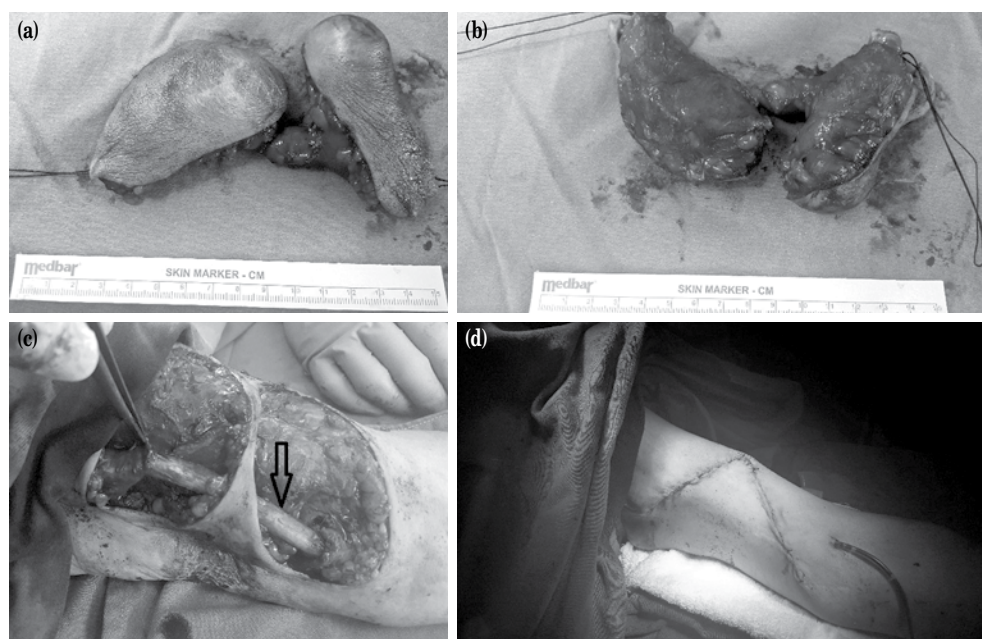


Figure 2. Operative steps concerning the skin flap technique. (a, b) Exploration of the venous segment of the arteriovenous fistula avoiding direct contact to the aneurysm and removal of the aneurysm by the skin flap technique by removing the intact tissue for better wound healing. (c) A biological vein graft was interpositioned between the venous segments of the fistula. (d) Closure of the skin without any need for excessive skin tissue removal and reconstruction.

Data were presented in number and percentage for categorical variables and in mean and range (min-max) values. A p value of <0.05 was considered statistically significant.

RESULTS

The mean age was 53 (range, 24 to 80) years in male patients and 50.3 (range, 16 to 85) years in female patients. Surgical sites consisted of 40 (80%) left upper extremity, nine (18%) right upper extremity, and one (2%) left lower extremity. The anesthesia technique used was local anesthesia (56%), if the patient had only high-flow rate AVFs or localized aneurysms. If the patient had giant aneurysms, our preference was general anesthesia with endotracheal intubation, laryngeal mask, or axillary nerve blockade.

A total of 50 surgical procedures were performed on 48 patients. The list of the operational techniques is presented in Table 1. Most of the operations were performed over the cephalic veins ($n=32$, 64%), either on the forearm or arm region. Twenty-two patients had cephalic vein aneurysmectomy and excision, six had cephalic vein plication, four had cephalic vein banding, and two patients had both cephalic

vein banding and plication simultaneously. In the arm region, 14 operations (28%) were performed over the basilic veins: six patients had basilic vein aneurysmectomy alone, four patients had basilic vein aneurysmectomy and graft interposition, two patients had basilic vein plication, one had basilic vein banding, and one had both banding and plication. Interestingly, one patient had aneurysmal dilatation of the brachioaxillary biological graft, in which excision and graft re-interposition were performed (Figure 3). One patient had a total graft rupture and

Table 1. List of the operations for arteriovenous fistula aneurysms and high-flux arteriovenous fistulas

Type of the operation	Number of patients
Cephalic vein aneurysmectomy	22
Cephalic vein plication	6
Cephalic vein banding	4
Cephalic vein banding and plication	2
Basilic vein aneurysmectomy only	6
Basilic vein aneurysmectomy and graft interposition	4
Basilic vein banding	1
Basilic vein plication	2
Basilic vein banding and plication	1
Aneurysm resection of biological graft and graft interposition	1
Femoral graft interposition	1

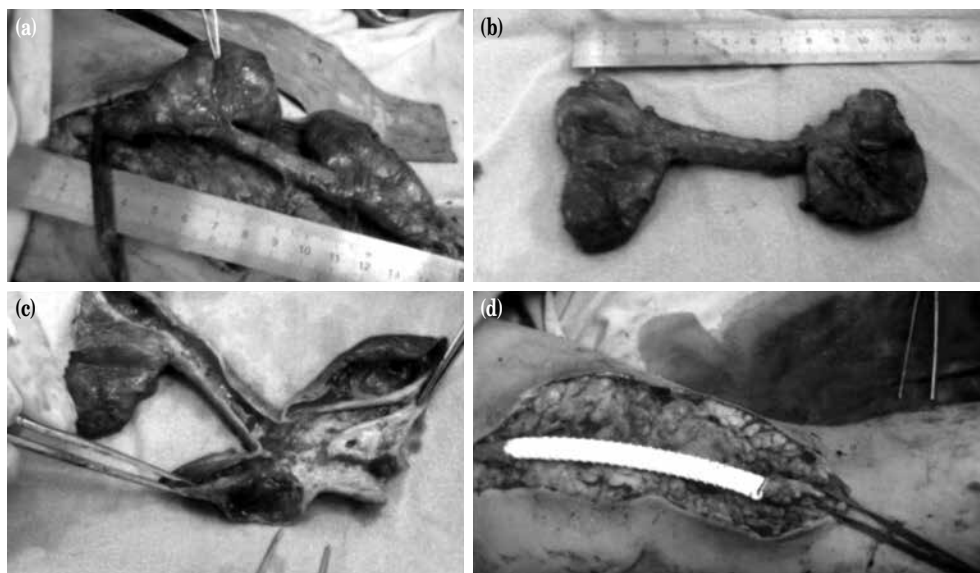


Figure 3. Excision of the aneurysmatic biological brachioaxillary arteriovenous fistula graft thrombosis. (a) Aneurysm formation over the needle punctures of the biological graft material. (b) Excised biological aneurysmatic graft. (c) Intraluminal aneurysmal structure after removal of the thrombotic material. (d) An 8-mm polytetrafluoroethylene graft interposition between the resected biological graft.

pseudoaneurysm formation in the femoral region and graft interposition was performed with an 8 mm PTFE graft.

Three of the patients (6%) were taken into emergency surgery due to rupture and active bleeding (two for cephalic vein aneurysm rupture and one for a ruptured pseudoaneurysm of the femoral PTFE graft).

Overall, 40 (80%) of the operations were performed due to AVF aneurysm formation, 28 of which were located over the cephalic vein (six were radiocephalic over the forearm and 22 were brachiocephalic over the arm), and 12 were located over the basilic vein on the arm region.

As a general rule, since the cephalic vein is the first choice in AVF formation, the most common sites of operation using the Tan-Gor skin flap technique were the cephalic veins. However, we realized that basilic veins reached greater diameters forming giant aneurysms (the largest diameter in our series being 7.9 cm) due to the surgical technique in basilic vein transposition, which was performed by ligating the side branches of the basilic veins.

All operations by the Tan-Gor skin flap technique were performed on their left upper extremities. Eight (73%) of the patients were females, whereas three (27%) of the patients were males. The mean

age was 50.9 (range, 24 to 78) years. Two patients were operated by local anesthesia, whereas the other nine received general anesthesia (five endotracheal and four laryngeal mask). Two of the patients

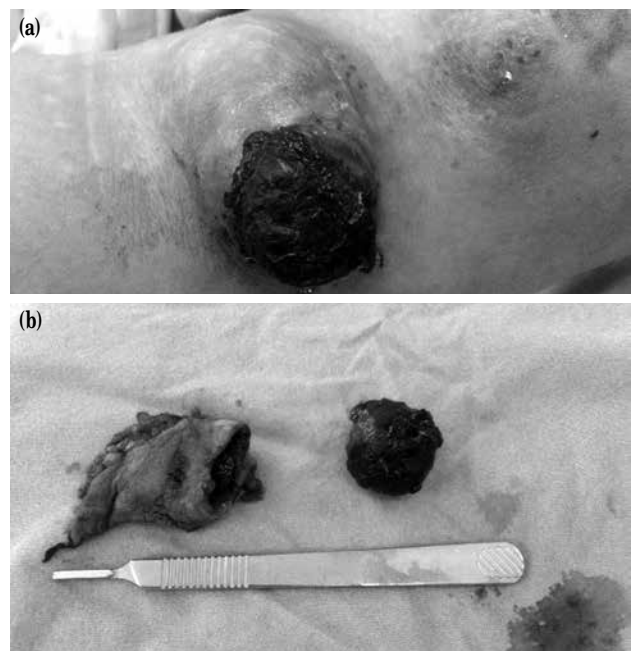


Figure 4. A ruptured brachiocephalic arteriovenous fistula. (a) Skin erosion and hemostatic plug formation over the ruptured cephalic vein. (b) Excised ruptured aneurysm using the skin flap technique.

Table 2. Data of patients regarding the Tan-Gor skin flap technique

Patient initials	Age/Gender	Vascular access site	Location of the aneurysm	Anesthesia type	Surgery
MS	60/M	BCAVF	Left cephalic vein	General anesthesia	Cephalic vein aneurysmectomy
MG	57/F	RCAVF	Left cephalic vein	General anesthesia	Cephalic vein aneurysmectomy
SS	30/F	BBAVF	Left basilic vein	General anesthesia	Basilic vein aneurysmectomy & 8 mm PTFE graft interposition
AB	63/F	BCAVF	Left cephalic vein	General anesthesia	Ruptured Cephalic vein aneurysmectomy (emergency)
KK	41/M	BCAVF	Left cephalic vein	Local anesthesia	Cephalic vein aneurysmectomy
AS	60/F	BCAVF	Left cephalic vein	Local anesthesia	Cephalic vein aneurysmectomy
HO	78/F	BBAVF	Left basilic vein	General anesthesia	Basilic vein aneurysmectomy
ST	24/F	BCAVF	Left cephalic vein	General anesthesia	Ruptured Cephalic vein aneurysmectomy (emergency) & primary brachial artery repair
IG	54/F	BBAVF	Left basilic vein	General anesthesia	Thrombosed basilic vein aneurysmectomy
HI	38/M	BCAVF	Left cephalic vein	General anesthesia	Cephalic vein aneurysmectomy & 8 mm PTFE graft interposition
ZB	55/F	BBAVF	Left basilic vein	General anesthesia	Thrombosed Basilic vein aneurysmectomy & 8 mm biological graft interposition

BCAVF: Brachiocephalic arteriovenous fistula; RCAVF: Radiocephalic arteriovenous fistula; BBAVF: Brachio basilic arteriovenous fistula; PTFE: Polytetrafluoroethylene.

underwent emergency surgery due to rupture of the aneurysm, whereas the others underwent elective surgery. Figure 4 shows the removal of the ruptured AVF aneurysm by the Tan-Gor technique. In most cases, aneurysmectomy ended in less than half an hour (the mean time for excision of the aneurysm is 19 min for basilic veins and 23 min for cephalic vein aneurysms) excluding the graft interposition. Data of patients who were operated using the Tan-Gor technique are summarized in Table 2.

None of our patients had rupture of the aneurysm during the operational process (excluding the emergency cases). None of the elective cases needed blood transfusion due to blood loss postoperatively. Almost all of the patients were discharged from the hospital the day after the first HD session performed from the jugular transient HD catheters with oral antibiotics (cefuroxime axetil 500 mg bid). Only two patients had serious thrombophlebitis and required prolonged antibiotic therapy and hospitalization both pre- and postoperatively.

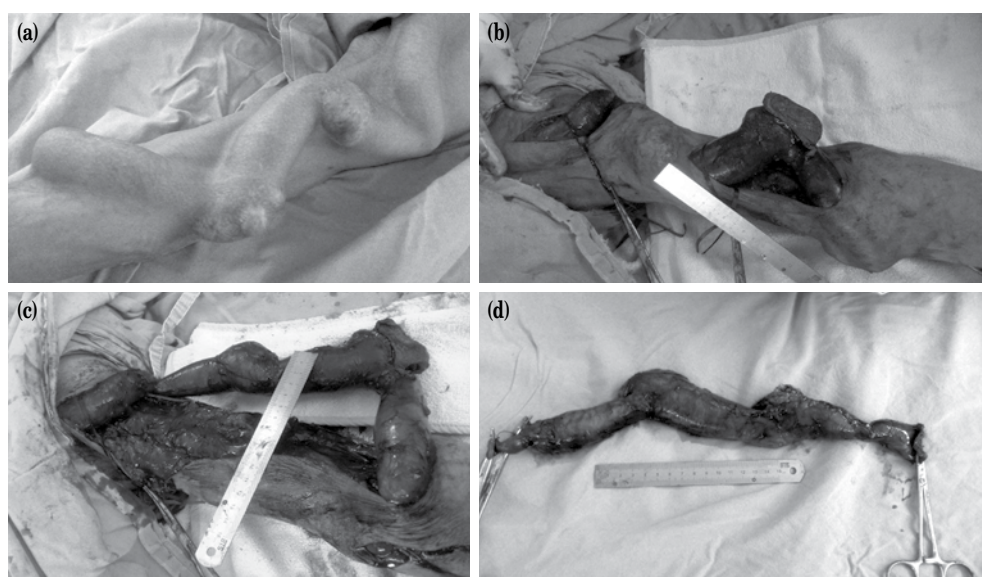


Figure 5. (a-d) Removal of the giant brachiocephalic arteriovenous fistula aneurysm using classical incision. Note the length of the incision made for exploration.

DISCUSSION

Hemodialysis, peritoneal dialysis, and renal transplant are the possible interventions for ESRD patients and AVFs are the most widely used HD access in these patients. Unless a renal transplant is performed, either these AVFs or permanent or transient HD catheters are the access sites for lifelong HD. Usually AVFs are created starting from the most distal site of the non-dominant upper extremity. Unfortunately, AVFs are not free from complications. Approximately one-third of AVFs develop a complication during its life span.^[1] The most frequent complications are aneurysm formation, vascular steal syndrome, venous hypertension, hemorrhage, infection, and neurological disorders.^[2] Complications of vascular access require hospitalization in 39% of patients with definitive loss of vascular access in 29%.^[3] According to a meta-analysis, the incidence of aneurysm and false aneurysm in HD vascular access ranges from 0 to 6%.^[4] In addition to loss of function and the risks mentioned above, patients usually report discomfort due to the appearance of the fistula more than any other symptom including pain, bleeding, and bruising.^[5]

The National Kidney Foundation-Kidney Disease Outcomes Quality Initiative (NKF-DOQI) guidelines state avoiding aneurysm formation, and the patient should insist on site rotation, unless a buttonhole method is used in a native fistula. Progressive enlargement of an aneurysm can eventually compromise the skin above the fistula, leading to possible ruptures. This may result in hemorrhage, exsanguinations, and death, eventually. To overcome this potentially lethal complication, various techniques are described in the literature, including surgical techniques and endovascular techniques.

Ligation of the AVF is the least desirable option, even if we assume that the patient has a functioning transplanted kidney. Pierce et al.^[6] reported the use of longitudinal stapling to reduce the normal diameter in 12 patients with non-infected, fusiform venous aneurysms with a mean patency of 24.7 months in 10 of 12 patients. Alternative treatment options include open plication, excision and primary anastomosis, excision, and interposition of venous or prosthetic graft.^[7-9] Georgiadis et al.^[8] showed that specific group of corrections were superior by means of autogenous better than prosthetic, true aneurysms better than false aneurysms, patients with one or two previous AVFs in the revised arm better than those with more than

two previous accesses in the revised arm and finally forearms better than those in the upper arm.

Our patient series consisted of those with AVFs with high flux and AVF aneurysms. As reported in the literature, the primary objective of any surgical correction of AVF aneurysms should be to preserve the native fistula first, as we did in our study. For patients with correctable anatomy, our main strategy was either banding of the high-flux AVF or plication of the aneurysmatic segment with running 4/0 prolene sutures. In case of aneurysm formation in the distal upper arm, we preferred a new AVF creation at the antecubital region using the brachial artery, since the patient still had a potential native AVF route. Most of the cephalic vein aneurysmectomy cases ended with a new brachiocephalic AVF. Since the patient had an already arterialized venous segment, these fistulas matured earlier.

Although there are some salvage procedures for the preservation of the native AVF aneurysms, there are still some patients who unfortunately need either complete or partial resection of these AVF aneurysms. The literature is lacking in the description of techniques for removal of the aneurysm, when resection is the concern, particularly in giant AVF aneurysms, and emergency cases with active bleeding. Our technique, Tan-Gor skin flap technique, is the first technique which describes the resection of the aneurysm avoiding direct contact of the aneurysm.

If a patient requires aneurysmectomy, the AVF anastomosis site or the arterial segment is secured and the skin incision is performed longitudinally over the aneurysmal segment where the skin adhesion is mostly present. If a surgeon is not careful, the aneurysmatic segment of the vein can be damaged due to its relatively thin wall and dense adhesions with the surrounding tissue. This is probably the most important and the most time-consuming step of the dissection. After complete resection, there is usually excess skin tissue which needs to be reconstructed. The operative steps regarding the classical surgical removal of a giant AVF aneurysm is shown in Figure 5. Different from the classical surgical technique, the final step for skin resection is performed first and the anterior aspect of the aneurysm is left untouched (Figure 6).

In radiocephalic or brachiocephalic AVFs, side branches of the cephalic veins became enlarged by time due to an increased and arterialized venous flow. The same is also true for brachio basilic AVFs with one

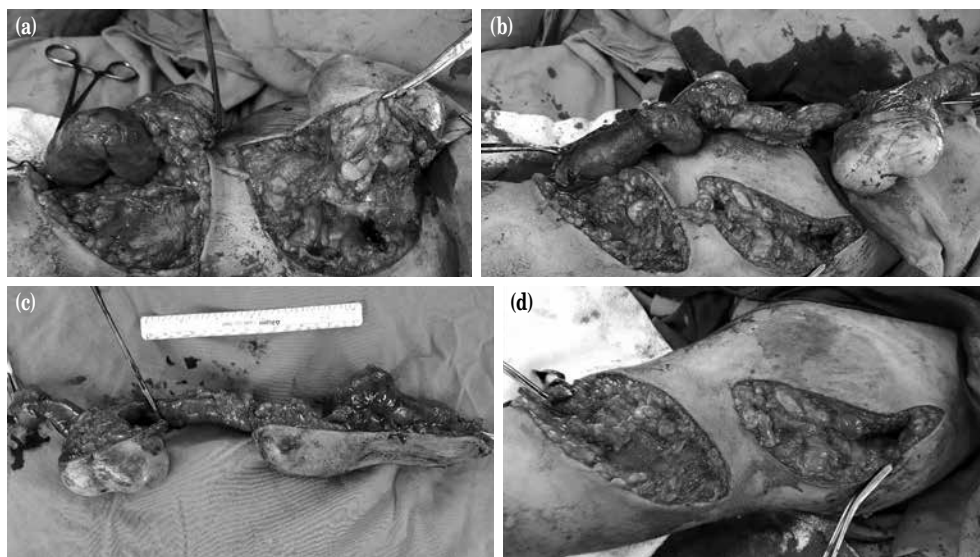


Figure 6. (a-d) Operative steps showing removal of giant aneurysmal dilatation of the basilic vein after mapping of the skin incisions using the Tan-Gor skin flap technique.

basic difference: the side branches of the basilic veins are ligated and basilic vein is turned into a tubular structure without side branches and superficialized by being passed through a tunnel before brachial artery anastomosis. During recurrent HD sessions, if a needle is inserted from the same segment, aneurysm formation becomes a more common sequela over time, and this complication may cause fatal complications through ruptured aneurysms or may cause AVF failure as a result of thrombosis mainly caused by turbulence flow in the aneurysm.

The lateral and medial aspects of the aneurysm are usually free from dense adhesive tissue and easy to dissect. In case of the basilic vein transposition performed AVFs, this method is more useful, since there are no side branches which were ligated during the AVF creation. That is why this technique is more preferable for the aneurysms of basilic vein transpositions. This technique is particularly useful for the complete removal of the aneurysm and for ruptured aneurysms. In addition, if a good mapping is performed, this technique may also be beneficial for graft interposition to reconstruct the AVF. Of our Tan-Gor skin flap technique patients, two were operated due to aneurysmal ruptures and two were operated due to chronic thrombosis. In the remaining seven patients, we attempted to reconstruct the vein and three of them were reconstructed by either PTFE or biological graft interposition. The skin incision length was less than

the classical incision resulting in better wound healing and cosmetic results, and the patients were discharged from the hospital after the first HD session. Since these patients were also immunocompromised patients, preservation of the skin continuity might have resulted in less infectious diseases.

The limitation of this study is that we were not able to statistically document the time benefit of this new technique, since we did not calculate the exact time for surgical excision of AVF aneurysms using the classical technique. After invention of the new technique, we calculated the time needed for the removal of the aneurysm. Based on our observations, although we were unable to perform statistical analysis, we conclude that time spent for surgical excision of the AVF aneurysms in skin flap technique is almost half the time using the classical technique. Nonetheless, further studies are needed to confirm these findings.

In conclusion, preservation of the AVFs should be the first choice of treatment in aneurysmal dilatation of AVFs. Since aneurysmal dilatation decreases the access sites, it is not always possible to preserve the AVF without excision. To avoid this complication, different puncture sites should be attempted during HD sessions. If reconstruction of the AVF is not possible and surgical aneurysmectomy is required, the Tan-Gor skin flap technique is a safe technique, particularly for giant basilic vein aneurysms and emergency aneurysmal ruptures which decreases the

operational time dramatically and provides better wound healing and cosmetic results.

Declaration of conflicting interests

The authors declared no conflicts of interest with respect to the authorship and/or publication of this article.

Funding

The authors received no financial support for the research and/or authorship of this article.

REFERENCES

1. Fitzgerald JT, Schanzer A, Chin AI, McVicar JP, Perez RV, Troppmann C. Outcomes of upper arm arteriovenous fistulas for maintenance hemodialysis access. *Arch Surg* 2004;139:201-8.
2. Feldman HI, Held PJ, Hutchinson JT, Stoiber E, Hartigan MF, Berlin JA. Hemodialysis vascular access morbidity in the United States. *Kidney Int* 1993;43:1091-6.
3. Elseviers MM, Van Waeleghem JP. Identifying vascular access complications among ESRD patients in Europe. A prospective, multicenter study. *Nephrol News Issues* 2003;17:61-4.
4. Huber TS, Carter JW, Carter RL, Seeger JM. Patency of autogenous and polytetrafluoroethylene upper extremity arteriovenous hemodialysis accesses: a systematic review. *J Vasc Surg* 2003;38:1005-11.
5. Quinn RR, Lamping DL, Lok CE, Meyer RA, Hiller JA, Lee J, et al. The Vascular Access Questionnaire: assessing patient-reported views of vascular access. *J Vasc Access* 2008;9:122-8.
6. Pierce GE, Thomas JH, Fenton JR. Novel repair of venous aneurysms secondary to arteriovenous dialysis fistulae. *Vasc Endovascular Surg* 2007;41:55-60.
7. Lo HY, Tan SG. Arteriovenous fistula aneurysm--plicate, not ligate. *Ann Acad Med Singapore* 2007;36:851-3.
8. Georgiadis GS, Lazarides MK, Panagoutsos SA, Kantartzis KM, Lambidis CD, Stamos DN, et al. Surgical revision of complicated false and true vascular access-related aneurysms. *J Vasc Surg* 2008;47:1284-91.
9. Woo K, Cook PR, Garg J, Hye RJ, Canty TG. Midterm results of a novel technique to salvage autogenous dialysis access in aneurysmal arteriovenous fistulas. *J Vasc Surg* 2010;51:921-5.