

Transapical Aortic Valve Implantation in High-Risk Aortic Stenosis: A Case Report

Yüksek Riskli Aort Darlığında Transapikal Aort Kapak İmplantasyonu: Olgu Sunumu

Abdullah Ozer^{1,2}, İlker Dal³, Okan Uğurlu¹, Gamze Sarkılar⁴, Mehmet Kayrak³, Erdal Ege¹, Kurtuluş Ozdemir³
Ali Sarıgül¹

¹ Necmettin Erbakan University, Meram Faculty of Medicine, Department of Cardiovascular Surgery, Konya, Turkey

² Gazi University, Faculty of Medicine, Department of Cardiovascular Surgery, Ankara, Turkey

³ Necmettin Erbakan University, Meram Faculty of Medicine, Department of Cardiology, Konya, Turkey

⁴ Necmettin Erbakan University, Meram Faculty of Medicine, Department of Anesthesiology, Konya, Turkey

ABSTRACT

A 72-year-old female patient with respiratory distress and chest pain was referred for echocardiography after which a severe aortic stenosis was diagnosed. From clinical perspective an AVR would have carried too much risk in this case, therefore TAVI with transapical approach via left anterior thoracotomy was the treatment of choice. In this case report, we describe our experience with this new procedure in our country.

Key Words: Aortic stenosis, transapical aortic valve implantation, valvular heart disease

Received: 12.03.2015

Accepted: 02.12.2016

ÖZET

Yetmiş iki yaşında bayan hasta göğüs ağrısı ve solunum sıkıntısı şikayetiyle ekokardiyografiye yönlendirildi, sonrasında ciddi aort darlığı tanısı konuldu. Klinik bakış açısıyla AVR bu vakada çok riskliydi, bu yüzden tedavi seçeneği sol ön torakotomiyle transapikal yaklaşımla TAVI'ydı. Bu olgu sunumunda ülkemizde bu yeni prosedürle olan deneyimimizi paylaşıyoruz.

Anahtar Sözcükler: Aort darlığı, transapikal aort kapak implantasyonu, kalp kapak hastalığı

Geliş Tarihi: 03.12.2015

Kabul Tarihi: 12.02.2016

INTRODUCTION

With the improvement in living standards and related increase in the aging population, the prevalence of calcific aortic valve stenosis (AS) has increased consequently. The prevalence of aortic stenosis in patients older than 65 years is 2-5%. Valve diseases are mostly seen in this age group (1). Aortic valve replacement (AVR) has been a successful treatment for aortic stenosis since many years. However, AVR is a highly risky procedure in older aged patients with excess comorbidity resulting in 30% of the patients being refused for surgical treatment (2).

Cardiovascular comorbidity and mortality rates in older aged patients increase the procedural risks of open surgery. The logistic euroSCORE for surgery in patients above 75 years increases to 1% each year. 30% of patients with AS are refused to undergo surgery due to high morbidity and mortality rates. Despite the poor prognosis of symptomatic AS, due to being a high risk disease open heart surgery is still performed (3-5). In high risk patient populations, a less invasive approach could be more advantageous. In 1992, Andersen et al. studied the use of porcine bioprosthetic valves in animal models. In 2002, Cribier et al. studied the use of transcatheter aortic valve implantation (TAVI) (6-7).

CASE REPORT

A 72-year-old female patient with respiratory distress and chest pain was submitted to our department. During patient evaluation, no signs of coronary ischemia were found. Echocardiography showed an ejection fraction of 30%. Aortic valve leaflets were fibrocalcific, thick and stenotic. Maximum gradient of the aortic valve was 47 mmHg, the mean gradient was 30 mmHg, and mild aortic insufficiency (grade 1). The patient history included coronary artery bypass grafting (CABG) in 1998, a cerebrovascular accident, chronic obstructive pulmonary disease (COPD), diabetes mellitus (DM), gastrointestinal bleeding, and carotid artery stenosis which was treated with a stent.

Surgical Method

Overall, the patient had high morbidity and mortality rates, therefore a TAVI with a transfemoral approach became the treatment of choice. Due to failure of transfemoral access, the aortic valve was implanted using a transapical approach.

Address for Correspondence / Yazışma Adresi: Abdullah Ozer, MD, Gazi University, Faculty of Medicine, Department of Cardiovascular Surgery, Ankara, Turkey
E-mail: dr-abdozer@hotmail.com

©Telif Hakkı 2016 Gazi Üniversitesi Tıp Fakültesi - Makale metnine <http://medicaljournal.gazi.edu.tr/> web adresinden ulaşılabilir.

©Copyright 2016 by Gazi University Medical Faculty - Available on-line at web site <http://medicaljournal.gazi.edu.tr/>

doi:<http://dx.doi.org/10.12996/gmj.2016.29>

Under general anesthesia a temporary pacing wire was inserted from right femoral. The mediastinum was reached via anterior thoracotomy in the 5th intercostal space in the left submammary region. The pericardium was then opened and hanged using sutures. A transesophageal echocardiography probe was inserted. An apex stabilizer was placed in the left ventricle for the valve delivery system. After a 22 F balloon dilatation, the valve delivery system was introduced via the apex. No:25 bioprosthetic aortic valve was implanted with transapical approach. After finishing the procedure, a chest tube was inserted in the left thorax. The left anterior thoracotomy was appropriately closed (Figure 1-4).

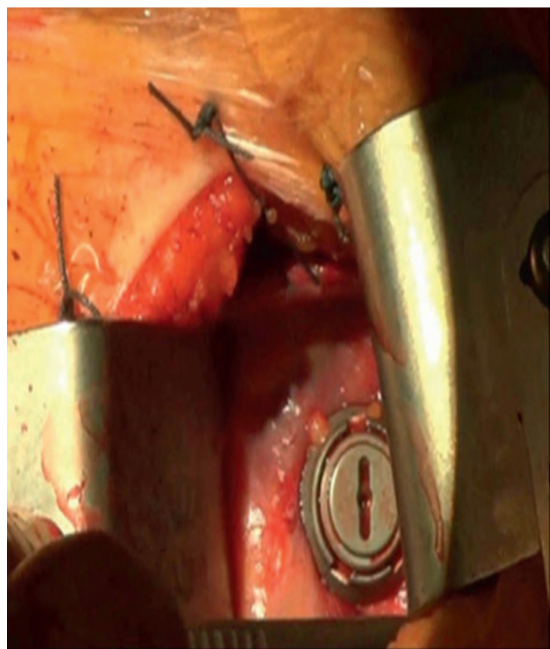


Figure 1: Anterior thoracotomy with apex stabilizer.

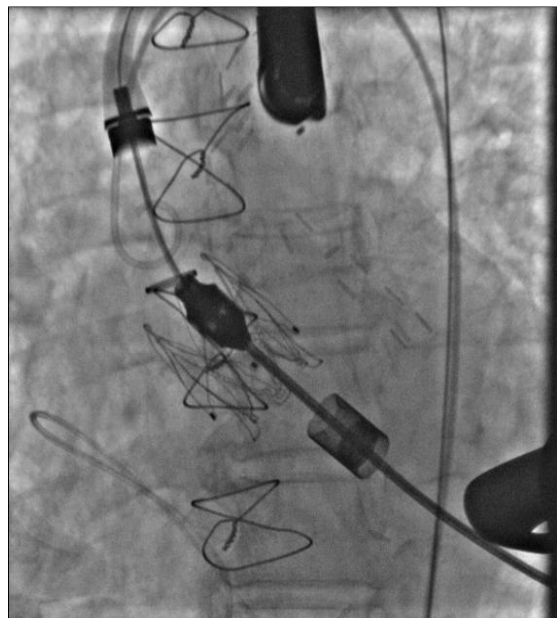


Figure 2: Aortic valve implantation with using the valve delivery system.

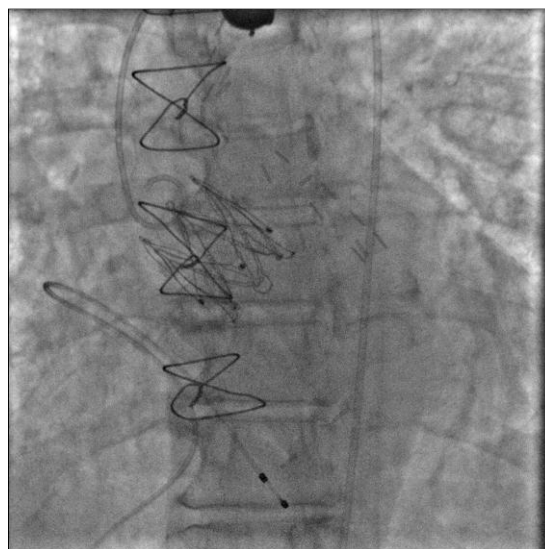


Figure 3: The implantation of the valve at the end of the procedure.

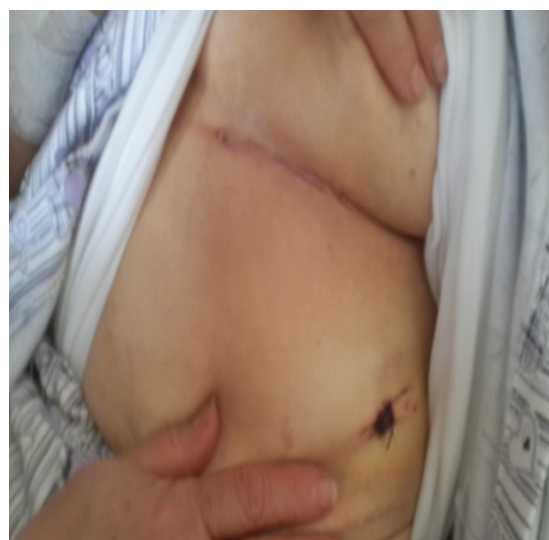

Figure 4: Postoperative scar of left anterior thoracotomy incision.

DISCUSSION

AS is a form of left ventricular outflow tract obstruction (LVOTO) and may lead to left ventricle hypertrophy (LVH), heart failure, syncope and angina pectoris. The most common cause of AS is age-related calcific degeneration with a prevalence of 2% in patients older than 65, and 4% in patients older than 85 years [8]. Despite successful results after surgical treatment in patients older than 80 years, factors such as an aging population and increasing comorbidity rates increase the risk for AVR re-intervention. Eventually, patients are considered inoperable (9).

After Cribier et al. who were the first to successfully perform TAVI in humans, this became the treatment of choice in elderly patients with calcific AS that carries a high risk for surgical treatment (10). TAVI carries less mortality and morbidity rates when calculated with euroSCORE and STS. After TAVI, valve surface area increases and significant improvement in the functional class of the patients are observed (11). TAVI can be performed via transfemoral or transapical approach. The transapical route is preferred when there is a lack of quality and sufficient peripheral artery diameter.

The selection criteria of TAVI patients include: (i) presence of severe AS, (ii) AS related critical symptoms, (iii) functional aortic valve surface area $<0.8 \text{ cm}^2$, (iv) a mean aortic valve gradient $>35 \text{ mmHg}$, (v) low functional capacity.

CONCLUSION

In patients with high-risk AS, transapical TAVI via left anterior thoracotomy is a highly preferable surgical method.

Conflict of interest

No conflict of interest was declared by the authors

REFERENCES

1. Freeman RV, Otto CM. Spectrum of Calcific aortic valve disease: Pathogenesis, disease progression and treatment strategies. *Circulation* 2005;111:3316-26.
2. Otto CM, Lind BK, Kitzman DW, Gersh BJ, Siscovick DS. Association of aortic-valve sclerosis with cardiovascular mortality and morbidity in the elderly. *N Engl J med* 1999;341:142-7.
3. Bonow RO, Canabello BA, Chatterjee K, de Leon AC Jr, Faxon DP, Freed MD, et al. ACC/AHA 2006 guidelines for the management of patients with valvular heart disease a report of the American College of Cardiology/American Heart Association Task Force on Practice Guidelines (Writing Committee to Revise the 1998 guidelines for the management of patients with valvular heart disease) developed in collaboration with the society of Cardiovascular Anesthesiologists endorsed by the society of Cardiovascular Angiography and Interventions and the Society of Thoracic Surgeons. *J Am Coll Cardiol* 2006;48:e1-48.
4. Stewart BF, Siscovick D, Lind BK, et al. Clinical factors associated with calcific aortic valve disease: Cardiovascular Health Study. *J Am Coll Cardiol*. 1997;29:630-4.
5. Billings FT, Kodali SK, Shanewise JS. Transcatheter Aortic Valve Implantation: Anesthetic Considerations. *Anesthesia- Analgesia* 2009; 108:1453-62.
6. Andersen HR, Knudsen LL, Hasenkamp JM. Transluminal implantation of artificial heart valves: Description of a new expandable aortic valve and initial results with implantation by catheter technique in closed chest pigs. *Eur Heart J* 1992;13:704-8.
7. Cribier A, Eltchaninoff H, Bash A, et al. Percutaneous transcatheter implantation of an aortic valve prosthesis for calcific aortic stenosis: First human case description. *Circulation* 2002;106:3006-8.
8. Stewart F, Siscovick D, Lind BK, et al. Clinical factors associated with calcific aortic valve disease: Cardiovascular Health Study. *J Am Coll Cardiol*. 1997;29:630-4.
9. Bloomstein LZ, Gielchinsky L, Bernstein AD, Parsonnet V, Saunders C, Karanam R, et al. Aortic valve replacement in geriatric patients: determinants of in-hospital mortality. *Ann Thorac Surg* 2001;71:597-600.
10. Cribier A, Eltchaninoff H, Bash A, Borenstein N, Tron C, Bauer F, et al. Percutaneous transcatheter implantation of an aortic valve prosthesis for calcific aortic stenosis: first human case description. *Circulation* 2002;106:3006-8.
11. Zajarias A, Cribier AG. Outcomes and safety of percutaneous aortic valve replacement. *J Am Coll Cardiol* 2009;53:1829-36.